THE FOETAL MEMBRANES AND PLACENTA OF THE AFRICAN ELEPHANT (*LOXODONTA AFRICANA*)

By E. C. AMOROSO, F.R.S.* and J. S. PERRY†
* *Royal Veterinary College, London*
† *Institute of Animal Physiology, Babraham, Cambridge*

(*Received* 2 *August* 1963)

[Plates 1 to 14]

CONTENTS

The placenta of the African elephant sometimes extends completely around the equatorial zone of the chorionic sac, but it is more usually interrupted at one or more points on the circumference, in which case the villous areas are restricted to more or less elongated patches distributed meridionally. No chorionic villi were found over the polar areas of the sac.

The chorion is distended, and completely separated from the amnion, by a voluminous quadrilocular allantois, the four sacs of which arise from a common antrum immediately below the point where the umbilical cord emerges from the amnion. These extend around the amnion, and fuse with it, until they meet over the back of the foetus. A yolk-sac was present in the youngest specimen examined (estimated gestation age 1 to 2 months, weight of foetus 2 g), but no trace of this structure could be found in another specimen in which the conceptus was still spherical (estimated gestation age 3 months, weight of foetus 10 g).

The internal endodermal surface of the allantois bears a large number of protuberances, referred to as 'allantoic pustules'. They are mainly concentrated in the vicinity of large allantoic vessels, but their function is obscure.

The placental band comprises a central attachment area bordered by a distinct margin which contains extravasated blood and superficially resembles the marginal haematomata of the placenta of the dog. The extravasated blood, however, is not derived from vessels in the uterine wall, but from capillaries within the placental labyrinth.

As seen with the light microscope, the placenta of the elephant is an endothelio-chorial or a vaso-chorial one, according to the respective classifications of Grosser and of Amoroso and Wislocki (see Amoroso 1955*a*, *b*). The trophoblast is almost entirely single-layered; it is cellular in the basal zones of the placenta but appears syncytial in the bulky distal part which constitutes the placental labyrinth. In the marginal regions of the band extravasation of maternal blood cells occurs, and the cytotrophoblast in this component of the placenta actively ingests some of these corpuscles. In the central portion of the placental band the major maternal vessels are invested by modified trophoblast which retains its cellular character. Beneath the labyrinth, in the central region of the placental band, an invasive zone of lobate villi progressively gives place to a zone where there is very active phagocytosis of the disorganized maternal decidua by the trophoblast. The latter is brought into close relation with the numerous foetal capillaries by the extreme attenuation of the foetal connective tissue. This zone is sharply demarcated from the overlying syncitiotrophoblastic labyrinth.

Maternal blood enters and leaves the placenta by large vessels. The principal afferent vessels feed the labyrinth by arterial branches which pass more or less obliquely towards the foetal surface of the placenta. Small branches leave them at frequent intervals within the labyrinth, and enter the tortuous syncytial lamellae. At many points at the base of the placenta the efferent vessels become confluent with larger venous channels which return the blood to the uterine veins. In the marginal zone, even at our earliest stage, some blood escapes into small trophoblastic lacunae, where it becomes stagnant and undergoes phagocytosis (see above). By mid-pregnancy the marginal zones are clearly defined, and extravasation of blood also occurs within the junctional zone beneath the labyrinth.

The essential features of the placenta and foetal membranes are already established in the earliest stages examined, and they undergo modifications of a relatively slight and secondary nature during the further course of gestation.

The elephant, hyrax and manatee share a number of features in the arrangement of the foetal membranes and in the detailed structure of the placenta. These similarities, and accompanying differences, are briefly discussed.

Introduction

The literature contains no adequate description, even for a single stage of development, of either the foetal membranes or the placenta of the elephant, the few available accounts being fragmentary and leaving many questions in doubt as to the exact nature of the topography of the membranes and the histological relations of the endometrium and chorion. This lack of detailed and exact information regarding placentation in elephants is due in the main to the difficulty of obtaining well-fixed material. Moreover, the time elapsing between the moment when the animal is killed and when the uterus is removed at autopsy is usually a matter of many hours, so that postmortem changes are often extensive. The large size of the pregnant reproductive tract of the elephant also usually precludes favourable preservation.

The most detailed accounts of the gross and microscopic structure of the elephant's placenta are those of Assheton & Stevens (1905) and Boecker (1907). Previously, Owen (1857, 1868) had described the morphological features of a specimen at about mid-pregnancy and Chapman (1880) had examined one at full term. Chapman's account was supplemented in a further paper in 1899, and Assheton (1906) reviewed what was then known of the placenta of the elephant and of the hyrax in comparing them with that of the sheep. The specimen described by Assheton & Stevens (1905) was an afterbirth obtained when an elephant calf was born, probably stillborn, in the London Zoo (Beddard 1902), and they also examined Owen's specimen, which had been preserved in the Museum of the Royal College of Surgeons. We have located only one account of elephant placentation written after 1907, that by Sangvichien (1951) based on membranes recovered when an 80 lb. foetus was aborted.

The five specimens upon which the foregoing descriptions are based are all of Indian elephants, but none of these previous accounts is accompanied by as detailed or adequate illustrations as the present material affords. Moreover, it is evident from the earlier descriptions and the discrepancies between them that the authors were greatly hampered in their investigations owing to the poorly preserved condition of their material. In most cases, the quality of the fixation must have been such that the material would have been rejected had not its rarity encouraged the investigators to attempt the utmost use of what was available. The extent of the confusion thus engendered may be judged from the fact that the accounts of two such competent investigators as Owen and Assheton differed over the presence or absence of an allantoic cavity.

While minor differences between the placentation of the Indian and African elephant do exist, they are, nevertheless, very similar in many respects. Our material of *Loxodonta*, which is more extensive and better preserved than any proboscidean material hitherto obtained, thus affords an opportunity of re-investigating the topography and histological structure of the placenta and foetal membranes, and has enabled us to reconcile many of the apparent inconsistencies in the literature.

In a previous paper (Perry 1953) it was stated that the histology of the placenta appeared from preliminary study with the light microscope to be rather similar in *Loxodonta* and *Procavia*. Further investigation has not substantiated this impression, and it may be said that the placentae of these two species exhibit some striking but mainly superficial similarities, together with differences in detailed structure and development. The placental affinities of the two groups, and of others which share certain characteristics with them, have been discussed by various authors and will be reviewed in a later section of this paper, when the present material has been described.

Material and methods

The present account is based upon material from pregnant uteri of *Loxodonta africana* collected in Uganda in the course of an investigation carried out by one of us in circumstances described in a previous paper (Perry 1953), together with one specimen (E 1, table 1) of an earlier stage of pregnancy, collected in Kenya in June 1962 by Dr R. V. Short, who very kindly put it at our disposal. This specimen, which was fixed in formalin within an hour of death, comprises the whole of the conceptus with its contained foetus, estimated to be 1 to 2 months old (figures 2 to 5, plate 1). The slightly older specimen, E 36, includes only the foetal components of the placenta, the allanto-chorionic sac having been removed in its entirety from the uterus, and preserved intact in alcohol (figures 6 and 7, plate 2).

Eight pregnant uteri and their contained allanto-chorionic sacs have been selected for detailed study, six of them collected in the period January to March 1950. During this period a number of specimens were obtained relatively soon after death and in some cases it was possible to retain the apposition of foetal and maternal elements during fixation.

The topography of the foetal membranes was explored in the fresh condition, but even then it proved impossible to separate chorionic from allantoic tissue over much of the allanto-chorion, so that the arrangement of the foetal membranes has been described from dissections of fixed material.

The collection includes a number of specimens which appear to be near the middle of pregnancy, and some later stages, including one (E148, table 1) which must have been very near term. We have no specimens of the very earliest stages in development; in our youngest (E1) the chorio-allantoic placenta is already well established and has, indeed, acquired its definitive form in some respects.

Procedure in the field varied according to circumstances, but after a few specimens had been examined in the fresh condition attention was mainly devoted to adequate preservation of material for transport to England. In the larger specimens it was extremely difficult to retain the apposition of the foetal and maternal parts of the placenta after fixation. This was especially true of small pieces of the placenta, even when the outer layers of muscle were removed from the uterus. Since it was desired to retain the foetal-maternal connexions intact, and yet to secure adequate fixation, a thick slice of the uterus was removed with the whole width of the placental band attached; the apposition of foetal and maternal tissues was aided to some extent by sewing together the margins of the 'slice' with stitches passing through its entire thickness. The specimen was then immersed in a strong solution of formol-alcohol for about 12 h, after which it was transferred to a 5% formalin solution for storage. Smaller pieces were preserved in various other fixatives for special purposes.

Portions up to a size which comprised about half the width of the placental band were imbedded in celloidin, and thick sections (20 μm) were prepared; thinner sections were obtained from smaller blocks, the thickness of the 'slice' being divided into a number of smaller pieces which were double-imbedded in celloidin and paraffin wax. The majority of the sections were stained with haematoxylin and eosin and with several modifications of Mallory's connective tissue stain. In addition, a variety of cytochemical reagents were used for the display of fat and glycogen.

Although the foetal-maternal connexions in the smaller pieces were subject to greater distortion during fixation, the blocks of tissue subsequently removed for the preparation of histological sections proved to be well preserved and the relations of the endometrium and chorion could be elucidated with the help of the bulk specimens available for comparison. Such pieces of the placenta were collected when it was possible to dissect the uterus soon after the death of the animal. In other cases, when the post-mortem interval was longer, the chorionic sac was preserved intact and the account of the topography of the foetal membranes, given below, is based upon the dissections of two such specimens after transport to England, where each stage in the procedure could be photographed.

Investigation of the preserved material has proceeded from the gross to the microscopic structure, and the same plan has been followed in the description. The eight specimens which have been examined in detail are listed in table 1, in order of their estimated gestation age.

TABLE 1. SPECIMENS ARRANGED IN ORDER OF GESTATION AGE

specimen and date killed	interval after death, until dissection (h)	mammary glands	foetus		ovaries	conceptus	allanto-chorionic sac	placental band	notes
			sex	wt.					
E1, 25. vi. 62	1	milk	—	2 g	3 large recent corpora lutea	10 cm (fresh)	spherical	incomplete	C–R length of foetus approx. 4 cm (preserved)
E36, 9. ix. 47	20	milk	—	10 g	one large recent corpus luteum in each	20 cm (fresh)	spherical, diameter 9 cm (preserved)	incomplete	C–R length of foetus approx. 10 cm (preserved)
E115, 18. i. 50	24	not lactating?	♀	3 kg	corpora lutea of conception only	see figure 12, plate 3	length 79 cm, girth 102 cm (fresh)	incomplete 2 ‘cotyledons’	possibly a first pregnancy
E147, 8. iii. 50	5	no milk	♀	3 kg	corpora lutea of mid-term ovulation	girth 109 cm (fresh)	see figure 18, plate 4	incomplete 3 ‘cotyledons’	—
E122, 6. ii. 50	24	—	♀	3 kg	5 large recent corpora lutea	length 108 cm, girth 135 cm (fresh)	see figures 19 to 21, plate 4	incomplete 3 ‘cotyledons’	placental band extended over less than half circumference
E138, 24. ii. 50	½	milk	♀	6 kg	many large recent corpora lutea	—	length 76 cm, girth 132 cm (fresh)	incomplete	conceptus small for size of foetus
E117, 25. i. 50	16	milk	♂	4·5 kg	large recent corpora lutea in right ovary only	length 124 cm, girth 172 cm (fresh)	see figure 13, plate 3	complete	placental band 20·5 cm wide, attachment zone 11·5 cm wide (fresh)
E148, 8. iii. 50	7	milk	♂	120 kg (estimated)	corpora lutea apparently regressing	—	—	incomplete	very near term: av. width of placental band 21 cm (preserved)

THE GRAVID REPRODUCTIVE TRACT

The general arrangement of the female reproductive tract has been described in a previous paper (Perry 1953) and a separate account of its development and musculature appears in the paper that follows the present one (Perry 1964). The lumina of the right and left uterine horns continue for some distance below the junction of the surrounding musculature before opening separately into a common lumen which occupies approximately the posterior half of the body of the uterus.

Implantation is of the central type (Mossman 1937) and was believed to occur in the distal part of the uterus where the horns are fused but the lumina are distinct (Perry 1953, figure 4). The conceptus of E1, however, was in the right uterine horn, nearer to its ovarian end (figure 2, plate 1) as was a specimen of similar age subsequently obtained by one of us (E.C.A.) in May 1964. As a result of the growth of the blastocyst, it eventually occupies and distends the whole of one uterine horn. The adjacent portion of the contralateral horn is compressed, and the allanto-chorionic sac is thus excluded from it, even after extending into and filling the common lumen of the lower part of the uterine body.

Twinning has not been recorded in the African elephant, but is known to occur in the Indian elephant (Blanford 1888–91; Ferrier 1948). At birth, the calf of *Loxodonta* weighs about 120 kg and measures about 120 cm from the occiput to the base of the tail. It was not possible to measure the conceptus of the full-term specimen (E148, table 1), but the zonary placental band extended around a girth of at least 150 cm, its average width being approximately 30 cm, in the fresh condition.

A conspicuous feature of the reproductive tract is the unusually long vestibule or urogenital canal, which extends from the opening of the vagina at about the level of the pubic symphysis, to an opening on the abdominal wall a little anterior to the hind legs.

THE TOPOGRAPHY OF THE PLACENTAL MEMBRANES

(1) *The chorionic membrane*

The youngest developmental stage at our disposal (E1, table 1, figures 2 to 5, plate 1) comprises the entire conceptus at an estimated gestation age of 1 to 2 months. In this specimen the chorio-allantoic placenta is already well established. Here, the areas of trophoblastic proliferation are arranged in three discrete patches confined to the equatorial region of the blastocyst and connected by membranous chorion. Figure 4 is a transect of the conceptus through the areas of attachment after the removal of the foetus. It shows the relative development of the mucosa and muscularis. The mucosa, which was strikingly gelatinous in the fresh condition, forms a thick annular cushion in which radially disposed blood vessels can be seen.

The next developmental stage (E36, table 1, figures 6 to 11, plate 2) is a spherical allanto-chorionic sac of about 3 months of age with its contained foetus. The remainder of the blastocyst is taken up by a voluminous allantois, the extra-embryonic coelom having already been obliterated by the enlargement of the allantoic sac (see p. 7). In this specimen, the trophoblastic proliferations that engage the endometrium are sharply confined to the equatorial region of the blastocyst. They comprise two segments of unequal size bearing the allanto-chorionic villi. These segments are separated from each other by intervening membranous chorion, as shown in figures 6 and 7, plate 2, photographed by reflected and transmitted light, respectively. In the illustrations a tongue-shaped process (*t*) of the larger segment is distinguishable in this region as an accessory placental mass. It extends towards, but does not fuse with the smaller segment, and in it the trophoblastic proliferation is less intense than elsewhere. At this stage the placental band is approximately 40 mm in breadth. By mid-term, however, when the zonary arrangement of the placenta is clearly defined, it has attained a width of about 20 cm and the chorionic sac, which was at first spherical, has become distinctly ovoid, elongation taking place in the direction of the uterine axis, as shown in figure 12, plate 3. It is noteworthy also that the zonary band is not invariably divided into segments; it was complete, for instance, in E 117 (table 1 and figure 13, plate 3), but not of equal width at all points around its circumference.

There are no signs of the development of chorionic villi anywhere outside the placental girdle in any of our specimens, the earliest of which certainly represents a much earlier stage in pregnancy than that of the Indian elephant described by Owen (1857), who found subcircular areas of villous proliferations at the poles of the chorionic sac. Chapman (1880) confirmed the presence of such villous patches in a full-term specimen of the same species, and Assheton & Stevens (1905) agreed with Owen that these patches constituted a non-deciduous and diffuse placental area, which it was unusual to find in conjunction with a deciduate zonary placenta.

Our material does not provide an explanation as to why the invasive proliferation of the trophoblast with its axial mesoderm should be restricted to particular areas of the chorionic surface, or why it should vary, within limits, from one specimen to another. Our youngest specimen provides no evidence that the girdle-like arrangement results from the unequal attrition of a formerly diffuse proliferation of the trophoblast over the entire circumference of the blastocyst, the trophoblast at the poles lagging behind the invasion of trophoblast in the central zone (cf. Indian elephant, Owen 1857; Chapman 1880; Assheton & Stevens 1905).

As is evident from the specimens listed in table 1 and those shown in figures 15 to 17, plate 3, the placental band grows progressively in width and in thickness as gestation advances, but towards the end of pregnancy the organic connexion between the endometrium and the chorion is greatly reduced, and consists of little more than the maternal arteries and veins which enter and leave the base of the placenta (figure 14, plate 3).

(2) *The yolk-sac*

In our youngest specimen (E 1) the yolk-sac is already reduced to a shrivelled thin-walled sac lying between adjacent compartments of the allantois (see below) and apparently having no connexion with the chorion (figure 3, plate 1). It is lined by large deeply staining endodermal cells, and covered by vascular mesenchyme. The fact that the endodermal cells are modified over part of the yolk-sac wall, where they are columnar and vacuolated (figure 30, plate 6), suggests that the omphalopleur formerly made contact with the chorion and was fused with it, thus establishing a chorio-vitelline placental relationship. In the 3-month-old blastocyst, on the other hand, the yolk-sac has undergone complete resorption and the extra-embryonic coelom is entirely obliterated by the fusion of the voluminous allantois with the chorion over the whole extent of the latter.

(3) *The allantois*

In our youngest specimens (E1 and E36) the allantois has already attained the striking configuration of the definitive organ, the structural complexities of which are related to the peculiar manner in which the allantoic vessels reach the chorion. The umbilical blood vessels, of which there are two arteries and two veins, divide a short distance from the body of the foetus, giving rise to four diverging sets of paired vessels (figure 11, plate 2). These proceed as diverging pedicles that pass in membranous reduplications of the allantois to the surface of the placenta before undergoing further subdivisions. In these specimens, illustrated in figures 3 and 4, plate 1, and figures 6 and 7, plate 2, the allantoic blood vessels have made their first contact with the chorion.

Upon approaching the face of the placenta the four major pairs of vessels, constituting the umbilical pedicles, give off large diverging branches which pass to the adjacent parts of the placenta and, as shown in figures 8 and 9, plate 2, a profusion of smaller vessels radiates meridionally from them to supply the whole of the membranous allanto-chorion. In figure 8, which shows a portion of the foetal surface of the allanto-chorion, these blood vessels can be seen to rest upon the surface of the membrane and to protrude by their thickness into the allantoic cavity. Here too may be seen, glistening through the translucent allanto-chorionic membrane, a number of circular, opaque bodies representing early stages in the development of allantoic pustules (see pp. 10 and 11).

Unlike the foregoing branches, the main stems of the original vessels proceed directly to the placental face but, like the former, they are raised for the most part from the surface (figure 9). These stem vessels course for long distances, diminishing ultimately in size by giving off numerous subsidiary tributaries to all parts of the placenta. Some of these subsidiary branches, while traversing the placental face, are free to the extent of possessing a slender mesentery for short distances, but they soon become embedded in the allanto-chorionic mesenchyme, which is well developed in this region.

As previously indicated, the allantois of the African elephant is a complex structure and by the second or third month of pregnancy it already constitutes a quadrilocular sac which is anchored to the placenta by the four pairs of diverging vascular pedicles alluded to above (see figure 11, plate 2). These vascular pedicles form the boundaries of a common allantoic antrum (*a*), from which the cavity extends between the leashes of vessels so as to form sacculations or compartments of unequal size, the outer walls of which are fused everywhere with the chorion, forming with it an extensive allanto-chorionic membrane. The two major compartments (2 and 4, figures 20, 21, plate 4), lying side by side, occupy the equator of the chorionic sac and extend over the lateral surfaces of the amnion, the cephalic and caudal ends of which are enclosed by the two lesser sacculations (1 and 3) which extend into the poles of the membranous chorion. Where allantois and amnion are in contact, their mesodermal elements fuse, forming allanto-amnion which is much less vascular than the membranous allanto-chorion.

Stages in the dissection of the uterus and the foetal membranes, which are intended to show these complicated relationships at about the middle of pregnancy, are illustrated in figures 12 and 13, plate 3 and figures 18 to 22, plates 4 and 5.

The first step in the dissection of the chorionic sac, after its removal from the uterus and storage in formalin, was to slit open that portion of the chorion which has fused with the allantois within the confines of the rectangle formed by the attachment of the allantoic vessels, thus exposing the common allantoic antrum (figure 19, plate 4). In this figure, the edges of the slit are retracted so as to display the subjacent vascular pedicles as well as the openings of the four allantoic diverticula or recesses which extend out between the pairs of blood vessels bounding the common allantoic space. For ease of orientation their openings are numbered as '1', '2', '3' and '4'. Also clearly visible, between the paired vessels as they emerge from the umbilical cord, is the opening of the urachus (*ur.*).

At this stage, even more than at the preceding ones, the two lateral diverticula (2 and 4) which are approximately co-extensive with the zonary placenta, have become more voluminous relatively and absolutely than the cephalic and caudal ones (1 and 3), which extend respectively over the head and rump of the foetus (figure 20). Accordingly, any attempt to expose the interior of these lateral compartments must inevitably involve the resection of parts of the placental band.

In figures 20 and 21 the larger sacculations '2' and '4' extend over the lateral surfaces of the amniotic sac and '4', which is the largest, partly covers the dorsal and polar surfaces. The outer (allanto-chorionic) walls (*ac*) of these lateral compartments have been cut away along the line of their junction with the cephalic and caudal compartments (1 and 3), and reflected to expose the inner (allanto-amniotic) wall (*aa*), as well as the cavity of the common antrum. Flexible probes (*pr*) mark the margins of the cephalic and caudal compartments in figure 20.

Finally, an attempt to show the relationship of the four diverging sets of blood vessels to the floor of the common allantoic antrum has been made in figure 22, plate 5. In this view of the interior of the allanto-chorionic sac the mesenteries of reduplicated allantois, which ensheathe the respective leashes of blood vessels as they pass from the umbilical cord to the chorion, have been dissected away, leaving the floor of the antrum intact and displaying very handsomely the vascular pedicles.

It will be recalled that the membranous allanto-chorion of our 3-months-old blastocyst is supplied with a number of blood vessels, arteries and veins, readily visible to the naked eye (figures 7 and 8, plate 2). By mid-term, however, the vascularity of the membranous chorion has increased quite considerably and it now greatly exceeds that of the allanto-amnion or of the membranous reduplications of allantoic membrane which separate the four sacculations of the allantoic cavity. The structural peculiarities here outlined leave one in no doubt that the relationship of amnion and allantois is exceedingly complex and that the latter forms with the chorion a voluminous allanto-chorion which is much more extensive than the amniotic sac which it surrounds.

(4) *The allanto-amnion and the amniotic pustules*

The amnion is a thin semi-transparent membrane which closely invests the foetus in all our specimens. In all except the youngest specimen it is fused back to back with a portion of the allantois, the cavity of which everywhere separates it from the vascular chorion. In the youngest specimen, E1, local thickenings of the allantoic mesoderm extend across to the amniotic mesoderm and fuse with it (figure 29, plate 6). The mesenchyme of these thickenings resembles that of the amniotic and allantoic pustules described below. In later stages, however, the amniotic and allantoic pustules protrude into the cavities of the amnion and allantois respectively—that is, away from the mesodermal surfaces. It is therefore doubtful whether the mesenchymatous outgrowths which join the two membranes in E1 can be regarded as an early stage in the formation of the amniotic and allantoic pustules. They perhaps represent the beginning of the fusion of amniotic and allantoic mesoderm which is complete in the older specimens.

In specimens at mid-term or later, the most characteristic feature of the amnion pertains to the nature of its inner (ectodermal) surface. This is beset with a profusion of minute excrescences or pustules (figures 25 and 26, plate 5). Similar thickenings on the foetal surface of the amnion of several mammalian species have been variously known as *amniotic plates* or *bodies* (Turner 1875), *plaques amniotique* (Bernard 1879, Jenkinson 1906), *amniotic villi* (Wislocki & van der Westhuysen 1940; Wislocki & Enders 1941), *amniotic pustules* (Assheton 1906; Hammond 1927; Amoroso 1952), *amniotic caruncles* or *carunculae* (Wislocki 1935; Heuser & Wislocki 1935; Wislocki & van der Westhuysen 1940; Wislocki & Enders 1941). We prefer the term *amniotic pustules* for the similar structures in the elephant.

As seen in figure 25, these pustules appear as spherical, pearly-white elevations that are not especially related to blood vessels, but are irregularly distributed over the entire surface of the amnion, although they are much more abundant in the neighbourhood of the distal end of the umbilical cord. They vary considerably in size, the largest attaining a diameter of 0·5 mm, the smallest being just visible to the naked eye. In sections (figure 26) the pustules prove to be somewhat pedunculate and to be composed of a delicate core of mesenchyme clothed by a proliferated layer of enlarged epithelial cells that differ perceptibly from the ordinary amniotic epithelium. Some of the covering cells are vacuolated.

(5) *Allantoic differentiations*

In addition to the amniotic pustules there are similar, but very much larger, excrescences on the inner (endodermal) surface of the allanto-chorion that project freely into the allantoic cavity. Very much more irregular than the minute amniotic pustules, they were described by Owen (1857) in the Indian elephant, as *subcircular bodies*, by Assheton & Stevens (1905) as *disk-like bodies* and by Chapman (1880) as *cotyledons*. The term *cotyledon* was used by Assheton & Stevens, and by Beddard (1902), to describe the segments of the placental band.

In the African elephant, these wax-like excrescences are usually subspherical in shape (figure 23, plate 5), but occasionally more bizarre forms are encountered such as those portrayed in figure 24, where some are club-shaped and others are mushroom-like, sometimes with an annular thickening on the stalk. The specimens illustrated in figures 20 and 21, plate 4, are from allanto-chorions near the middle of pregnancy, and the average diameter of the allantoic bodies is 5 to 6 mm at this stage. They increase in size until they are commonly about 1 cm in diameter at full term.

Regarding their distribution, Assheton & Stevens (1905) observed that they did not occur over the zonary placental band in their specimen, but did so in Owen's specimen. In our African material they are uneven in number and distribution in different parts of the allanto-chorion, but are more numerous where they overlie the placenta than elsewhere. As can be seen in figure 23 they are generally distributed along the course of the blood vessels, although a small percentage of them are without any distinct relationship to recognizable placental vessels. On the other hand, it should be recalled that in E36, estimated to be about 3 months old, although the vascularization of the membranous chorion is not especially abundant (see figures 7 and 8, plate 2), a fair number of the allantoic bodies are already present, most of them at a very early stage of differentiation. Yet, even the smallest visible ones accompany the vessels that leave the placental border to supply the allanto-chorionic membrane.

These observations suggest that these various bodies, so numerous along the walls of the allantoic vessels supplying the placenta, are specializations of the adventitial vascular sheath, some of which are destined at later stages to lose their connexion with the parent vessel. Microscopic examination (figure 27, plate 5) reveals, however, that they are due merely to the proliferative growth of the mesodermal stroma of the allantois. As is evident from the figure, the fibrillar cells which comprise the core of the allantoic bodies are similar to those of the underlying mesoderm, but are fewer, more irregular and less compactly arranged than elsewhere in the foetal mesenchyme, being held together in a substance similar in appearance to Wharton's jelly. Immediately beneath the covering epithelium, the cells of which retain their cuboidal form, the mesenchymal elements are more compactly arranged and somewhat more plentiful. Moreover, blood vessels occur only at the base of the allantoic bodies and do not appear to enter their cores. Similar bodies have been described in the manatee (Wislocki 1935), but their function remains unknown.

THE TOPOGRAPHY OF THE ZONARY PLACENTA

In the account which follows, the topography of the placenta is described in terms of 'regions' with respect to the surface of the placental band and in terms of 'zones' with respect to depth within a transect of the band, i.e. from the face of the placenta to its base. A transect of the placenta at mid-pregnancy is illustrated diagrammatically in figure 1; the respective width of the central and marginal regions in the fresh condition can be distinguished in figure 13, plate 3, and compared with the condition after fixation in figures 15 and 16. It is evident that fixation causes greater shrinkage in the central than in the marginal region, so that the actual area of attachment appears relatively less extensive in the fixed preparation. Notwithstanding this fact, it is clear that the surface area of the central region far exceeds that of the combined marginal regions by the middle of gestation. There is considerable individual variation in the surface area of the placenta

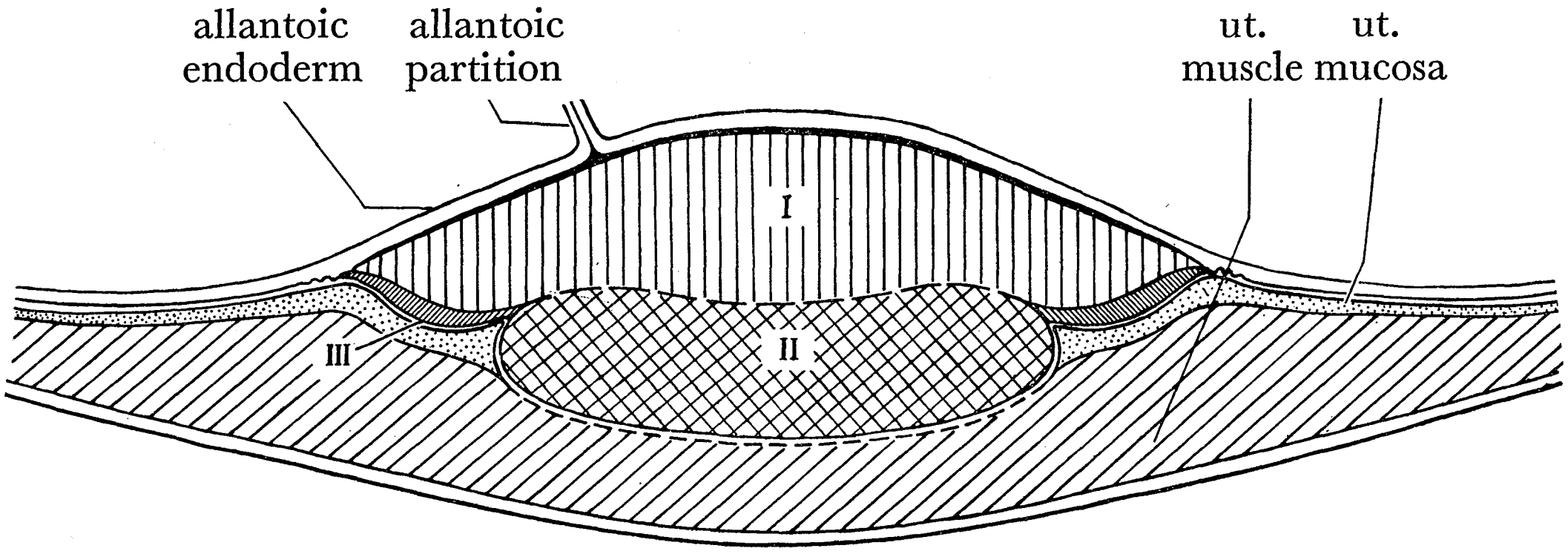

FIGURE 1. Diagrammatic transect of placental band.

at any particular stage of pregnancy, but it is estimated that the area of attachment of chorion to endometrium is between 1000 and 1500 cm^2 at about mid-term, increasing about threefold during the second half of gestation.

The character and mode of growth of the trophoblast is perhaps the most striking feature which differentiates the placenta of *Loxodonta* from that of any other form of zonary placenta so far described. By reference to figure 1, the placental trophoblast at mid-term may be divided into three distinct zones:

Zone I, the *syncytiotrophoblastic zone*, which comprises the bulk of the placental labyrinth, extends across the whole width of the allantoic face of the zonary band and is continuous with the cellular parenchyma of both Zones II and III in the central and marginal regions, respectively. It consists of lamellar sheets of syncytial trophoblast enclosing tortuous maternal capillaries.

Zone II, the *basal cytotrophoblast*, located in the central region immediately beneath Zone I, is a zone of actively phagocytic cellular trophoblast. It consists, primarily, of the proliferating tips of the syncytial lamellae, and comprises the sole invasive tissue of the placenta. In the deeper part of this invasive zone, the foetal tissues form blunt 'lobate villi' (see p. 19), each with a relatively massive core of richly vascularized mesenchyme. Here, the cytotrophoblast cells appear to be taller and more strikingly altered than elsewhere. Because of the intermingling of the cytotrophoblastic elements with the necrotic products of the endometrium, the subdivision of this zone is subject to marked variation in sharpness of definition. We shall adopt the term 'junctional' or 'necrotic' zone for this basal cytotrophoblast, for it is clear that in this layer the trophoblast, the cells of which have a variable morphology, meets and intermingles with the elements of the endometrium which it destroys. To disengage its various elements in the ripe placenta, and to label them, is well nigh impossible.

Zone III, the *border cytotrophoblast*, is located in the marginal region and extends inwards towards the central region for variable distances beneath Zone I. Like Zone II, it consists of a broad band of labyrinthine cytotrophoblast which is continuous on the foetal side with the laminae of syncytial trophoblast, but it terminates freely on the maternal side, enclosing recesses or lacunae into which maternal blood has escaped. This formation is the equivalent of the 'marginal haematoma' of carnivores and, as we shall see, is a device which provides for the histiotrophic nourishment of the foetus by the destruction and assimilation of extravasated maternal blood.

From the foregoing it is quite clear, therefore, that the abrupt transition between syncytial and cellular trophoblast constitutes a horizontal partition between corresponding zones in both the marginal and central regions, and that there is little, if any, syncytium which actually penetrates to the inner face of the placenta.

THE HISTOLOGICAL DIFFERENTIATION OF THE PLACENTA

(*a*) *The early placenta* (*E1 and E36*)

(i) *General*

As has been pointed out in the previous sections, the allanto-chorionic sacs associated with our earliest specimens already exhibit some of the placental characteristics seen at mid-term, and the syncytiotrophoblastic zone already constitutes the bulk of the placental labyrinth. Zone III, however, is not yet sharply demarcated; in E1 it is only represented by simple recesses or lacunae, lined by cytotrophoblast, into which maternal blood has already escaped (figure 31, plate 6) and in E36 it is still far from forming a continuous boundary to the placental margin. Zone II is represented in E1 only by the cellular trophoblast of the tips of the invading trophoblastic villi, and it has not been preserved in E36. In this specimen the blastocyst was very easily removed from the conceptus at the time of dissection, but the histological preparations show that the tips of the foetal villi, which were presumably covered by cytotrophoblast like those of both earlier and later specimens, must have remained attached to the uterine wall.

The arrangement of the areas of attachment in both these early specimens, to form an incomplete girdle of trophoblastic proliferation over the equator of the trophoblast, clearly foreshadows the zonary form of the later placenta. In the older specimen, E36, the girdle is interrupted in the vicinity of the insertion of the umbilical cord, and the smaller and less dense area of proliferation already referred to (p. 7) covers part of this gap. As seen with the light microscope, this accessory placental mass proves to be, as its gross appearance suggests, an additional area of chorionic attachment. However, since the uterine tissues have not been preserved in this specimen, little can be said of the exact manner of attachment of blastocyst to endometrium in it. Nevertheless, the impression was gained that the attachment of the chorionic sac to the wall of the uterus was in all essentials similar to that of the younger specimen, E1.

(ii) *The syncytiotrophoblastic zone* (*Zone I*)

The structure of the placenta of our two youngest specimens, as seen with the light microscope, is illustrated in figure 28 and figures 31 to 36, plates 6 and 7. As these figures show, Zone I consists of an irregular network of dark-staining lamellae of apparently syncytial trophoblast (*syn*, figure 35 and see Discussion, p. 29) which are separated by broad bands of pale-staining connective tissue, through which course the slender foetal capillaries (*f.c.*). In these capillaries, nucleated erythrocytes predominate in E1, whereas in E36 they already constitute only a minute proportion of the circulating red cells. In figures 32 and 35 the foetal stroma has shrunk away from the trophoblastic epithelium during fixation, whereas in figure 36 it has not been preserved in the sections. Figures 32 and 35 illustrate the histology of the lamellar trophoblast early in pregnancy. Here, in haematoxylin and eosin preparations, the nuclei are, in general, deeply staining, small, and irregular, while the cytoplasm is darker than that of the cytotrophoblast at the tips of the lamellae (figure 34). As yet, no intra-epithelial capillaries are discernible. Within the lamellae, surrounded by trophoblast and a variable amount of a fibrous matrix with occasional cells, best detected after staining with the P.A.S. reagent, run minute, tortuous, thin-walled maternal capillaries (*m.c.*). Thus a lamina of trophoblast separates the maternal blood vessels, which are lined by endothelial cells, from the foetal stroma with its capillaries, creating an endotheliochorial or a vasochorial membrane according to the respective classifications of Grosser and of Amoroso and Wislocki (see Amoroso 1955*b*). It will be shown that this relationship between the chorionic ectoderm and the maternal blood vessels persists over most of the placenta throughout the remainder of gestation and must be regarded as the definitive condition of the barrier. In this respect the placenta of the African elephant resembles the typical carnivore placenta such as that of the dog and cat (Duval 1895; Amoroso 1955 *b*) and is strikingly different from the haemochorial type of placenta encountered in the hyrax (Thursby-Pelham 1925; Wislocki & van der Westhuysen 1940) and in the manatee (Wislocki 1935). It is clear, moreover, that in the hyrax, at least, maternal blood is released into the trophoblastic sinuses at an earlier developmental stage than that of our youngest specimen, and that the trophoblast comprising the lacunae in the basal half of the placenta is completely devoid of mesoderm and consequently of a foetal circulation. Hence in the hyrax the respiratory exchange is restricted to the foetal surface of the placenta occupied by the dilated lacunae, whereas in our earliest placental stage of *Loxodonta* it takes place over the deeper portion of the labyrinth as well.

(iii) *The junctional zone* (*Zone II*)

The microscopic structure of the zone of attachment in E1 (C.R. length, 33 mm) is illustrated in figures 28 and 34, plates 6 and 7. The chorionic outgrowths have a stout core of richly vascularized mesenchyme and their epithelium consists of a single layer of trophoblast which is clearly cellular at the advancing tip of each outgrowth. In these respects the folds resemble the lobate villi at the base of the mid-term placenta (see pp. 12 and 19) but the trophoblast cells are not, at this early stage, as cylindrical in form, nor is the transition to an apparently syncytial condition as abrupt as it is destined to become in the ripe placenta. These growing tips penetrate the mucosa for variable distances. In their advance they do not regularly fit against the openings of the uterine glands in the way which is characteristic of the placenta of the dog and cat (cf. Assheton 1906). In *Loxodonta*, however, the uterine glands are nowhere abundant, and they are no more so in the area of attachment than elsewhere.

The maternal tissues, whether epithelial or stromal, appear to undergo cytolysis in the immediate vicinity of the encroaching cytotrophoblast although in places, at this early stage, remnants of the disintegrating decidua in the shape of decidual cells and glandular debris are included in the trophoblastic lamellae, together with maternal capillaries. Outside the area of attachment, the chorionic sac is completely membranous, and is apposed to but not fused with the uterine epithelium.

The foetal blood supply to the placenta is through grossly visible arteries which course on the foetal surface of the placenta and give off a variable number of small vessels that dip into the chorionic septa separating the lamellae. During the early stages in development the growing trophoblastic lamellae are widely separated by abundant foetal stroma, and the foetal blood vessels appear relatively sparse. During later stages, however, as the placenta matures, the chorionic mesenchyme becomes greatly compressed between the branching lamellae and the vascularisation is correspondingly increased.

(iv) *The placental border* (*Zone III*)

As previously indicated, this zone is only represented in our youngest specimen, E1, by simple recesses lined by cytotrophoblast. In the older specimen, E36, the basal surface of the placental band (uppermost in the illustrations, figures 6 and 7, plate 2), which constitutes the zone of attachment to the endometrium, appears in the gross to be uniformly studded with villous projections or papillae, and its margins are not especially differentiated to the naked eye. In sections, however, the histological structure is far from uniform in the central and marginal regions, respectively. The main difference between them pertains to the more intense proliferation and the invasiveness of the trophoblastic villi in the central region, in contrast to the marginal region where little or no invasion of the endometrium occurs. Even in E 1 there is some extravasation of maternal blood into lacunae lined with cytotrophoblast which is not in contact with the endometrium, and in E 36 there are places where the resultant haematomata are already fairly advanced, as shown in figure 36, plate 7. The trophoblast here is differentiated into characteristic columnar cells with basally situated nuclei and a large amount of distally placed, vacuolated cytoplasm. The condition, where cytotrophoblast is in direct contact with stagnant maternal blood, is more clearly defined in older placentae and its detailed description will be deferred until later.

Adjacent to the border of the placenta in E 1, the membranous chorion (figure 33, plate 7) consists of relatively thick folds of mesoderm covered by a simple layer of columnar cells continuous and almost identical with the cytotrophoblast of the marginal lacunae. These folds are destined at later stages to become elaborated into the complex structure of the placental margin.

The endometrium immediately outside the placental areas is of interest. Here, the surface epithelium is preserved and the mucosa is variously folded so that bluntly branched proliferations of the uterine wall project freely into the uterine lumen, as shown in figure 31, plate 6. At this stage (E 1) the endometrial glands, though relatively sparse, are actively secreting and discharge their contents into the uterine cavity. The mucosa is markedly oedematous, the stroma in places directly beneath the surface epithelium and between the outlets of the glands being swollen, quite acellular, and filled with a faintly pink-staining colloid.

(v) *The extra-placental region*

In contrast to the paraplacental endometrium, the mucosa of the uterine wall in the cleft between trophoblastic proliferations in E 1 (figure 4, plate 1) is not produced into folds and is relatively shallower than elsewhere. The glands of this part of the uterus, though greatly reduced in number, are simple, slightly dilated structures, identical in character with the fundic glandular segments found elsewhere in the endometrium.

(*b*) *The placenta at mid-term*

(i) *General*

Apart from a great increase in width, in thickness, and in circumferential extent, the most noticeable change in the gross topography of the placental band between the stages reached by our youngest specimens and that which is reached by the middle of pregnancy (e.g. E 117, figure 13, plate 3) consists in the further differentiation of central and marginal regions. These features are illustrated in the photographs of the transected band in mid- and late pregnancy (figures 15 to 17) and in the photomicrographs (figures 41 and 54, plates 9 and 12) which are described in greater detail below. Especially noticeable in figure 17 and in the photograph of the fresh specimen taken in the field (figure 14), is the dark colour of the placental band, which contrasts with the pallor of the uterine wall to which it is attached.

Microscopically the architecture of the placental labyrinth has changed markedly from the previous stage, and illustrates the growth to maturity of the placenta foetalis. The latter consists of a thick lobulated structure (figure 37, plate 8) varying from 4 to 5 cm in thickness and composed of trophoblast and stroma in which the three distinctive zones are now recognizable (figure 1).

(ii) *The syncytiotrophoblastic zone* (*Zone I*)

Details of this zone at mid-gestation are illustrated in figures 38 and 39, plate 8. As can be seen from the photomicrographs, it now consists of a somewhat twisting system of fine-meshed syncytial lamellae and foetal mesenchyme in which the maternal and foetal circulations become intimately apposed. The lamellae which enclose the maternal capillaries are oriented for the most part in parallel rows running obliquely from the surface towards the base of the placenta, but there are numerous anastamoses between them, and they branch and rejoin so frequently that, as Assheton & Stevens (1905) remarked, 'sections through this zone at mid-pregnancy present the same appearance, regardless of the plane in which they are cut'.

The maternal capillaries are narrow tortuous channels, enclosed in the meshes of the trophoblastic lamellae (figure 39). In places, blood is recognizable within them, distinguishable from that in the foetal capillaries by the relative abundance of leucocytes. The endothelium consists of flattened cells, as in the dog, the puma and the brown bear among the carnivores, whereas in the cat and ferret it is more cuboidal (Amoroso 1952). These endothelial cells rest upon a conspicuous basement membrane which is intensely differentiated by the periodic acid schiff stain or any of the trichrome stains. *Loxodonta* also resembles the dog, and differs from the cat, in that giant decidual cells are lacking between the maternal vessels.

Separating the endothelium of the maternal capillaries from the foetal stroma are narrow laminae of the trophoblast composed solely of syncytial elements which possess less cytoplasm than previously. Their nuclei, measuring 6 to 8 μm in diameter, show little alteration in size and shape from the previous stage and they, as well as their accompanying cytoplasm, stain intensely with haematoxylin. As viewed with the light microscope, not a trace of cytotrophoblast can be found anywhere in the lamellae, and mitotic figures are practically absent.

At the previous stages the foetal connective tissue, which was relatively loose, had the appearance of a rather broad system of relatively thick mesodermal stems. In the mesodermal system of the present stage, the connective tissue carrying the slender foetal capillaries has become greatly attenuated so that the trophoblastic lamellae are brought much closer together and the tissue appears somewhat dense. In keeping with the disposition of the lamellae, the foetal capillaries are oriented for the most part in rows and the blood within them contains here and there nucleated red blood cells. The endothelium lining the capillaries is recognizable, and around the slightly larger vessels there is an additional sheath of foetal mesenchyme. Thus, it may be said that in regard to the architecture of the syncytial zone of the ripe placenta, *Loxodonta* resembles the carnivores more closely than either *Procavia* or the manatee, both of which have haemochorial labyrinths.

A feature of the syncytiotrophoblastic lamellae at mid-pregnancy which is worth emphasizing is the hyaline degeneration of some of those adjoining Zone II (figure 47*a*, *h.l.*, plate 10). This process, which can be observed to a greater or less extent in all the specimens of the present stage, but more particularly in E138, is destined to increase in extent and to characterize the later or final form of the syncytial zone (see below p. 24). One other feature of this zone is the occurrence of 'islands' of cytotrophoblastic arcades which enclose extravasated maternal blood; a typical example is shown in figure 40, plate 8. These cytotrophoblastic lacunae, which become increasingly numerous as gestation advances are histologically similar to, and presumably derived from, the marginal region of the placenta with which they are continuous and which is described below.

An important aspect of the placentation of *Loxodonta* concerns the manner in which the foetal trophoblast ensheathes the branches of the uterine arteries as they penetrate the placenta and pass up towards the surface of the labyrinth. This encasing of maternal vessels is accompanied by degeneration of both the adventitia and the media, so that ultimately the circulating maternal blood comes to be confined in a channel of endothelium, resting upon a lamina of collagenous fibres enclosed by trophoblast. Figure 42, plate 9, shows a portion of such a vessel in longitudinal section, and figure 43 shows part of the same section at a higher magnification. It may be seen that the darkly staining trophoblast which characterizes the outermost investment of the vessel is composed of elongated cells with indistinct cell boundaries and spindle-shaped nuclei, the chromatin of which is disposed peripherally in even-sized granules (figure 45, plate 9). The photographs also illustrate the abrupt transition from the syncytium of the lamella to the cellular component of the peri-arterial sheath, as well as the continuity of the core of the lamella with the eosinophilic matrix of the sheath. These features can also be seen in figure 44, plate 9 where a similar vessel is shown in transverse section together with thick-walled foetal vessels which run in the stroma of the major chorionic outgrowths (cf. figure 37, plate 8).

Similar changes have been described in the uterine vessels of a number of mammalian orders, notably the Sirenia, Hyracoidea and Carnivora by Wislocki and his associates (Wislocki 1935; Wislocki & Streeter 1938; Wislocki & van der Westhuysen 1940; Wislocki & Dempsey 1946; Wislocki & Amoroso 1956), who regard the ensheathing cells as taking origin from the trophoblast.

With regard to the remaining peri-arterial sheaths it will be noted that the amorphous basement membrane, which is interposed between the endothelium and trophoblast, represents all that still persists by way of a coat; its indented trophoblastic margin, in contrast to the regularity of its opposite (endothelial) surface, suggesting that it may be eroded by the trophoblast and constantly renewed by the endothelium. This appearance is in keeping with other observations on the activity of the placental trophoblast in the Sirenia (Wislocki 1935), Hyracoidea (Wislocki & van der Westhuysen 1940) and Carnivora (Wislocki & Dempsey 1946; Dempsey & Wislocki 1956; Wislocki & Amoroso 1956), where Wislocki and his associates have described an erosive or digestive action of the chorion, in that the collagenous fibres of the perivascular basement membranes lose their argyrophilia, swell and become transformed into a homogeneous substance, while at the same time collagen continues to be elaborated by the endothelium.

The views advanced above, concerning the possible formation and destruction of the perivascular basement membrane of the maternal arteries raise the question of the nature of the similar amorphous substance which surrounds the capillaries of the lamellae. In figure 43 one comes across a lamella which, in the plane of the section, is completely occluded by ground substance, whose homogeneity and density are quite similar to those of the peri-arterial sheath (cf. also figure 44). There is, however, this difference, that the borders of the syncytial trophoblast defining the lamella are smoother and more even, and the lining of the lamella does not exhibit the gross indentations displayed at the interfaces between cytotrophoblast and basement membrane, around the larger maternal vessels. Such similarities and differences are, however, consonant with the view that the amorphous substance of the capillary basement membranes is elaborated continuously by the endothelial cells of the capillaries within the lamellae, and is absorbed more evenly by the syncytial trophoblast.

Turning now to the cells lining the lumen of these afferent maternal trunks it is apparent that the extent to which the endothelium is preserved intact varies a good deal along their walls. In some localities, the sharp contours of an endothelium can be identified readily as a thin membrane, whereas in others it appears to be essentially lacking or scarcely discernible. To what extent these variable appearances reflect genuine histological differences, or should be regarded as artifacts of fixation, it is difficult to say with absolute certainty. The endothelium is exceedingly fragile, and it is our impression that our material may not have been adequately fixed for the preservation of so delicate a membrane, heavily encased as it is by the peri-arterial sheaths in these locations. On the other hand, there is a possibility that areas of the endothelium may be lost during life, so that an endothelio-chorial relationship no longer exists in these localities.

(iii) *The junctional or 'necrotic' zone* (*Zone II*)

We may now pass to a consideration of this zone at the time when it has essentially reached its definitive condition. It will be recalled that in our youngest specimens attachment was relatively superficial and invasion of the uterine wall had not progressed far, so that most of the thickness of the mucosa was still intact. In the present stage, however, the endometrium immediately adjoining the placental site is so completely disorganized that only remnants of the decidua in the shape of blood vessels and degenerating or necrotic cells of maternal origin are recognizable. The cells in question are ultimately phagocytozed and absorbed in some manner by the chorionic tissue and must be regarded as a continuing source of nutrition for the proliferating cells of the trophoblast.

The junctional zone at mid-term is broad, extremely cellular and dark-staining, and is sharply delimited from the syncytiotrophoblastic zone on the one hand, and from the underlying uterine musculature on the other. Figure 47, plate 10, illustrates these features of its topography. It consists in the main of cytotrophoblastic tissue, in the shape of intricately branched villi or trabeculae, as well as degenerating cells of various kinds. In occasional places small deposits or bands of an eosinophilic coagulum interrupt these fields. The foetal connective tissue in this zone is abundant and richly vascularized.

The tissues of the junctional zone, though exceedingly complex and difficult to analyze at this stage, nevertheless show a variably distinct separation into several layers. Immediately beneath the labyrinth it is characterized by widespread disintegration of tissues which are converted into a necrotic mass, as illustrated in figure 48, plate 11. Recognizable clumps or nests of degenerating cytotrophoblast occur at this level, their remains intermingling with the decidual residue. The nuclei of the cells constituting these nests, in contrast to the cytotrophoblast covering the proximal segments of the villi, stand out as pycnotic black dots enclosed in lightly stained vesicular cytoplasm, indicating that many of the cells are undergoing degeneration by liquefaction.

A little further from the foetal surface of the placenta the proximal segments of the cytotrophoblastic villi are relatively slender and irregularly branched (figure 49, plate 11). They are variable in length and in appearance, but are typically composed of a central core of richly vascularized mesoderm ensheathed by a layer of deeply staining cellular trophoblast. The epithelial cells (figure 51, plate 11) are columnar or polyhedral in shape, with sharply defined borders. They are large, with a single round nucleus in each cell. The cytoplasm is often produced into short blunt processes and the impression is gained that the cells in question are actively absorptive. Nearer the base of the placenta, the cytotrophoblast retains these characteristics, but the villi are less complexly branched, and they enclose a series of slit-like spaces or recesses (figure 50, plate 11). These recesses apparently communicate with the tortuous maternal channels in the syncytial lamellae. Nevertheless, they contain surprisingly little blood. Here and there, clumps of blood cells, or the shadows of erythrocytes, are recognizable, but for the most part the recesses contain a sort of globular amorphous debris, the nature and source of which are not clearly apparent. This material might be derived from the disintegration of masses of stagnant maternal blood which had escaped from the maternal capillaries and had passed beyond the point of recognition as individual blood cells. On the other hand, it resembles the globular and amorphous material in the spaces between the tips of cytotrophoblastic villi in the innermost layer of the junctional zone, which we can identify with some assurance as being derived from the uterine mucosa (see below). In all probability, both of these sources contribute to its formation.

In the innermost layer of the junctional zone, at the base of the placenta, blunt and relatively massive tongue-like outgrowths of foetal tissue can be seen (figure 52, plate 11). They penetrate the uterine mucosa to a variable degree. The bases of the uterine glands remain in places, but elsewhere the trophoblast reaches the muscularis. These processes of foetal tissue, formed clearly by the expanded ends of the main villous stems, have a thick central core of vascularized connective tissue ensheathed by a well-defined layer of columnar epithelium. They were described as 'lobate' by Assheton & Stevens (1905). The epithelial cells, which possess distinct boundaries, are columnar in shape. Each cell possesses a conspicuous, large, vesicular nucleus which is basally situated, while the distal end of the cell is prolonged into a spatulate process, the cytoplasm of which stains intensely and is homogeneous in appearance. Whether the surface irregularities seen in the cytotrophoblast covering the lobate villi be regarded as artifacts of fixation or not, they indicate in our estimation that the surface of these cells has a special and peculiar structure related to their functional activities.

As already mentioned, some of the lobate villi reach the uterine muscularis to which they are attached by their epithelial investments (figure 52). Others, on the contrary, penetrate to the base of the placenta but are not attached and between them there is a variable amount of detritus of the character shown in figure 53, plate 11. Some of this material is globular, granular or amorphous, while much of it resembles uterine milk and represents material which during life is fluid and which presumably nourishes the trophoblast. In addition to this means of securing nourishment a further source of pabulum for the embryonic tissues becomes available in the necrotic material which is always present at the boundary between the foetal and maternal tissues.

The maternal portion of the junctional zone is composed of irregular fields of degenerating or necrotic tissue as well as debris which is for the most part acellular, consisting of irregular bands of a material that stains intensely pink with eosin. Because of the intermingling of the cytotrophoblastic elements with the various necrotic products of maternal origin, the two are frequently difficult to distinguish. A number of extremely dilated venous channels are present in the zone (figure 48, *v.c.*), and in all probability they tap maternal blood which has circulated through the labyrinth.

In occasional places in the deeper part of this zone contiguous to the uterine wall, small haemorrhages result from ruptures of dilated maternal vessels. These extravasates produce fields composed of shadows of corpuscles and scattered strands of fibrin. Maternal white corpuscles occur interstitially throughout the junctional zone.

Uterine glands are nowhere well developed in the subplacental tissues, so that in *Loxodonta*, as in *Procavia* (Wislocki & van der Westhuysen 1940) the glands, by this stage at least, play a relatively insignificant role in the further differentiation of the placenta, nor can the histiotrophic secretion of the glandular epithelium be construed as a continuing source of nourishment for the foetus, as it is in carnivores (Amoroso 1952).

(iv) *The placental border (Zone III)*

To close the description of the mid-term placenta, a brief description of the placental border is necessary. The gross character of this region, which is relatively simple, is well displayed in the present series. The zonary placental band tapers off to a blunt wedge which for variable distances is apposed to, but not fused with, the uterine wall (see figure 16, plate 3). Adjacent to the wedge, in the angle beneath it, large endometrial glands open into the uterine cavity (figure 59, plate 12). It is characteristic of *Loxodonta* that these glands of the paraplacental border persist until term; they eventually become extremely dilated and distended with a lipid secretion.

The detailed character of the changes overtaking the terminal parts of the syncytiotrophoblastic lamellae in the marginal region (Zone III) of the placenta at mid-gestation are illustrated in figure 41, plate 9, and figure 54, plate 12. It will be observed, by comparison with figure 36, plate 7, how the changes barely initiated by the end of the third month of pregnancy, have now produced folds of cytotrophoblast—continuous with the lamellae—that are larger and blunter, and recesses or lacunae that are greater in extent.

The abrupt transition between syncytiotrophoblast and cytotrophoblast marks the point where the maternal capillaries enclosed within the lamellae lose their endothelial walls and allow the seepage of maternal blood from the labyrinth into the recesses lined by cytotrophoblast (figures 55 to 57, plate 12). In figure 55, a ruptured maternal capillary (*m.c.*) is shown, exactly at the junction of syncytial and cellular trophoblast. Maternal erythrocytes lie free, enclosed between laminae of cytotrophoblast, and there is some dark-staining material apparently derived from maternal endothelial cells. The cytotrophoblast of this region is shown in greater detail in figure 56. Distally, the tips of the foetal villi protrude into lakelets of extravasated blood, as shown in figure 57.

These microscopic extravasations, which extend inwards from the placental margin for variable distances along its inner face, occasionally appear as a series of small lacunae in the midst of the syncytial lamellae as described already (see figure 40, plate 8). They are equivalent to the border and central haematomata of the carnivores and may be regarded as additional devices for the histiotrophic nutrition of the foetus. In them the blood is stagnant, and the cells forming the limiting surfaces for the fibrin and disintegrating corpuscles are easily distinguishable from the syncytium in the bulk of the placental labyrinth, and are quite unlike the small-celled trophoblast of Zone II. In all of these sites where maternal blood escapes, whether it be in the marginal region or in the small lacunae, the pictures of the enclosing epithelium are essentially similar. The cells in question are quite large, with basally situated nuclei, and cytoplasm that is variably filled with minute vacuoles, granules, disintegrating erythrocytes and pigment. Clearly, therefore, they provide for the nourishment of the embryo by absorption of maternal blood plasma and corpuscles.

Noticeable for the first time over the whole marginal region of the placenta at this period, between the trophoblast and the contiguous endometrial surface is the appearance of fibrin (figure 54, *f.*, plate 12). It assumes the form of a faintly staining, acellular, eosinophilic coagulum spread out linearly between the foetal and maternal tissues, and it seals off the marginal recesses with their contained blood. Beyond the margin of the placenta, it extends into the shallow folds of the membranous chorion and, as was noted by Assheton & Stevens (1905), it contains no erythrocytes.

Wislocki (1935), in describing structures in the manatee placenta that have a configuration of their walls strikingly like the marginal enclosures of *Loxodonta*, advanced the idea of de-differentiation of the placental parenchyma, deriving the enclosing cellular trophoblast from the syncytiotrophoblast. In *Loxodonta*, however, there seems to be little evidence for such an origin of the cytotrophoblast. On the contrary, the present observations are more readily reconciled with the belief that the cytotrophoblast constituting this peculiar zone represents the persistent cellular investment of the free ends of those lamellae which do not invade the endometrium. It is evident, moreover, that these covering cells are especially concerned in forming limiting surfaces for the extravasated maternal blood plasma and corpuscles.

By analogy with the central and marginal haematomata of the carnivores (see Amoroso 1952; Wislocki & Amoroso 1956), one would expect this extravasated blood to have escaped from vessels in the uterine endometrium to which the cytotrophoblastic proliferations are applied. But against this view are the facts that in *Loxodonta* the uterine epithelium of the paraplacenta remains intact and forms a continuous limiting surface for the mucosa, and that in no part of this region do uterine vessels discharge their contents into the uterine cavity, even at the time of the first appearance of these haematomata (see pp. 14 and 15).

Another reason for believing that the extravasated blood does not emanate from vessels in the uterine mucosa is that the maternal capillaries within the syncytiotrophoblastic lamellae of the labyrinth can be traced to the point where they communicate openly with the lacunar spaces lined by cytotrophoblast (figure 55, plate 12). Here and there, also, the syncytiotrophoblast can be seen surrounding degenerating maternal capillaries, and dark-staining cells which we believe to be derived from the disrupted endothelium lie scattered among the stagnant maternal corpuscles.

Finally, an additional reason for suggesting that the extravasated blood comes from maternal blood vessels which have traversed the labyrinth is the striking resemblance of these lakelets of stagnant maternal blood to extravasations near the surface of the placenta of the manatee (Wislocki 1935). Emphasis is placed on this similarity because Wislocki's study showed that the placental affinities between the manatee and the elephant are quite close. In the former animal there appeared to be little doubt of the derivation of the extravasations from the tortuous lacunae of the labyrinth.

It is to be observed, moreover, that since the marginal lacunae are continuous with the syncytial lamellae, the topographic relations of the former structures to the latter are very different from those between the lamellae and marginal haematomata of the dog or cat. For in these creatures the variously folded extensions of the chorionic membrane, constituting the green and brown borders, arise from the foetal side of the placenta and extend through the depth of the placental band. Consequently, the central and marginal regions are sharply demarcated [in a plane vertical to the surface of the endometrium. In *Loxodonta*, on the other hand, the primary demarcation between the two zones is horizontal, as seen in the transect of the placental band (figure 1) since it lies between the proximal syncytiotrophoblastic zone of the chorionic proliferations and the distal growing tips of the placental villi where the trophoblast is cellular.

There is thus direct evidence that blood from the maternal capillaries of the labyrinth contributes to that which lies within the marginal enclosures, and none for any other source. Accordingly, we may conclude that this region of haemostasis, and presumably of phagocytosis of blood cells by the cytotrophoblast, is maintained solely by the release of blood from the maternal capillaries of the labyrinth. A communication between these capillaries and the extravasated blood in the lacunae was described by Assheton & Stevens (1905) but their interpretation of the dynamics of the situation was entirely different from our own (see p. 28).

(v) *The paraplacental chorion*

The chorion, where it leaves the placental borders, to become membranous, is composed of a thin sheet of allantoic endoderm and a thin lamina of cuboidal cytotrophoblast facing the uterine cavity; allanto-chorionic mesenchyme, conveying the chorionic vessels, intervenes between the two. The paraplacental chorion (figure 46, plate 9) constitutes a smooth membrane over most of its surface, but in the vicinity of the placental border it is variously folded, forming shallow pockets or recesses which increase in depth and complexity as one approaches the edge of the placenta, being replaced finally on the ultimate placental margin, by the cytotrophoblastic arcades of Zone III containing stagnated maternal blood. There is thus a gradual transition from a simple to a complex surface and the trophoblastic proliferation of the placenta is accomplished gradually without any sharp line of demarcation between the membranous chorion and the labyrinth.

The chorionic epithelium supervening upon the mesoderm and facing the uterine cavity has a variable morphology. Its cells are at times polygonal, at times more columnar, and again over large areas low or even flattened. In some outlying regions, also, the chorionic mesoderm appears to be entirely denuded, but this may have been artificially produced. Some of the columnar cells, more especially those bordering the deep recesses, appear to be vacuolated.

Intervening between the shallow trophoblastic indentations, and in contact with the epithelium, are a few extravasated red blood cells and an exceedingly narrow layer of acellular fibrinous material. But only the deepest pockets, which communicate with the lamellae of the labyrinth, contain large amounts of stagnant maternal blood. It may be presumed that some of the blood which, according to our interpretation (see pp. 21 and 22) is liberated from the vessels of the labyrinth into the deep marginal recesses lined by cytotrophoblast, may reach the uterine cavity and enter the shallower pockets of the outlying chorion. A few millimetres from the border of the placenta, acellular material representing in all probability the coagulated secretions of the uterine glands as well as fibrin, dwindles while the membranous chorion converges towards the uterine wall, to spread out over the uterus as a loosely apposed membrane.

(vi) *The paraplacental endometrium*

In the paraplacental region the chorionic epithelium lies in loose apposition to the uterine wall, and large endometrial glands open into the uterine lumen, as described above (p. 20, and figure 59, plate 12). The basal portions of the glands are dilated and are separated by loose interglandular stroma, the whole giving a sponge-like appearance to the endometrium which contrasts with that of the non-pregnant animal, shown in figure 58. Many of the glands seem to have been so much drawn out as to become virtually a part of the surface of the endometrium. The glandular and endometrial epithelium at this stage is variable in morphology. It might be quite flattened or, as is the rule, cuboidal, but in some isolated areas it is columnar and the cells appear to possess ciliated borders.

(*c*) *The placenta at term*

(i) *General*

In the preceding paragraphs we have described the development of the placenta of *Loxodonta* up to the middle of pregnancy, at which time the major characteristics of the definitive organ are well established. Its subsequent history, up to the time of parturition, comprises those slowly evolving changes, of a relatively slight and secondary nature, which characterize the final phases of placental maturity. To illustrate these changes we have chosen a pregnant uterus containing a foetus (E 148) of about 120 kg, which is estimated to be very near term.

Low power views of a series of photomicrographs from the region of greatest growth of the trophoblast in the placenta at term are shown in figures 60, 62 and 63, plate 13, which together show the histology of the syncytiotrophoblastic and junctional zones (I and II). While Zone I still comprises the major part of the placenta, Zone II now constitutes less than one third of its total thickness. The junctional zone at term is consequently relatively shallow as contrasted with the much thicker basal cytotrophoblast of earlier stages. The character and extent of the border cytotrophoblast (Zone III) is little changed.

(ii) *The syncytiotrophoblastic zone* (*Zone I*)

Although the syncytial zone increases enormously in thickness and in width as well as in circumferential area as pregnancy advances, it undergoes relatively little change in structure. Seen with the light microscope, the dark-staining lamellae appear as relatively thin, irregularly twisting sheets of syncytial trophoblast that enclose the tortuous maternal capillaries. These lamellae (figure 60) are now separated by only the most slender strands of foetal connective tissue in which are abundant capillaries, often situated immediately below, and indenting the syncytium (figure 61, plate 13). The 'intra-epithelial' capillaries are a striking feature of the full-term placenta of *Loxodonta* and the time of their first appearance marks the beginning of the final phase of placental maturity.

As previously mentioned, an important feature of the topography of the syncytial zone at full term pertains to the occurrence, at several points along its innermost margin, and elsewhere, of lamellae showing various degrees of hyalinization. This process had begun in earlier stages in which we referred to it simply as a region of hyaline or fibrinoid degeneration between the syncytiotrophoblastic zone and the contiguous junctional zone (p. 17). In the present specimen the changes are more widespread and further advanced and they also occur irregularly throughout the syncytial zone.

Figures 65 to 67, plate 14, illustrate the detailed character of the changes overtaking the lamellae. In these photomicrographs, instead of an abundant, fine-meshed, close-set trellis work of syncytial trophoblast, the lamellae are relatively sparse, somewhat swollen and blotchy in appearance, and widely separated from each other by a faintly staining acellular matrix. As these changes proceed the maternal capillaries within the lamellae are progressively obliterated. Their endothelial cells become unrecognizable and their remains, together with the basement membrane, give rise to a conspicuous lamina of amorphous material which is intensely differentiated by the periodic-acid Schiff reagent and which appears to be surrounded solely by a relatively thin layer of syncytial trophoblast. The onset of these changes marks the end of the functional life of the lamella.

In addition to changes in the sinus-like capillaries of the lamellae, a curious transformation was noted in the full-term placenta, involving some of the larger maternal vessels which traverse the junctional zone to supply the labyrinth. Figure 68, plate 14 shows such a vessel; it will be noted that its lumen is extensively filled with concentric laminae of amorphous material which stains intensely with eosin and which appears to have originated from the vessel wall. Indeed, occasionally one comes across vessels which appear to be completely occluded. In some, the fibrinoid changes, besides extending into the lumen, tend to include the wall of the vessel, infiltrating or even replacing the muscular and adventitial coats. It is probably a sign that the foetal-maternal connexion is becoming relatively inactive.

(iii) *The junctional zone* (*Zone II*)

Detailed photographs of the junctional zone in the full-term placenta are presented in figures 62 and 63, plate 13. As has been stated above, it now constitutes no more than one third of the total thickness of the placenta, a transformation which involves the re-arrangement of its component trophoblastic villi. Their terminal portions, which were relatively short and blunt in the preceding phase of development (figures 50 and 52, plate 11) have now become long, slender and trabeculated. The network of trabeculae encloses relatively numerous maternal blood lacunae. In the superficial outer portion of the junctional zone (figure 62), the nearly parallel maternal vascular channels, containing the ghosts of maternal corpuscles as well as an eosinophilic coagulum of fibrin, alternate with foetal trabeculae. The trabeculae are clothed by a dark-staining layer of cytotrophoblast which forms the lining of the adjacent blood lacunae, the covering cells ranging from almost cuboidal forms, through columnar ones, to places where they are palisade-like. Here, the major trabeculae, running for the most part horizontally, contain a relatively stout core of foetal mesoderm in which sizeable blood vessels are present. Below them, and running chiefly perpendicularly, is the main mass of villi connecting the placenta to the uterine wall. Such an area of attachment is shown in figure 63. As the photograph shows, there is an abrupt boundary that marks the region of abuttal of the junctional zone on the uterine wall. It is apparent from comparison of this photograph with the pictures of the zone of attachment in early pregnancy and at mid-term (figure 28, plate 6 and figure 52, plate 11), that the anchoring villi have become materially altered. They have apparently absorbed most of the intervening material of maternal origin and have eventually been overtaken by the degenerative changes which began in the outer part of the junctional zone, near the labyrinth. Erosion of the uterine glands has been completed over the whole area of attachment, and the anchoring villi abut directly upon the muscularis.

(iv) *The placental border* (*Zone III*)

The occlusion of lamellae within the labyrinth towards the end of pregnancy, as described above, appears to reduce the escape of maternal blood into the marginal crypts, and in many places the crypts contain no blood cells. The coagulum which overlies the mouths of the crypts at mid-term (figure 54, plate 12) is at least as prominent at full term. The foetal villi themselves appear less vascular; the epithelial cells, which still have conspicuous cell walls, are reduced in height and their nuclei are small and dense. These marginal villi are shown in figure 64, plate 13. Their condition contrasts with that of the corresponding region at mid-pregnancy, shown in figure 57, plate 12, where highly vascularized villi, covered with active cytotrophoblastic epithelium, were bathed in extravasated maternal blood.

THE BLOOD SUPPLY TO THE PLACENTA

Studies and interpretations of the manner of circulation in the elephant placenta are not numerous (Assheton & Stevens 1905; Assheton 1906; Boecker 1907). The early description of Assheton & Stevens, based as it was on incompletely preserved material, differs in several major particulars from our own. In *Loxodonta* the principal uterine vessels, distributed regularly over the base of the placenta, feed the labyrinth by arterial branches which pass more or less obliquely towards the foetal surface of the placenta (figures 28 and 37). They give off, at frequent intervals, small branches which enter the tortuous syncytial lamellae; the abrupt transition between the parent vessel enclosed in its trophoblastic sheath, and the lamella, is well illustrated in figures 42 to 44. The endothelial walls of the capillaries are separated from the trophoblast by the homogeneous matrix described above. In our earliest specimen, E1, these maternal capillaries carry the blood to the foetal-maternal junction and to the marginal zone. At many places at the base of the placenta, these efferent vessels become confluent with larger venous channels which convey the blood to the veins in the muscularis. In the marginal zone, on the other hand, even at this early stage, some blood escapes into small cytotrophoblastic lacunae, where it becomes stagnant and is not returned to the maternal circulation.

By mid-pregnancy the marginal zone has become much better established, and extravasated blood within it forms a conspicuous feature of the placenta at this stage. By this time also, the junctional zone has acquired its definitive form and there is some extravasation of blood within it. In the later stages of gestation the placental blood supply is increased in extent by the circumferential growth of the placental band, and with the attenuation of the trophoblastic lamellae (compare figure 38 with figure 60) the capillary plexus becomes much more dense. The basement membrane is reduced in prominence and the maternal capillaries become even more closely apposed to the trophoblast (figure 61). As in the earlier stages, many of them discharge their contents into confluent venous channels prior to entering the uterine veins. Before parturition, however, a large part of the maternal capillary system within the labyrinth (figures 65 to 67), and many of the larger afferent maternal vessels in the junctional zone (figure 68), are sealed off by a hyaline transformation as described in an earlier section (p. 24). Thus in the final stage, many of the placental vessels supplying and draining the labyrinth no longer convey maternal blood.

The course of the foetal circulation in the early placenta has already been described (p. 8 et seq.). In the ripe placenta there is a progressive attenuation of the foetal stroma separating the lamellae, with a corresponding increase in the density of the capillary vessels, many of which indent the syncytial trophoblast and pursue an intra-epithelial course. Thus, at term, when it is realized that over a considerable area of the placental band, only the thinnest laminae of epithelial cytoplasm, and a delicate network of collagenous fibres, separate the foetal vessels from the maternal tissue (figure 61), the intra-epithelial capillaries acquire greater significance as a means of exchange between the mother and the foetus.

DISCUSSION

Although Owen (1857) noted a distinct allantoic cavity or series of cavities, Assheton & Stevens (1905), who compared their own specimen (an afterbirth) with Owen's half-term specimen, thought that there was no allantoic cavity. They could not, therefore, identify the 'subcircular bodies' which we have referred to as 'allantoic pustules' as being protuberances on the endodermal lining of the allantois. Their histological examination was, nevertheless, remarkably complete considering the nature of their material and it is evident, from examination of some of their preparations which survive, that imperfect fixation accounts for most of the discrepancies between their description and our observations. In the light of present knowledge of the comparative anatomy of the placenta it is possible to compare the placentation of the elephant, in some detail, with that of several genera with which it has some degree of phylogenetic affinity.

It is clear from the present investigation with the light microscope that the elephant and the hyrax are strikingly similar in respect of the morphology of the embryonic membranes. In the detailed structure of the placenta itself, on the other hand, there are major differences, especially in the development and growth of the trophoblast, the vasochorial nature of the elephant placenta (see p. 29), and the presence in it of marginal extravasations of blood reminiscent of the marginal haematomata of the dog and some other carnivores.

In the disposition of the lamellae of the labyrinth, the placenta of the elephant resembles that of the manatee (Wislocki 1935) more closely than that of the hyrax. In its finer structure, however, the elephant placenta is vasochorial, whereas that of the manatee, like that of the hyrax, is haemochorial. The three forms are clearly somewhat similar to each other in placentation and different from any others yet described, and they may be compared with respect to several major characteristics.

In the hyrax (Thursby-Pelham 1925; Wislocki & van der Westhuysen 1940) and the dugong (Harting 1878; Turner 1889) and conceivably in the manatee (Wislocki 1935), villous proliferations occur over the whole surface of the chorion in the early stages of development, and the zonary condition arises when proliferation ceases over the polar areas of the sac, which then become membranous. Apical patches of less complex villi occur in the Asian elephant, but in the African species proliferation is confined to the equatorial region of the blastocyst, even in early stages.

The large quadrilocular allantois of the elephant is apparently exactly similar to that of the hyrax, and this feature constitutes the most striking resemblance between the two genera, at least as far as the reproductive organs are concerned. The topography of the allantois is slightly different in the manatee, but the characteristic dilatation of the sac between 'leashes' of umbilical vessels occurs in all three species. It is interesting that this very striking and peculiar configuration of the allantois is also observed in the unrelated Cape ant-eater, *Orycteropus* (Mossman 1957). It also occurs in the lemurs (Hill & Burne 1922; Hill, Ince & Subba Rau 1928; Hill 1932), and Wislocki & van der Westhuysen (1940) discussed the possible significance of this similarity, together with Hill's suggestion that the arrangement represents a step in the evolution of the body-stalk. They concluded that the similarity with the lemurs was without phylogenetic significance and that the umbilical arrangement had no discernible evolutionary tendency.

Prominent pustules protrude into the cavity of the allantois in the manatee as in the elephant, but not in the hyrax. It is impossible to assess the significance of the increased area of endodermal surface which they bring into contact with the allantoic fluid. It may prove to be significant that they are most prominent in the largest, and quite absent from the smallest, of the three species, but their function remains completely unknown.

The extravasation of blood in the marginal regions of the elephant placenta is unique among placental mechanisms hitherto described, in that blood which has passed through the labyrinth in maternal vessels is released into a space which communicates with the uterine lumen. The release of blood into such a space occurs in the marginal haematomata of the carnivores, but it is released from vessels in the adjacent region of the uterine wall, and the main vascular supply of the placental labyrinth is not involved. A closer parallel with the elephant, in this respect, is provided by the manatee (Wislocki 1935), which has 'curious arcades of trophoblast' at the surface of the placenta, 'into which stagnated maternal blood escapes. The trophoblast enclosing these spaces is differentiated into columnar cells which are actively phagocytic, being filled with phagocytized red blood cells and pigment.' These 'spaces' are evidently homologous with the marginal enclosures, between adjoining layers of phagocytic cytotrophoblast, in the placenta of the elephant. But whereas the extravasation occurs within the closed (foetal) extremities of the lamellae of the labyrinth of the manatee, it occurs at their opposite extremities in the elephant, where they communicate with the potential cavity of the uterine lumen. There are no corresponding marginal regions in the placental band of the manatee.

These pockets of haemostasis, and eventual phagocytosis, in the elephant and the manatee, are evidently 'the equivalent of the haematomata...and other devices, mostly paraplacental structures, for the histiotrophic nourishment of mammalian foetuses' (Wislocki 1935). The 'device' of phagocytic absorption of extravasated erythrocytes appears to supply iron to the foetus (see Amoroso 1952) and the presence of considerable amounts of iron in the marginal region of the elephant placenta was recorded by Assheton (1906), who found it to be especially concentrated in the walls of the foetal capillaries of this region.

Although the marginal region becomes relatively reduced in extent towards the end of pregnancy in the African elephant, it is still present and quite extensive in specimens which must have been very near term. It is clear from the earlier stages represented by E 1 and E 36 that maternal blood is not released in any quantity until the chorionic sac is sufficiently distended to maintain a subspherical shape and to press closely against the uterine wall. This pressure, and the presence of the coagulum which seals off the open ends of the marginal enclosures (figure 54, plate 12), evidently prevents loss of blood by seepage into the uterine lumen. Assheton & Stevens (1905) described no 'marginal zone' in the full-term specimen, but recognized its prominence in Owen's mid-term placenta and concluded that they had 'all the stages showing how the maternal blood gains access to the foetal part of the placenta'. According to these investigators the maternal blood appeared to be forced up the intervillous spaces, 'crushing up the fine reticulum of the plasmodium, thereby forming the well-defined non-cellular walls so characteristic of the full-term maternal channels.' They traced the channel of blood and detritus up to a blood channel without endothelium and thence to a blood vessel with endothelium. The arteries of the central region of the placental band were therefore regarded as having developed from channels of maternal blood, bounded by foetal tissue, of the kind still to be found in the younger (marginal) regions until the last stages of pregnancy. Such an interpretation of the vascular arrangements within the placenta is no longer tenable since our younger stages show that the blood supply to the labyrinth has acquired many of its definitive characteristics long before the marginal zone is fully differentiated.

Marginal or central haematomata are usually associated with an endothelio-chorial placenta in the Carnivora, e.g. bear, dog, cat, ferret and the African polecat, *Zorilla*, (see Amoroso 1952), but are said to be lacking in the African civet (Strahl 1905). Watson (1881) reported that they were absent in the raccoon, but Biggers & Creed (1962) described the presence of an 'haemophagous organ' in this species. This structure appears to resemble a marginal haematoma, although the authors reject the designation and state that the organ described in the raccoon differs in the disposition of the foetal and maternal tissues within it. There are no marginal haematomata in the hyena, which has a haemochorial placenta (Amoroso 1955*b*, 1959).

The 'giant cells' of decidual origin which occur in the hyrax (Thursby-Pelham 1925; Wislocki & van der Westhuysen 1940) are not found in the elephant placenta. During the part of gestation represented by our material, the trophoblast is single-layered throughout, with the possible exception of relatively minute areas where it invests the larger maternal vessels, as shown in figures 42 to 44, plate 9. These photographs are strikingly similar to those of corresponding regions in the hyrax and in the manatee. The nature of the single-layered trophoblast which invests the lamellae in the labyrinth is open to question. We have referred to it as syncitio-trophoblast because cell boundaries are not distinguishable within it with the light microscope, yet it is difficult to envisage its mode of growth if it is regarded as a true syncytium. In our youngest specimen, attempts to resolve this question with the electron miscroscope have been frustrated by inadequate fixation of the material, but indentations of the limiting membrane, partially separating adjacent nuclei, suggest that the cytoplasm is not truly continuous. Furthermore, the presence of collagenous fibres, and occasional cells, seen in the electron micrographs between the trophoblast and the maternal endothelium, indicates that the placenta is vasochorial rather than, in the strict sense, endotheliochorial.

The invasive border of the trophoblast of the elephant is very different from that of the hyrax, but bears some resemblance to that of the manatee. Although the earliest stages of placentation in the elephant have yet to be described, the condition already attained by our earliest specimen suggests that there is no massive proliferation of the trophoblast at any stage.

Wislocki & van der Westhuysen (1940) concluded that 'In regard to placentation the Hyracoidea, Sirenia and Proboscidia form a closely related group', basing this conclusion, with regard to the elephants, on the limited data presented by Chapman (1880, 1899), Assheton & Stevens (1905) and Boecker (1907) for the Indian elephant. They also pointed out the resemblance between these three groups and the carnivores and sloths in the possession of penetrating trophoblast (and consequently a deciduous placenta) and in the gradual localization of the placenta from a diffuse to a zonary type. They noted the supposed haemochorial character of the elephant placenta as a further point of resemblance with the manatee and the hyrax. It is now clear that the African elephant placenta is in fact vasochorial, resembling in this respect that of all the carnivora that have been described, with the exception of the hyena (Amoroso 1955*b*, 1959; Morton 1956).

The African elephant differs from the Indian species in that it never possesses, or very soon loses, the villous patches which occur over the polar regions of the embryonic sac in the latter. It is probable that its topography as a zonary band, often interrupted at one or more points, does not result from the attrition of polar trophoblast but from the early vascularization of the chorion by allantoic vessels at one or more places on the blastocyst wall.

The bulk of the material on which this account is based was collected by one of us in circumstances described previously (Perry 1953). We are indebted to Dr R. V. Short, of the Department of Veterinary Clinical Studies, Cambridge University, for the youngest specimen described here.

The work was supported in part by the United States Public Health Service Grant GMO 6489-04.

It is a pleasure to acknowledge the technical assistance of Mrs J. Snelling and Mr P. N. O'Donoghue in histological preparation, and that of Mr A. R. Goffin and Mr R. Gallup in the photography, of the material.

REFERENCES

Amoroso, E. C. 1952 *Marshall's physiology of reproduction.* Ed. by A. S. Parkes. 3rd ed., vol. 2, p. 127. London: Longmans, Green and Co.

Amoroso, E. C. 1955*a* De la signification du placenta dans l'évolution de la gestation chez les animaux vivipares. *Ann. Endocr., Paris,* **16**, 435-447.

Amoroso, E. C. 1955*b* *The comparative anatomy and histology of the placental barrier.* Gestation, p. 119. Ed. L. B. Flexner. New York: Josiah Macy, Jr. Foundation.

Amoroso, E. C. 1959 Comparative anatomy of the placenta. *Ann. N.Y. Acad. Sci.* **75**, 855-872.

Assheton, R. 1906 The morphology of the ungulate placenta, particularly the development of that organ in the sheep, and notes upon the placenta of an elephant and hyrax. *Phil. Trans.* B, **198**, 143-220.

Assheton, R. & Stevens, T. G. 1905 Note on the structure and development of the elephant's placenta. *Quart. J. Micr. Sci.* **49**, 1-37.

Beddard, F. E. 1902 Report on the birth of an Indian elephant in the Society's menagerie. *Proc. Zool. Soc. Lond.*, p. 320.

Bernard, C. 1879 *Leçons sur les phénomènes de la vie.* Paris.

Biggers, J. D. & Creed, R. F. S. 1962 Two morphological types of placentæ in the raccoon. *Nature, Lond.* **194**, 103-105.

Blanford, W. T. 1888-91 *The fauna of British India, including Ceylon and Burma; Mammalia.* London: Taylor and Francis.

Boecker, E. 1907 Zur Kentnis des Baues der Placenta von *Elephas indicus. Arch. mikr. Anat.* **71**, 297-324.

Chapman, H. C. 1880 The placenta and generative apparatus of the elephant. *J. Acad. Nat Sci., Philad.* **8**, 413-422.

Chapman, H. C. 1899 La gestation et le placenta de l'éléphant (*E. asiaticus*). *C.R. Soc. Biol., Paris,* **1**, 525-526.

Dempsey, E. W. & Wislocki, G. B. 1956 Electron microscopic observations on the placenta of the cat. *J. biophys. biochem. Cytol.* **2**, 743.

Duval, M. 1893-95 Le placenta des Carnassiers. *J. Anat., Paris,* **29**, 249, 426, 633; **30**, 189, 644; **31**, 38.

Ferrier, A. J. 1948 *The care and management of elephants in Burma.* London: Steel Bros and Co.

Hammond, J. 1927 *The physiology of reproduction in the cow.* Cambridge University Press.

Harting, P. 1878 Het ei en de placenta van *Halicore dugong. Diss., Utrecht,* pp. 1-65.

Heuser, C. H. & Wislocki, G. B. 1935 Early development of the sloth (*Bradypus griseus*) and its similarity to that of man. *Contr. Embryol. Carneg. Instn,* **25**, 1.

Hill, J. P. 1932 The developmental history of the primates. *Phil. Trans.* B, **221**, 45-176.

Hill, J. P. & Burne, R. H. 1922 The foetal membranes and placentation of *Chiromys madagascariensis. Proc. Zool. Soc. Lond.* pp. 1145-1170.

Hill, J. P., Ince, F. E. & Subba Rau, A. 1928 The development of the foetal membranes in *Loris. Proc. Zool. Soc. Lond.* pp. 699-716.

Jenkinson, J. W. 1906 Notes on the histology and physiology of the placenta in ungulates. *Proc. Zool. Soc. Lond.* **1**, 73.

Morton, W. R. M. 1956 Placentation in a full-term spotted hyena (*Crocuta crocuta* Erxleben). *J. Anat., Lond.* **90**, 581.

Mossman, H. W. 1937 Comparative morphogenesis of the fetal membranes and accessory uterine structures. *Contr. Embryol. Carneg. Instn*, **26**, 129–246.

Mossman, H. W. 1957 The fetal membranes of the aard vark. *Mitt. Natf. Ges. Bern* (N.F.), **14**, 119–127.

Owen, R. 1857 Description of the foetal membranes and placenta of the elephant (*E. indicus* Cuv.), with remarks on the value of placentary characters in the classification of the mammalia. *Phil. Trans.* **147**, 347–353.

Owen, R. 1868 *On the anatomy of vertebrates*, vol. 3. London: Longmans, Green and Co.

Perry, J. S. 1953 The reproduction of the African elephant, *Loxodonta africana*. *Phil. Trans.* B, **237**, 93–149.

Perry, J. S. 1964 The structure and development of the female reproductive organs of the African elephant. *Phil. Trans.* B, **248**, 35.

Sangvichien, S. 1951 A study of elephant's placenta. From: *Collected papers of the Science Conference, Science Society of Thailand, 1951.*

Strahl, H. 1905 Beiträge zur vergleichenden Anatomie der Placenta (*Limuriden, Viverra civetta,* und *Centetes ecaudatus*). *Abh. senckenb. naturf. Ges.* **27**, 262–319.

Thursby-Pelham, D. 1925 The placentation of *Hyrax capensis*. *Phil. Trans.* B, **213**, 1–20.

Turner, W. 1875 On the structure of the diffused, the polycotyledonary, and the zonary forms of placenta. *J. Anat., Lond.* **10**, 127.

Turner, W. 1889 On the placentation of *Halicore dugong*. *Trans. Roy. Soc. Edinb.* **35**, 644–662.

Watson, M. 1881 On the female organs and placentation of the raccoon (*Procyon lotor*). *Proc. Roy. Soc.* B, **32**, 272–298.

Wislocki, G. B. 1935 The placentation of the manatee (*Trichechus latirostris*). *Mem. Mus. Comp. Zool., Harvard College*, **54**, 159–178.

Wislocki, G. B. & Amoroso, E. C. 1956 The placenta of the wolverine (*Gulu gulu luscus* (Linnaeus)). *Bull. Mus. Comp. Zool. Harv.* **114**, 91–100.

Wislocki, G. B. & Dempsey, E. W. 1946 Histochemical reactions in the placenta of the cat. *Amer. J. Anat.* **78**, 1–45.

Wislocki, G. B. & Enders, R. K. 1941 The placentation of the bottle-nosed porpoise. *Amer. J. Anat.* **68**, 97–125.

Wislocki, G. B. & Streeter, G. L. 1938 On the placentation of the macaque (*Macaca mulata*), from the time of implantation until the formation of the definitive placenta. *Contr. Embryol. Carneg. Instn*, **27**, 1–66.

Wislocki, G. B. & van der Westhuysen, O. P. 1940 The placentation of *Procavia capensis* with a discussion of the placental affinities of the Hyracoidea. *Contr. Embryol. Carneg. Instn*, **28**, 65–68.

Description of plates 1 to 14

Key to lettering

1, 2, 3, 4	openings of the four sacculations of the allantois	*m.c.*	maternal capillary
a.	antrum	*ov.*	ovary
a.a.	allanto-amnion	*pr.*	probes
a.c.	allanto-chorion	*syn.*	syncytiotrophoblast
c.	conceptus	*t.*	tongue of trophoblast
c.l.	corpora lutea	*ur.*	urachus
f.	fibrin layer	*v.c.*	venous channels
f.c.	foetal capillary	*y.s.*	yolk sac
h.l.	hyaline lamellae		

PLATE 1

(All photographs of E 1)

FIGURE 2. Uterus immediately after removal, from the ventral surface. The conceptus (*c*) is seen as a swelling at the base of the right horn. Several corpora lutea (*c.l.*) are seen on the surface of the ovaries (*ov.*). (× 0·14.)

FIGURE 3. Conceptus, opened from dorsal surface after fixation; foetus *in situ.* (× 1·3.)

FIGURE 4. Transect through fixed conceptus, foetus removed. (× 1·3.)

FIGURE 5. Foetus, after fixation. (× 3.)

PLATE 2

(All photographs of E 36)

FIGURE 6. Allanto-chorionic sac removed from uterus at dissection, fixed and photographed by incident light to show extent and nature of villous areas. (× 0·7.)

FIGURE 7. Same specimen as figure 6, but photographed by transmitted light to show the course of the allantoic blood vessels and the complete absence of villous proliferation outside the zonary attachment band. (× 0·7.)

FIGURE 8. Endodermal surface of allanto-chorion in the extra-placental region, at the junction of adjacent allantoic loculi. The small light patches are developing allantoic pustules. (× 3·5.)

FIGURE 9. Endodermal surface of allanto-chorion in the area of placental attachment. (× 4.)

FIGURE 10. Foetus, after fixation. (× 1·5.)

FIGURE 11. The four pairs of umbilical vessels and the corresponding allantoic loculi as seen after removal of part of the allanto-chorion (cf. figure 19, plate 4). (× 2·5.)

PLATE 3

FIGURE 12. E 115. Uterus, photographed at time of dissection. (× 0·12.)

FIGURE 13. E 117. Placental band after removal of uterine wall. Photographed in the fresh condition. (× 0·12.)

FIGURE 14. E 117. The uterine wall reflected from the area of placental attachment, showing the main vessels which traverse the foetal-maternal junction, exposed by gentle traction. (× 0·25.)

FIGURE 15. E 147. Placental band, transected after fixation. Foetal tissue only. (× 1·0.)

FIGURE 16. E 138. Placental band, transected after fixation. Outer layers of uterine musculature and serosa removed before fixation. (× 1·0.)

FIGURE 17. E 148. Placental band, transected after fixation. Foetal and maternal tissue held in apposition. Whole thickness of uterine wall preserved. (× 1·0.)

PLATE 4

(All figures × 0·3 approx.)

FIGURE 18. E 147. Allanto-chorionic sac, after fixation in formalin, showing one of three interruptions in the placental band.

FIGURE 19. E 122. Allanto-chorionic sac opened beneath the 'arcade' formed by the four pairs of umbilical vessels.

FIGURE 20. E 122. The outer wall of one of the allantoic compartments has been cut and reflected. Probes (*pr.*) mark the limits of this compartment.

FIGURE 21. E 122. The second, larger, lateral compartment of the allantois has been opened. This photograph, and figure 20, show the distribution of allantoic pustules on the endodermal surface of the allanto-chorion (*a.c.*) and the simple membranous nature of the allanto-amnion (*a.a.*).

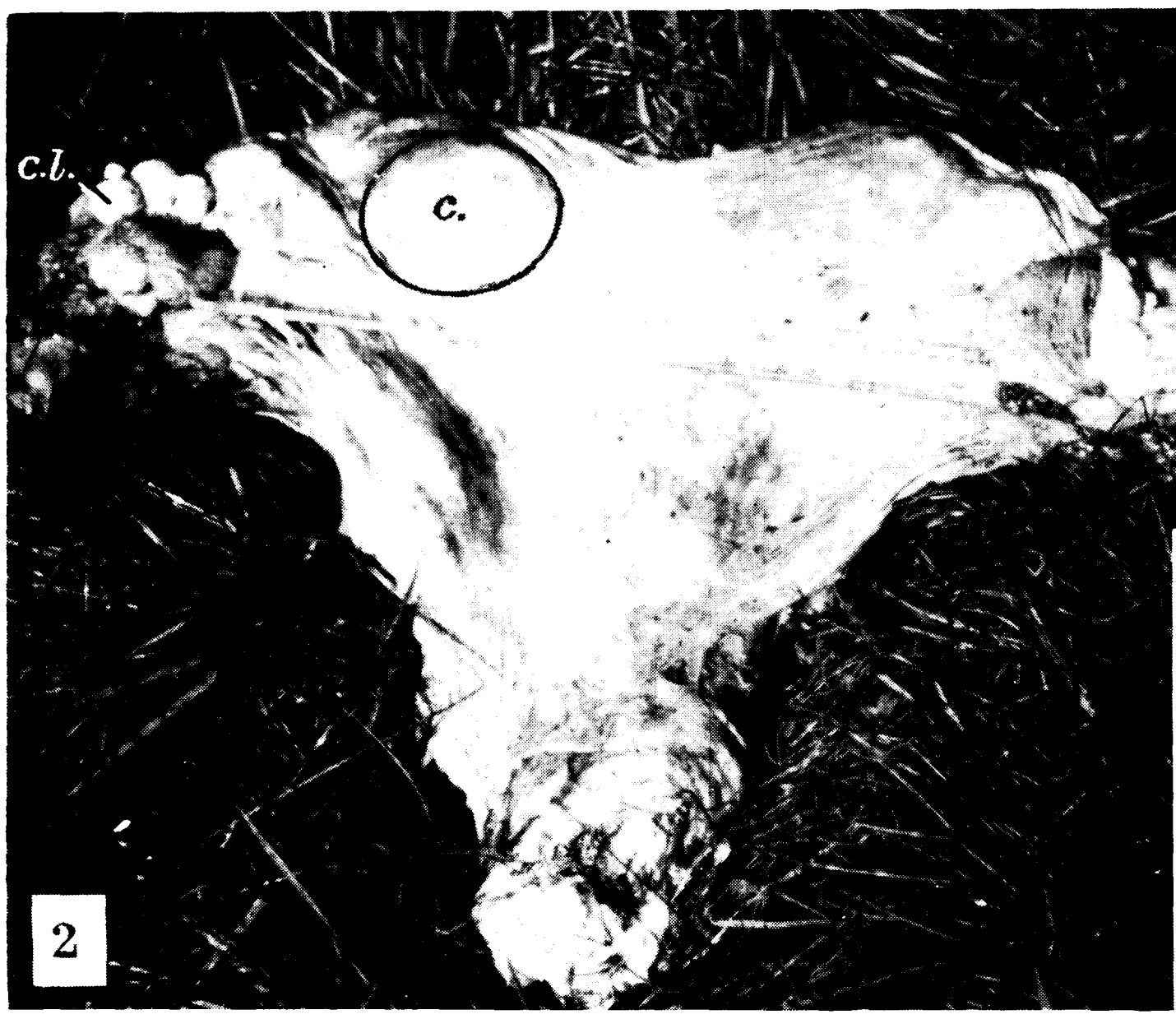

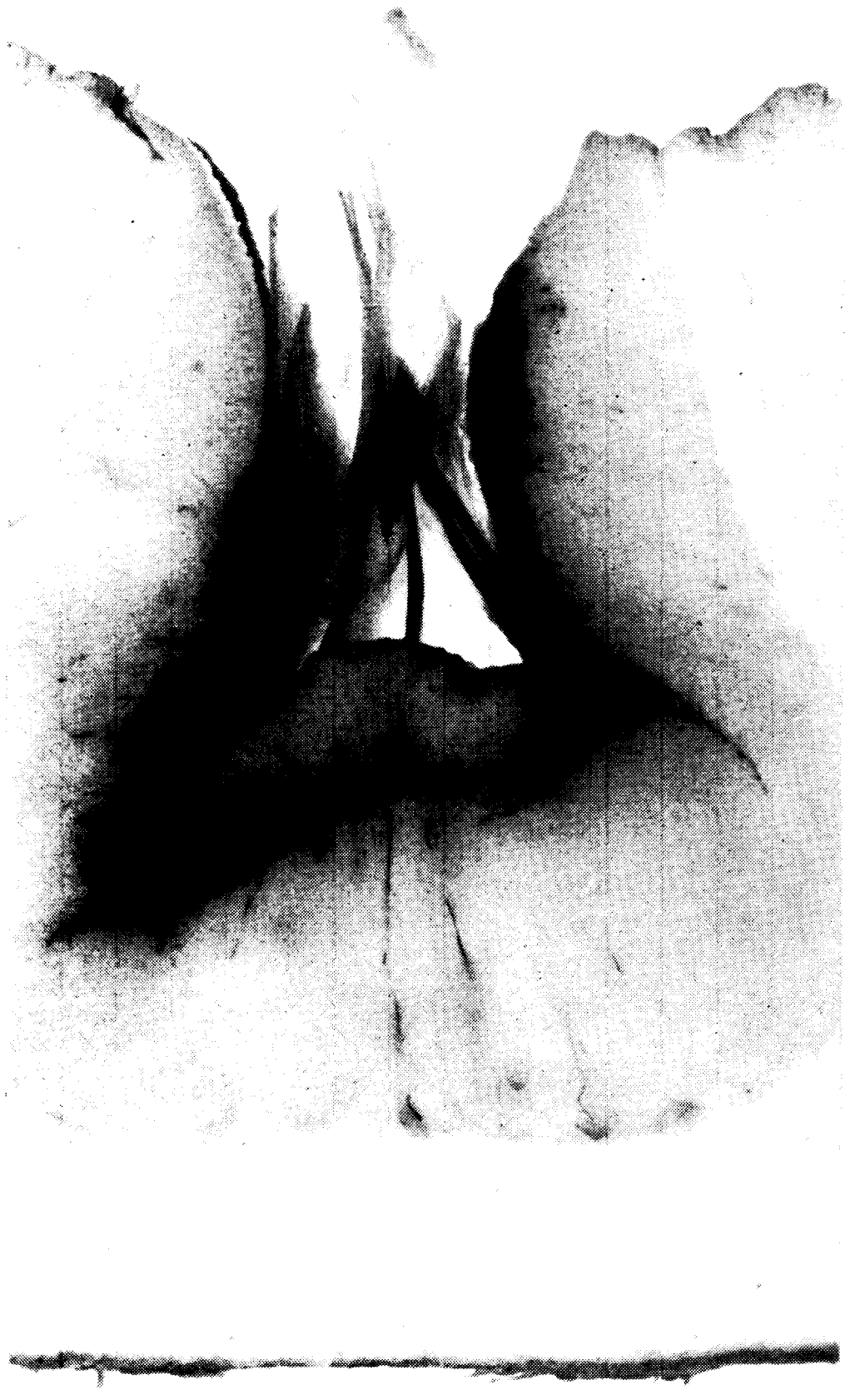
4

FIGURES 2 TO 5

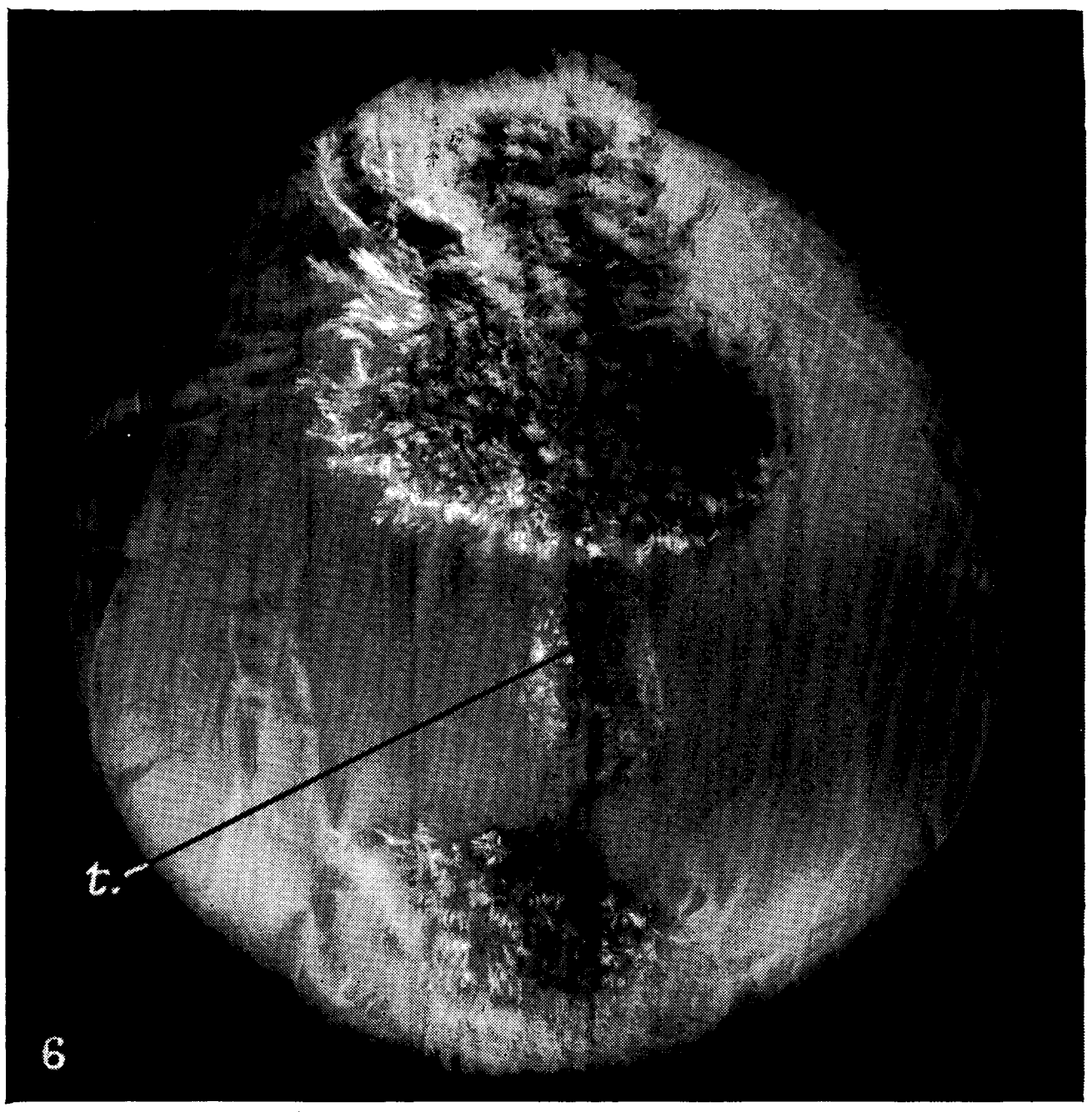

6

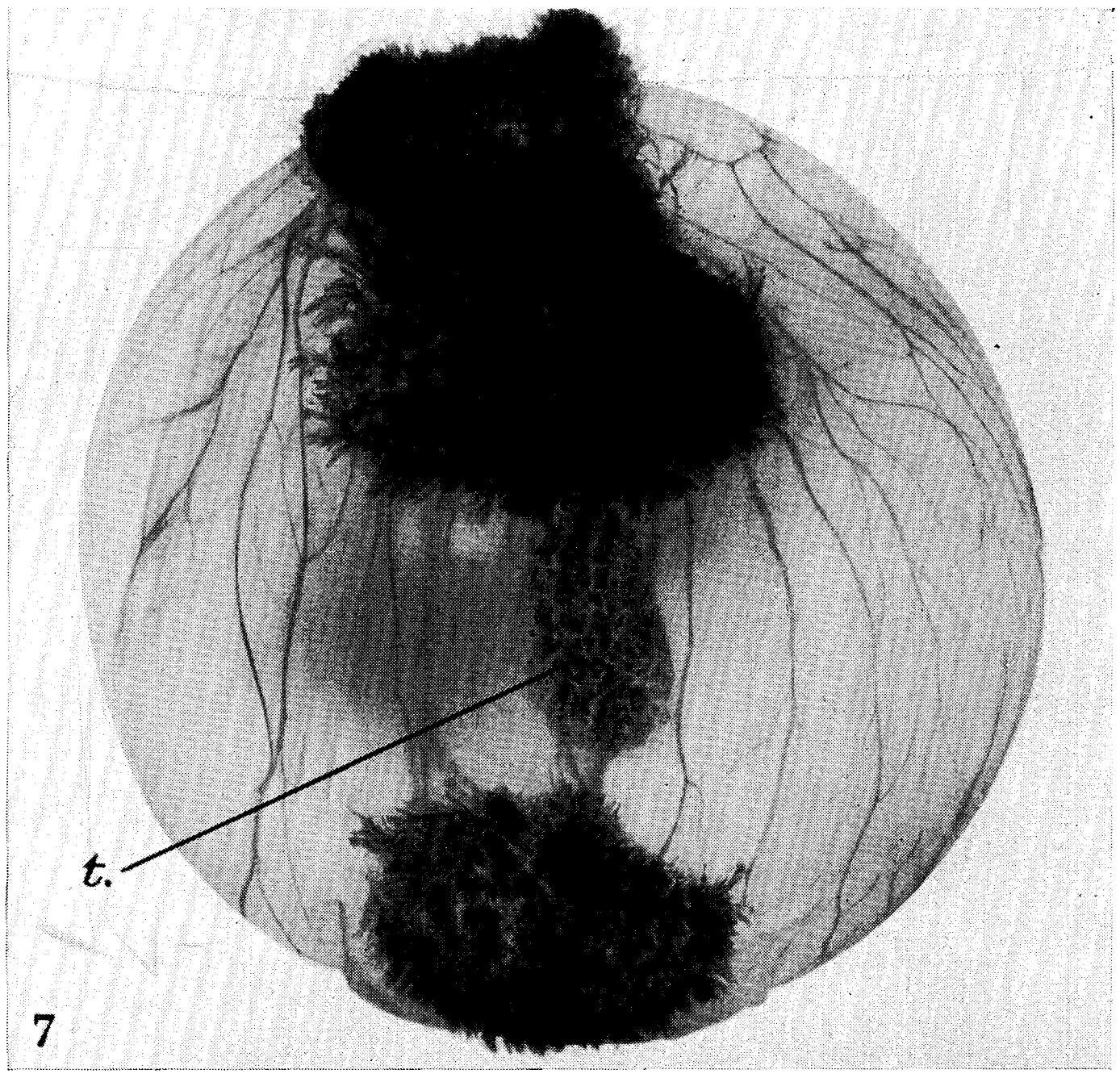

7

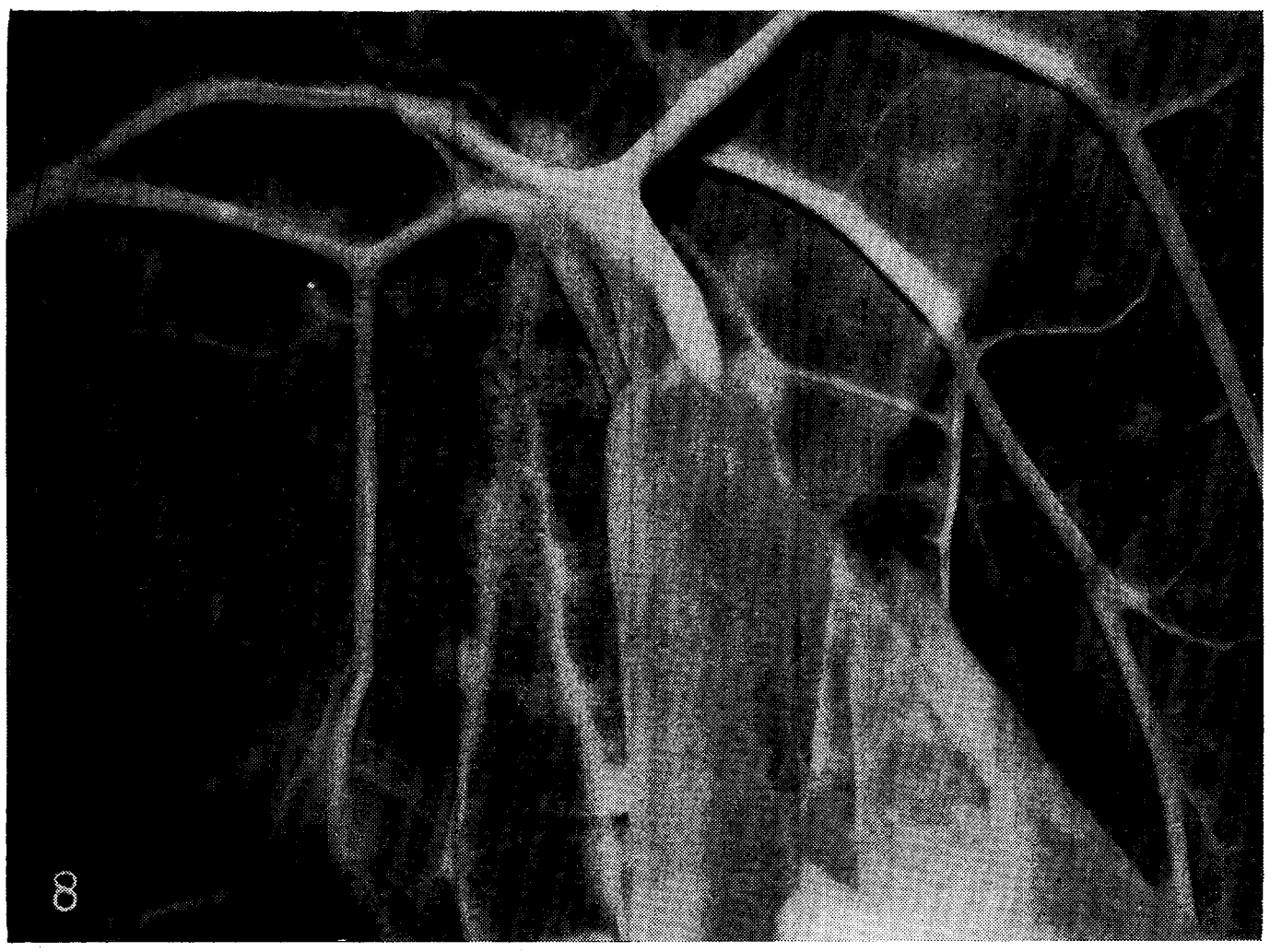

8

9

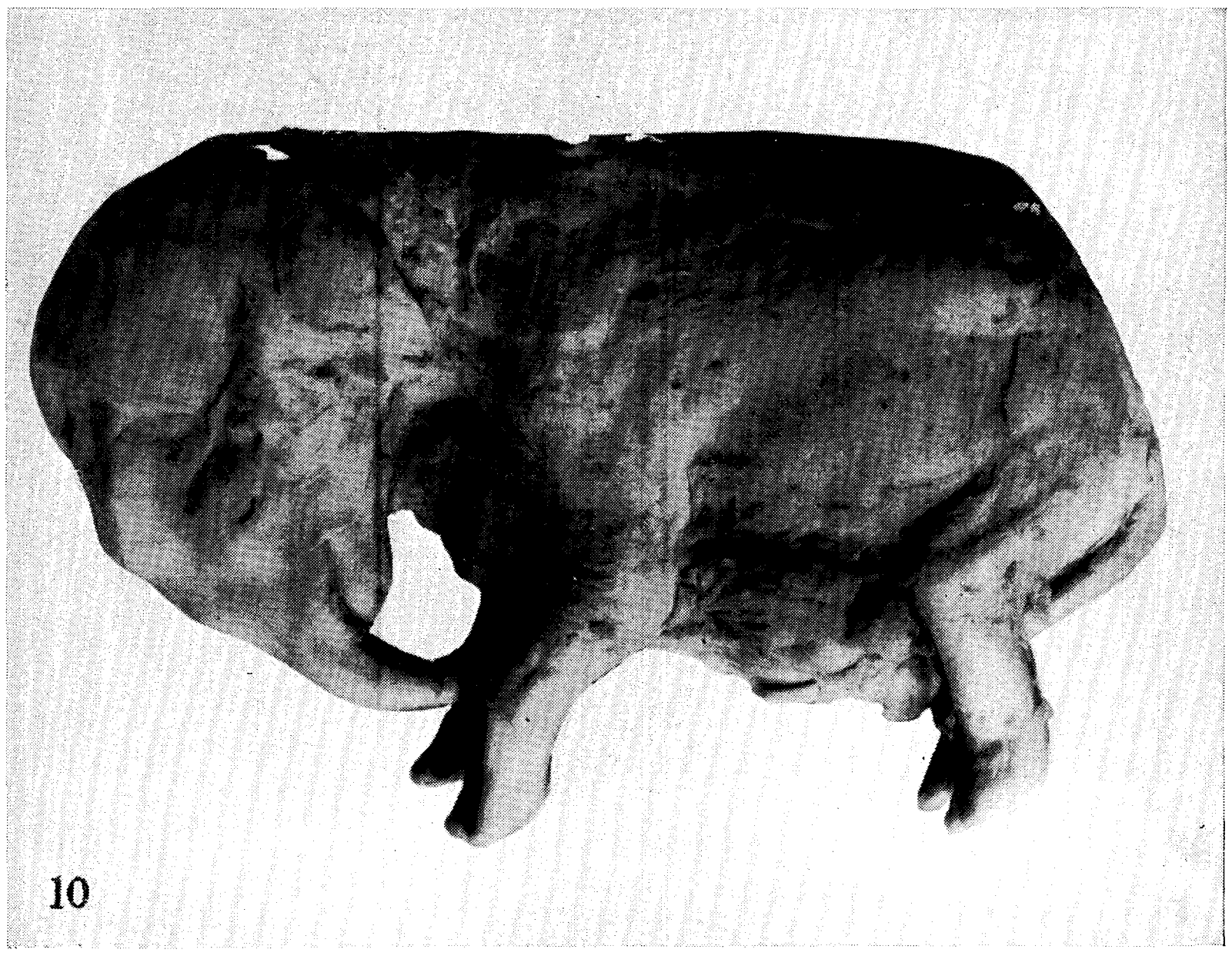

10

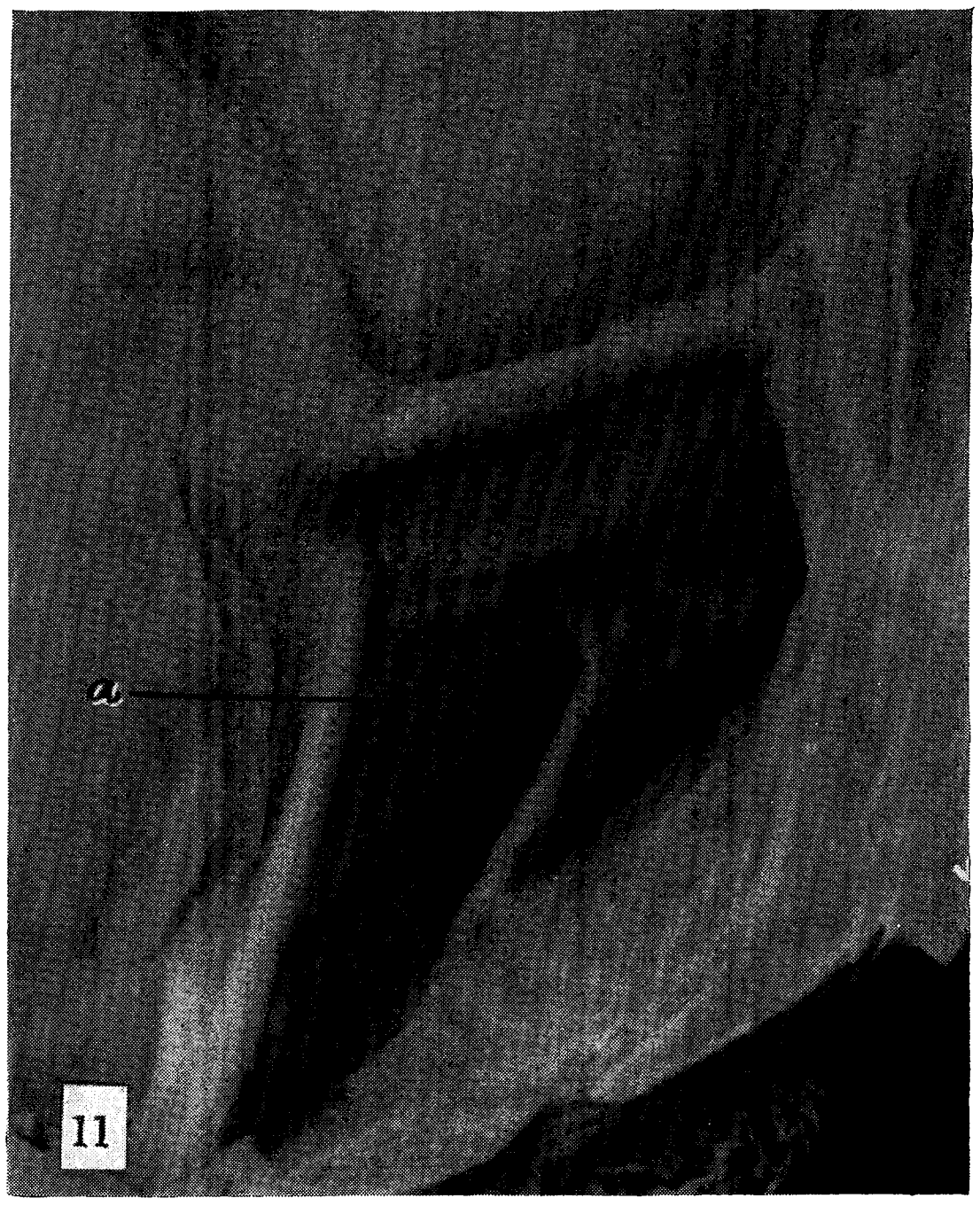

11

FIGURES 6 TO 11


12


13


14

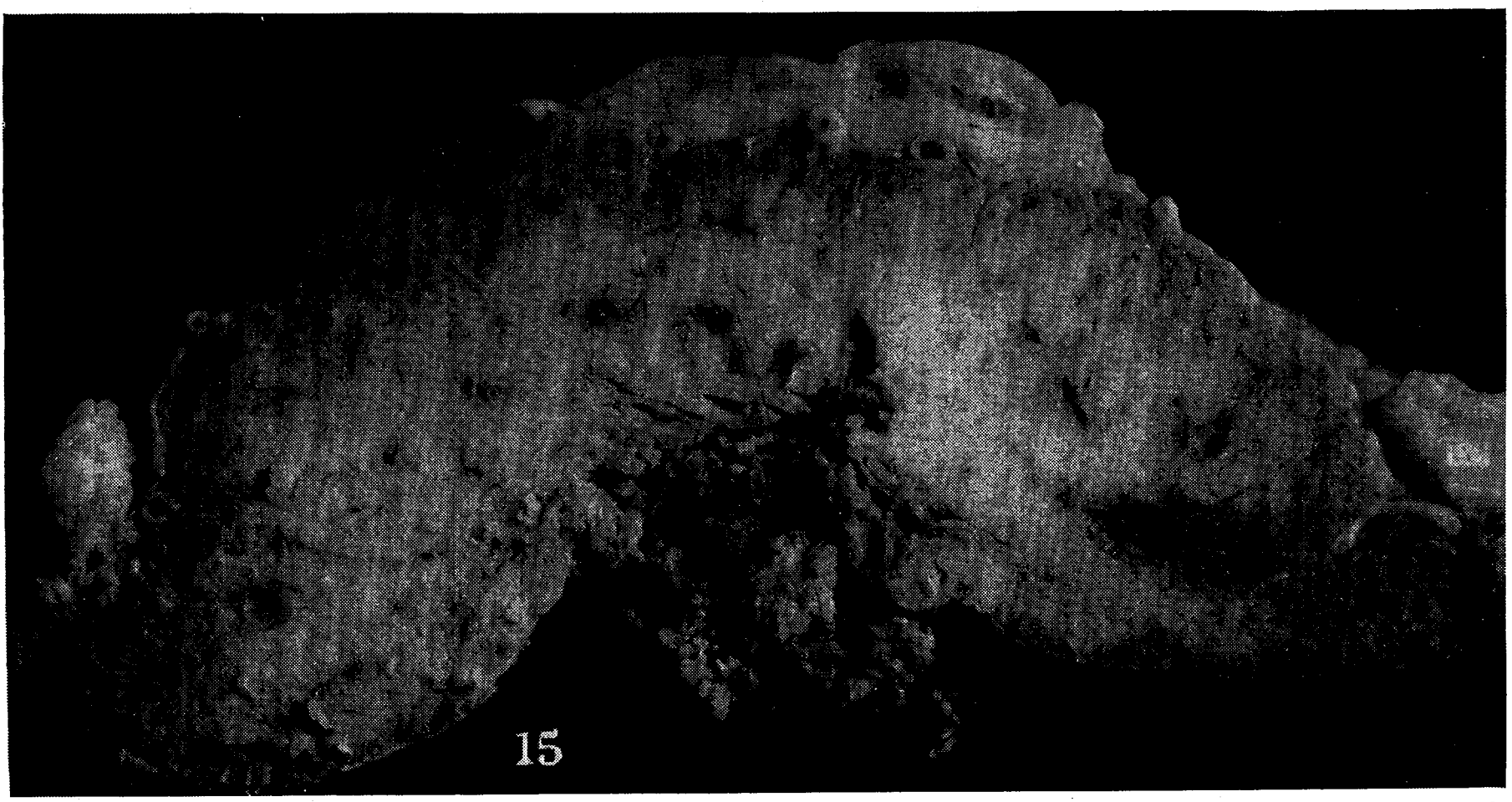
15

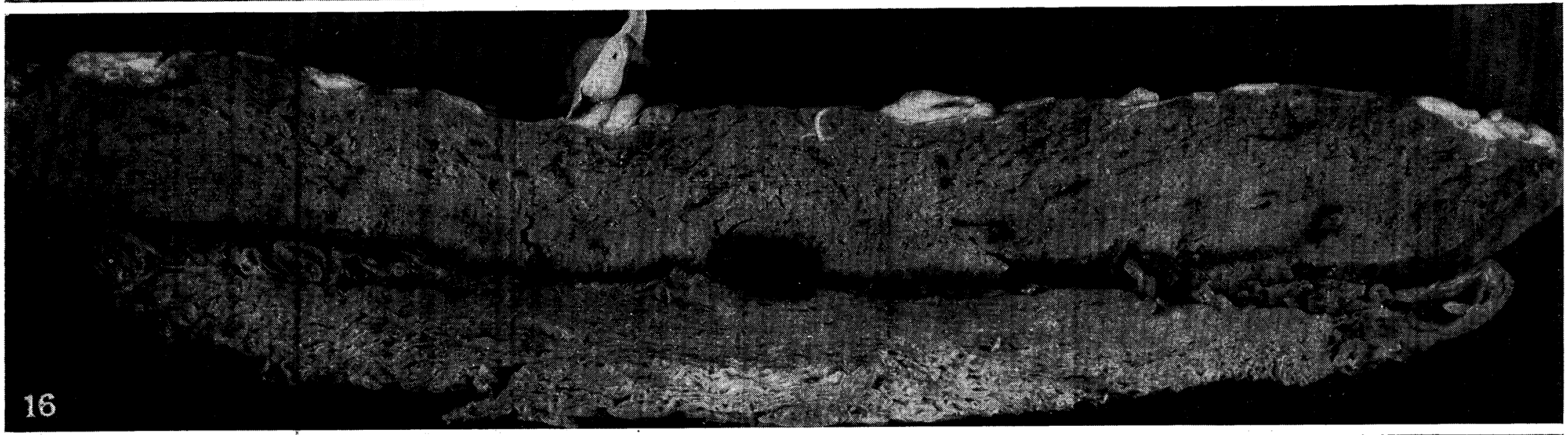
16


17

FIGURES 12 TO 17


18

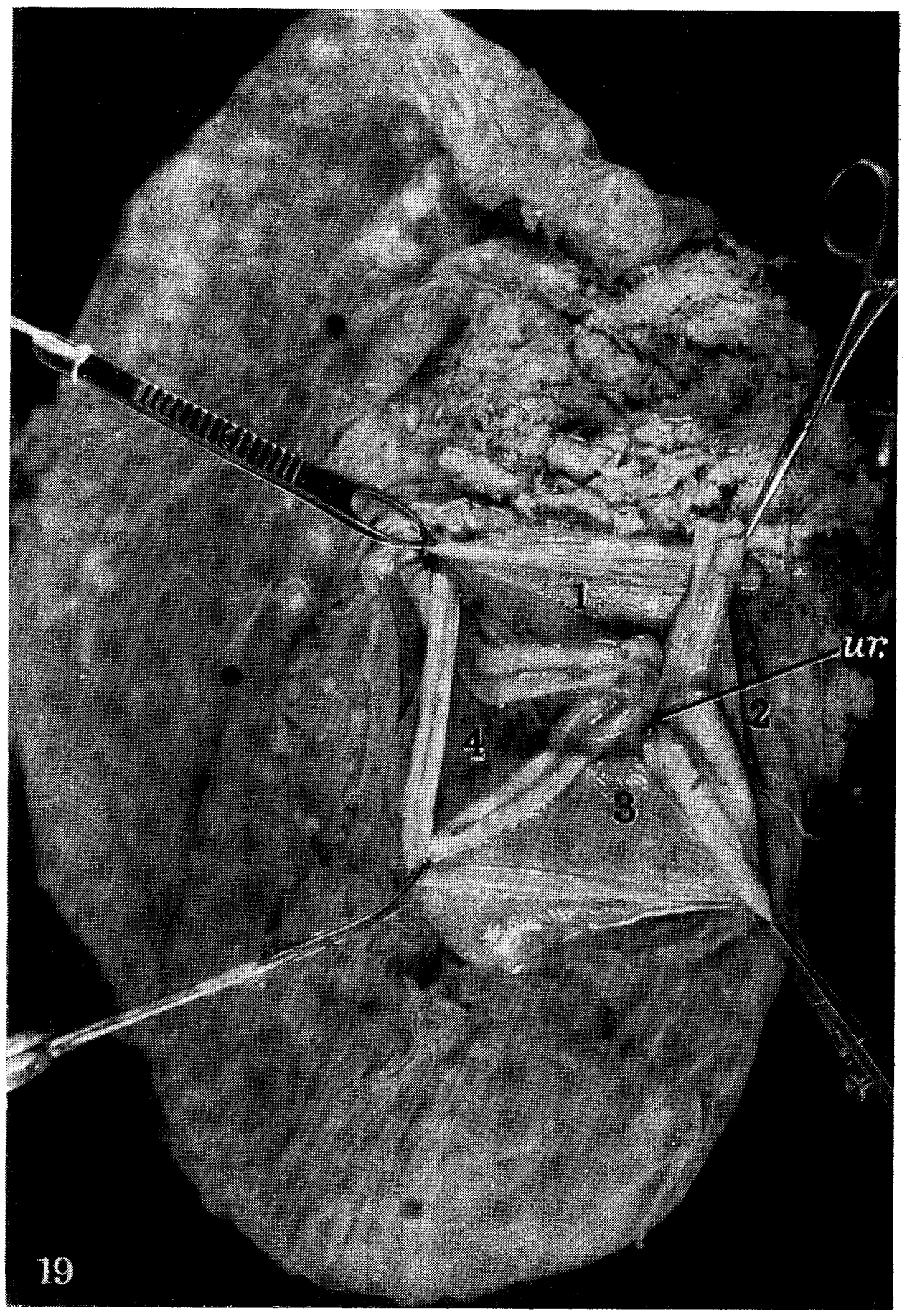
19

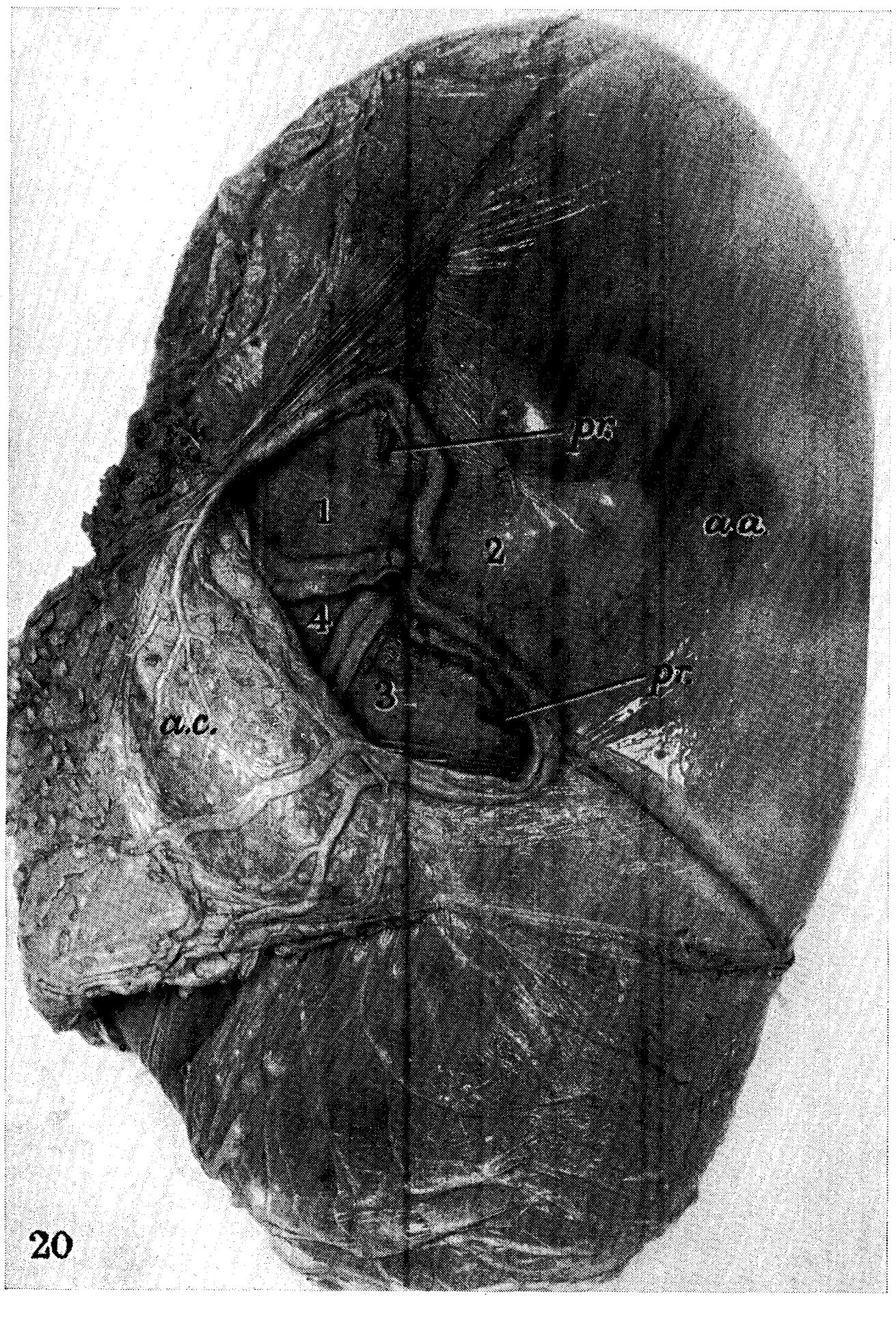
20


21

FIGURES 18 TO 21

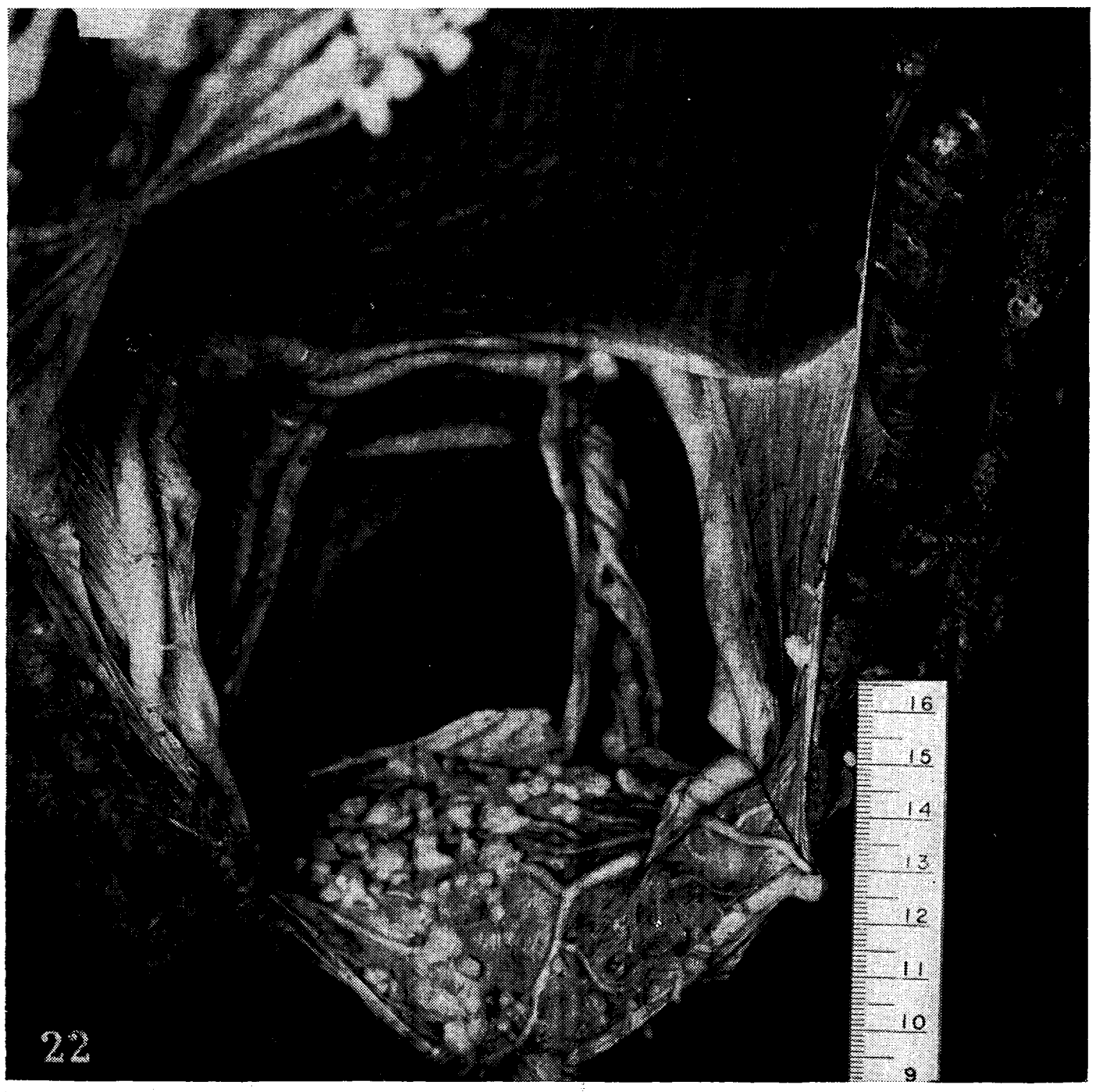

22

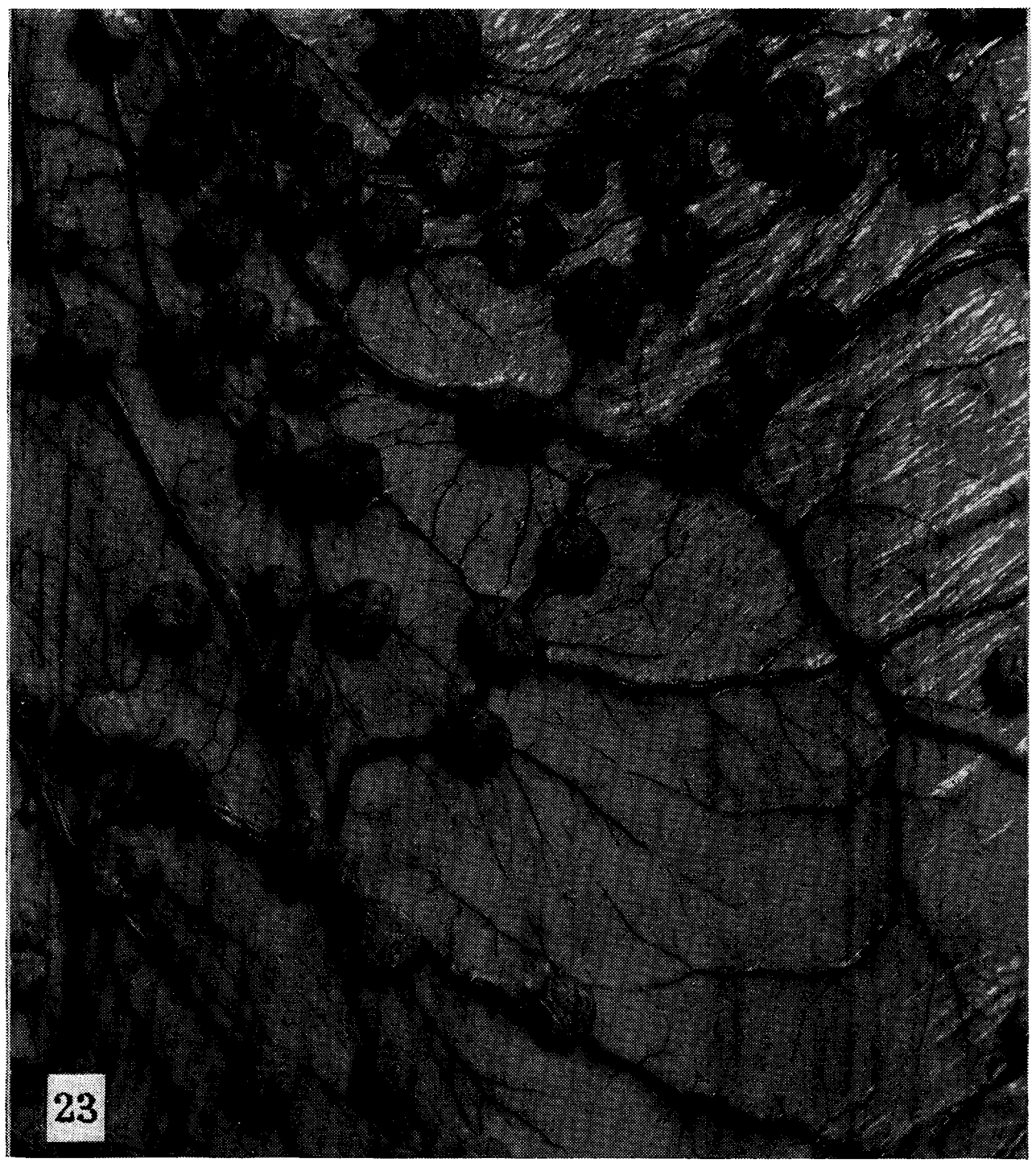

23

24

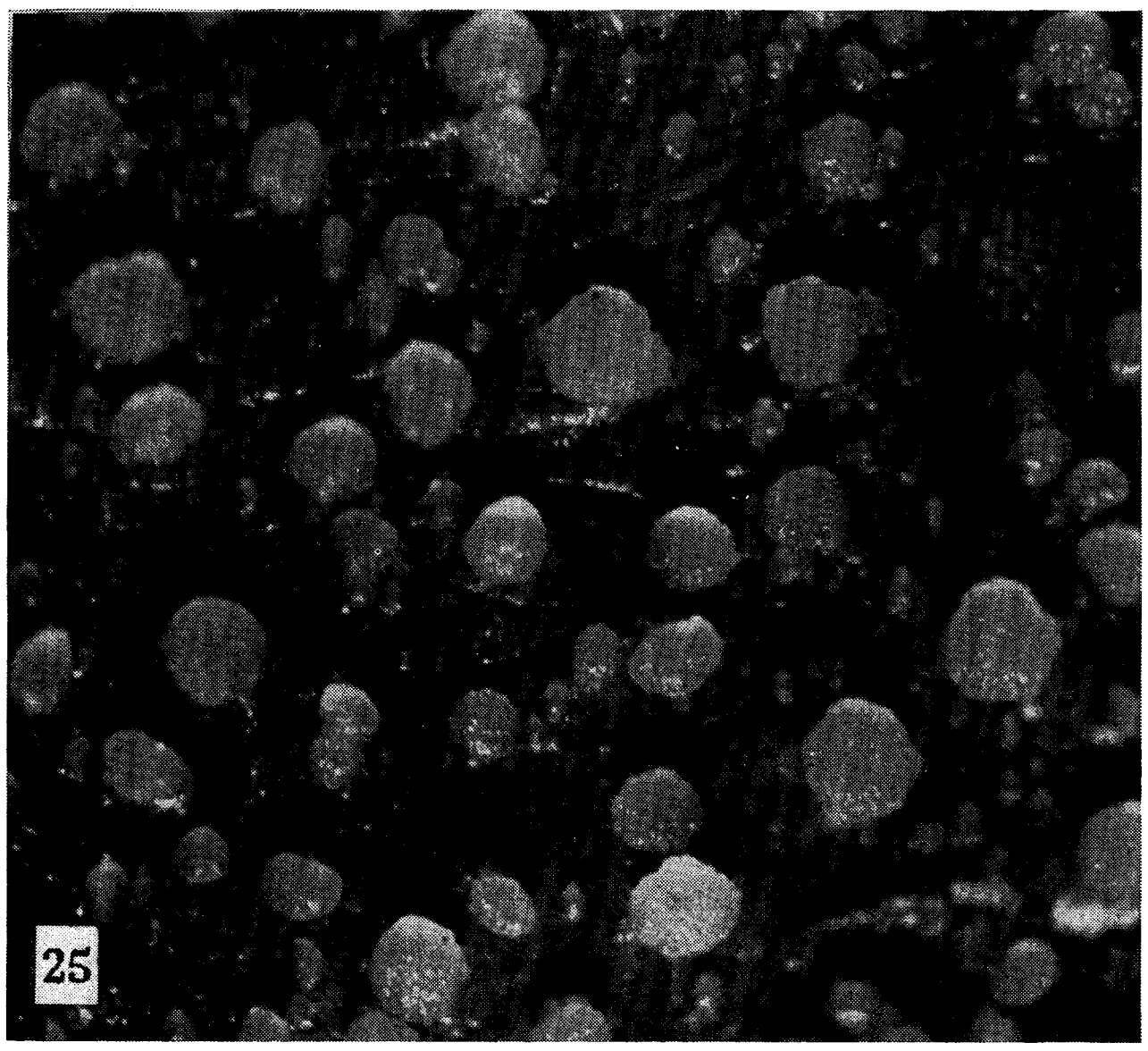

25

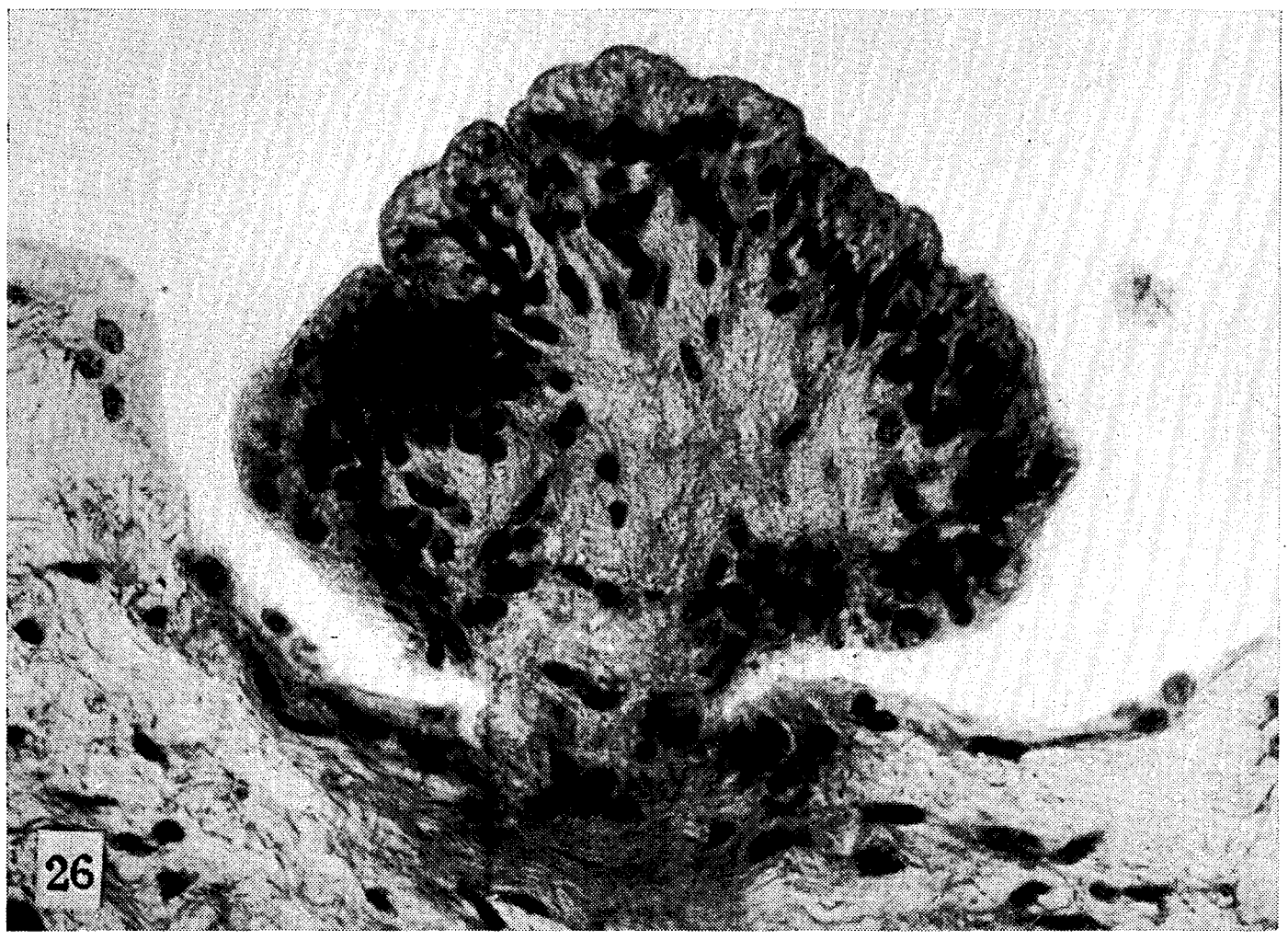

26



27

FIGURES 22 TO 27

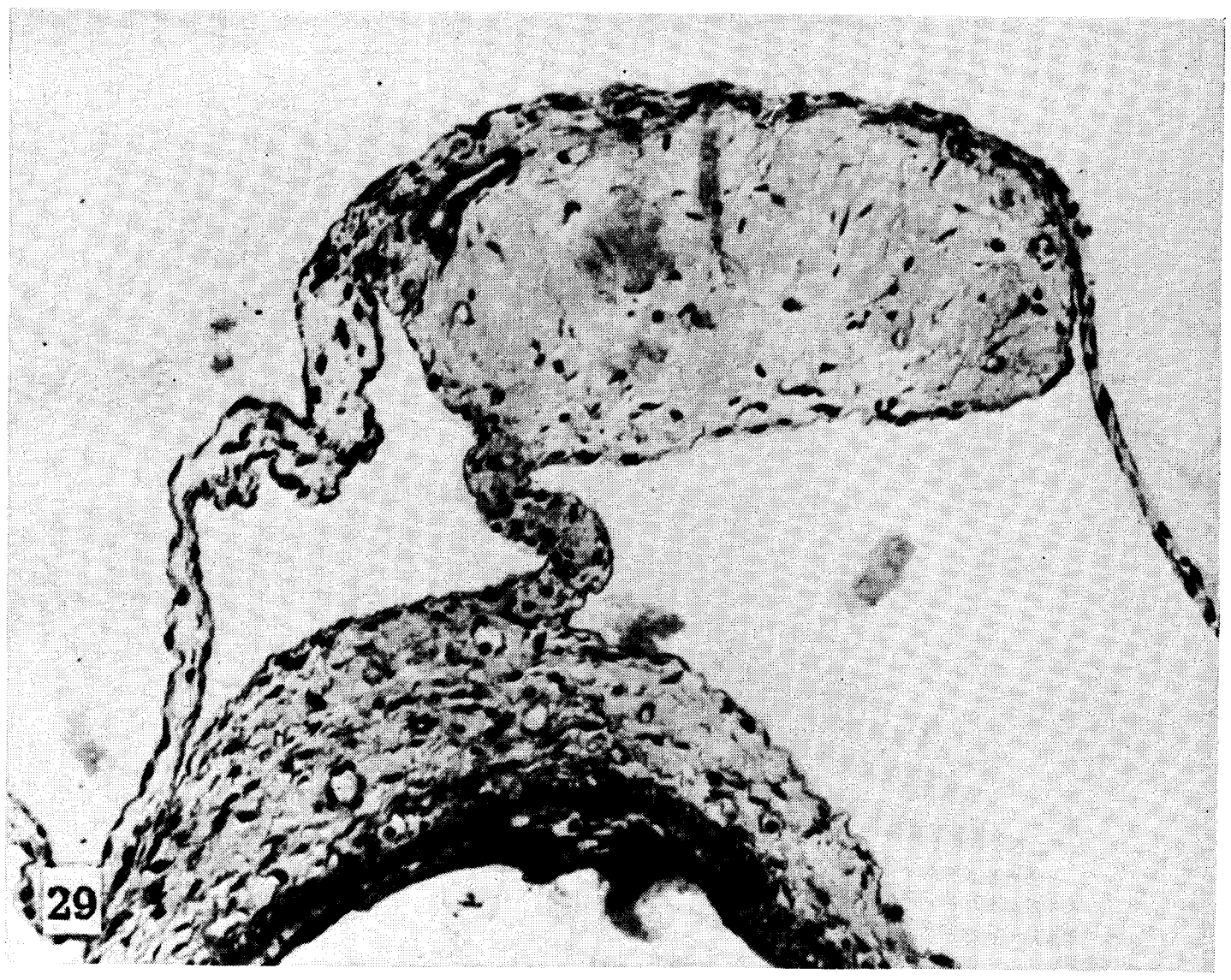

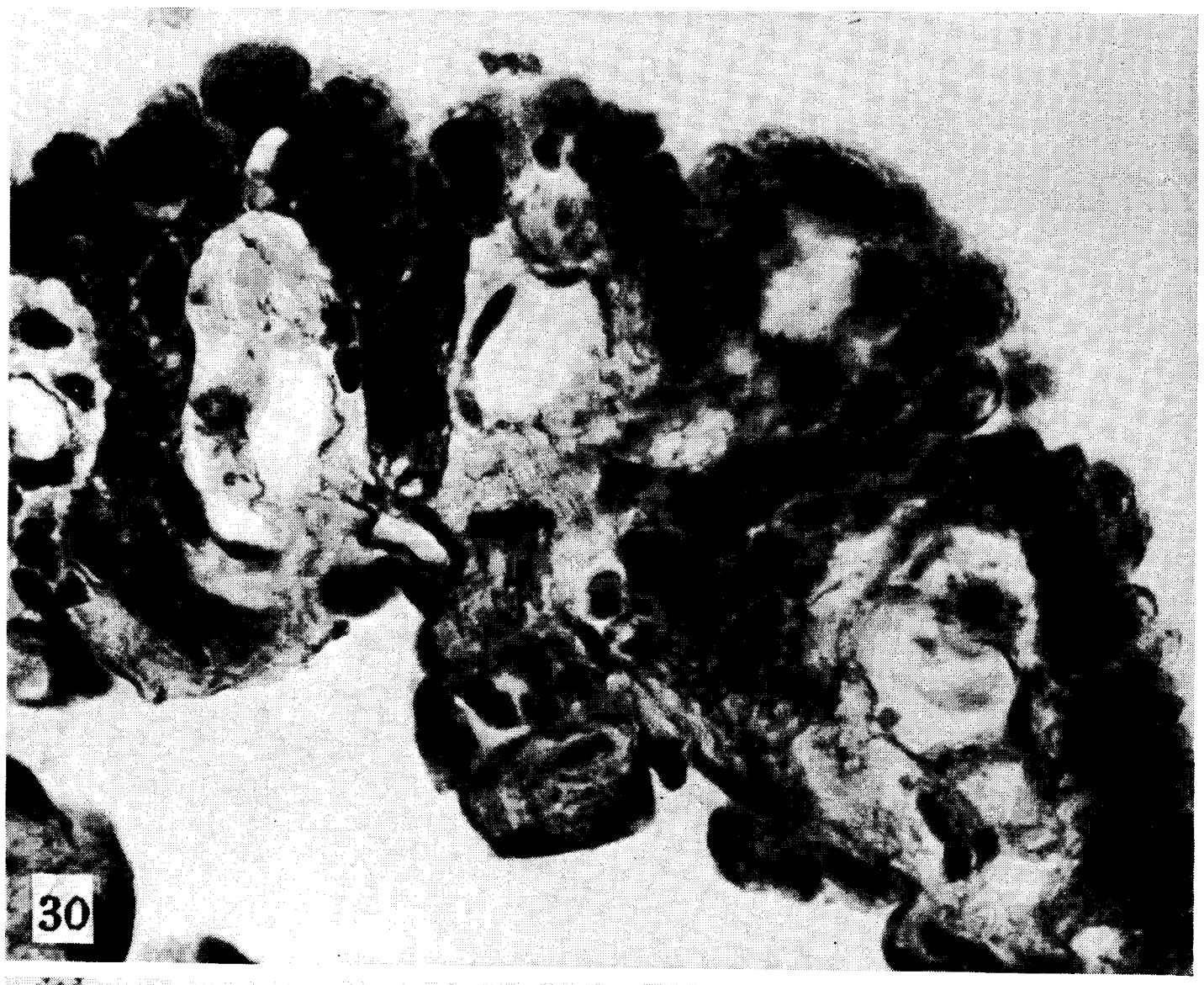

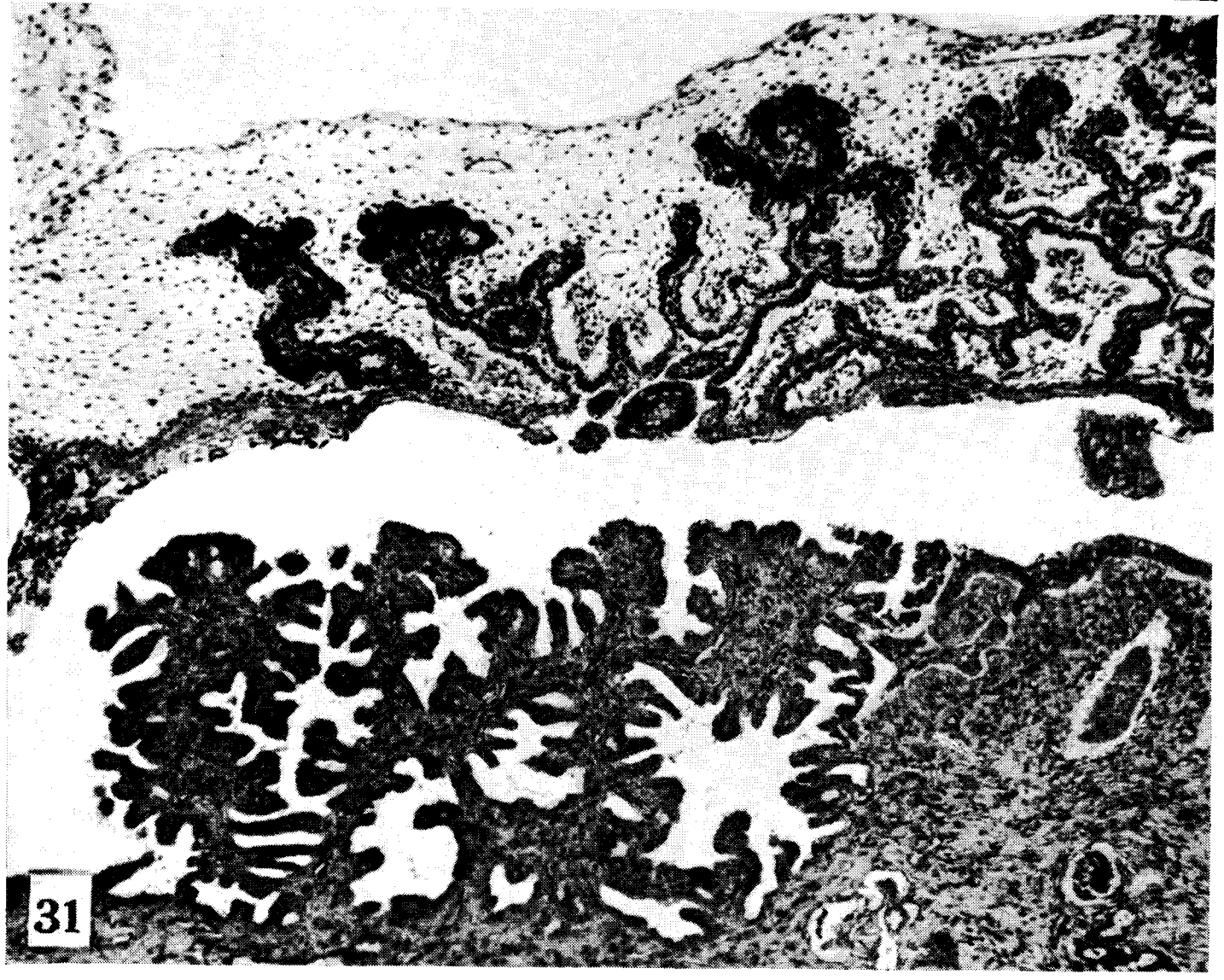

FIGURES 28 TO 31

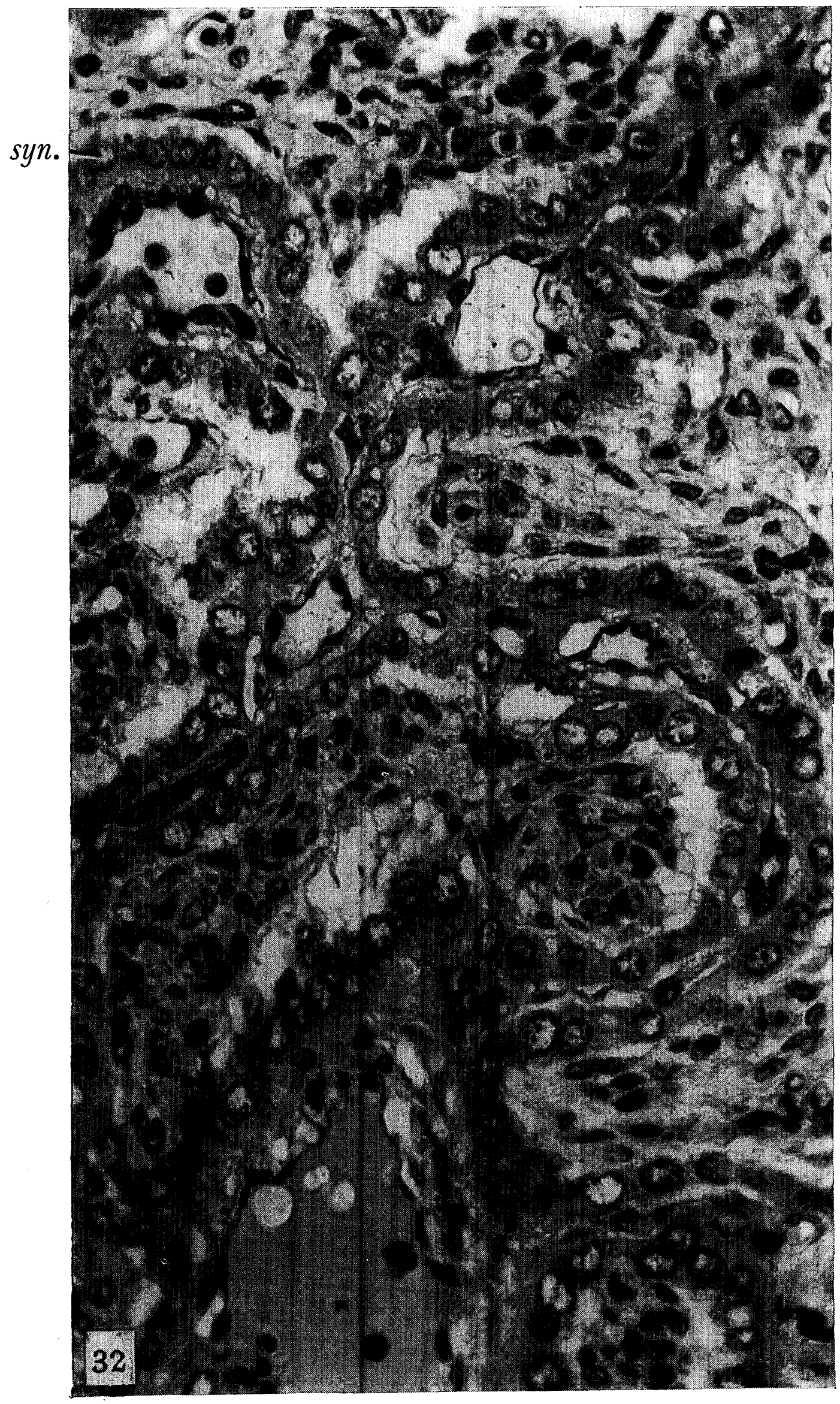
32

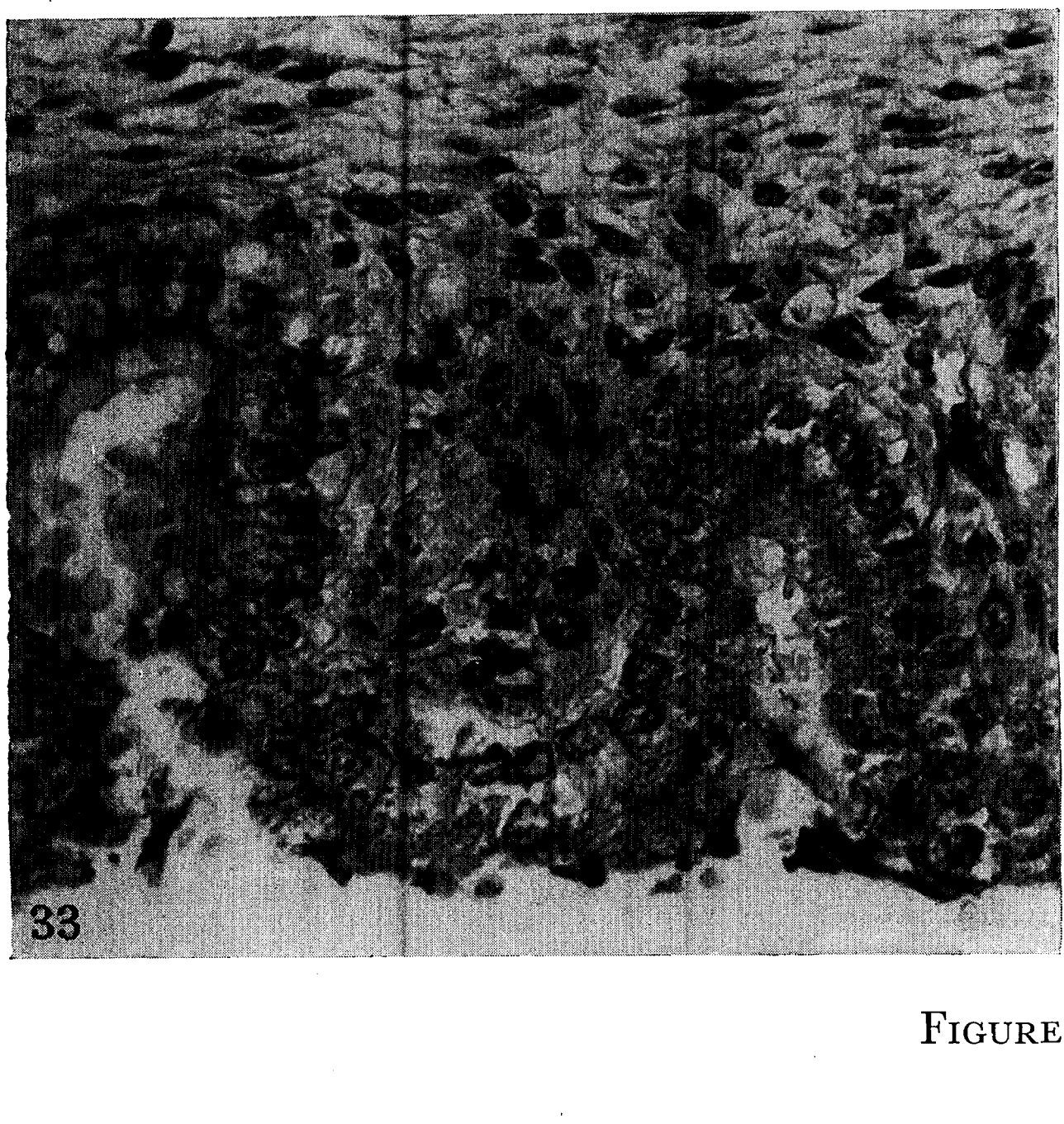
33

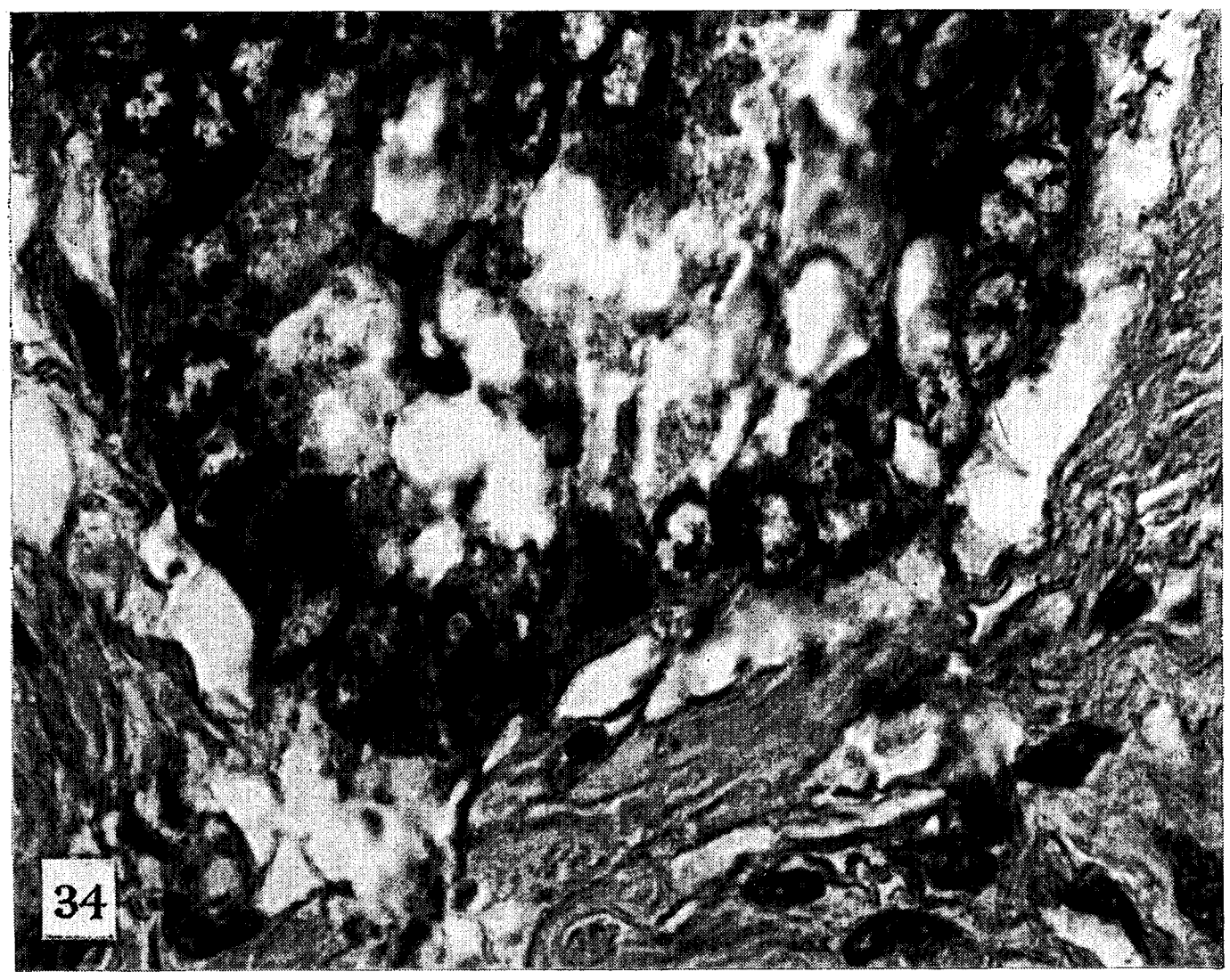
34

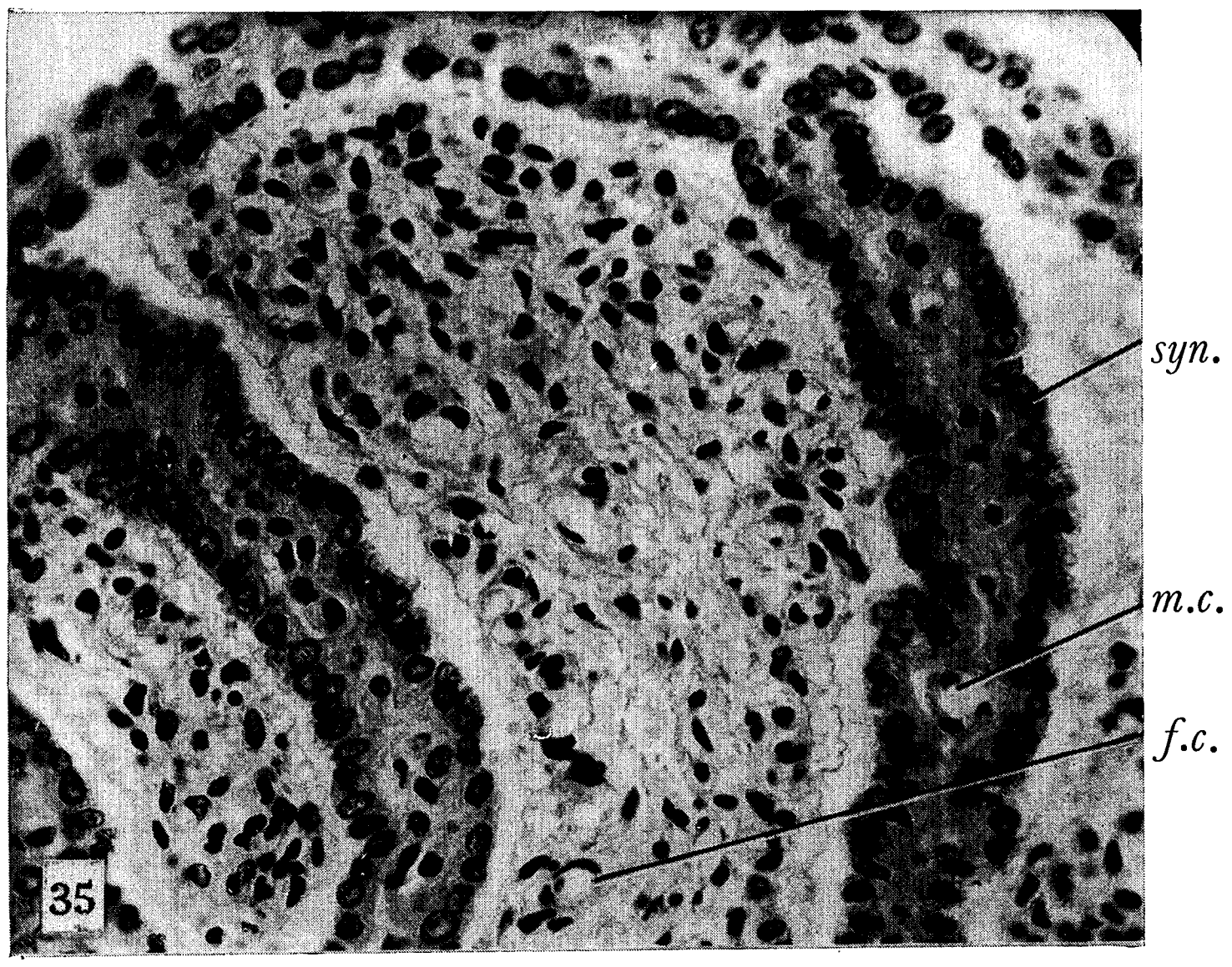
35

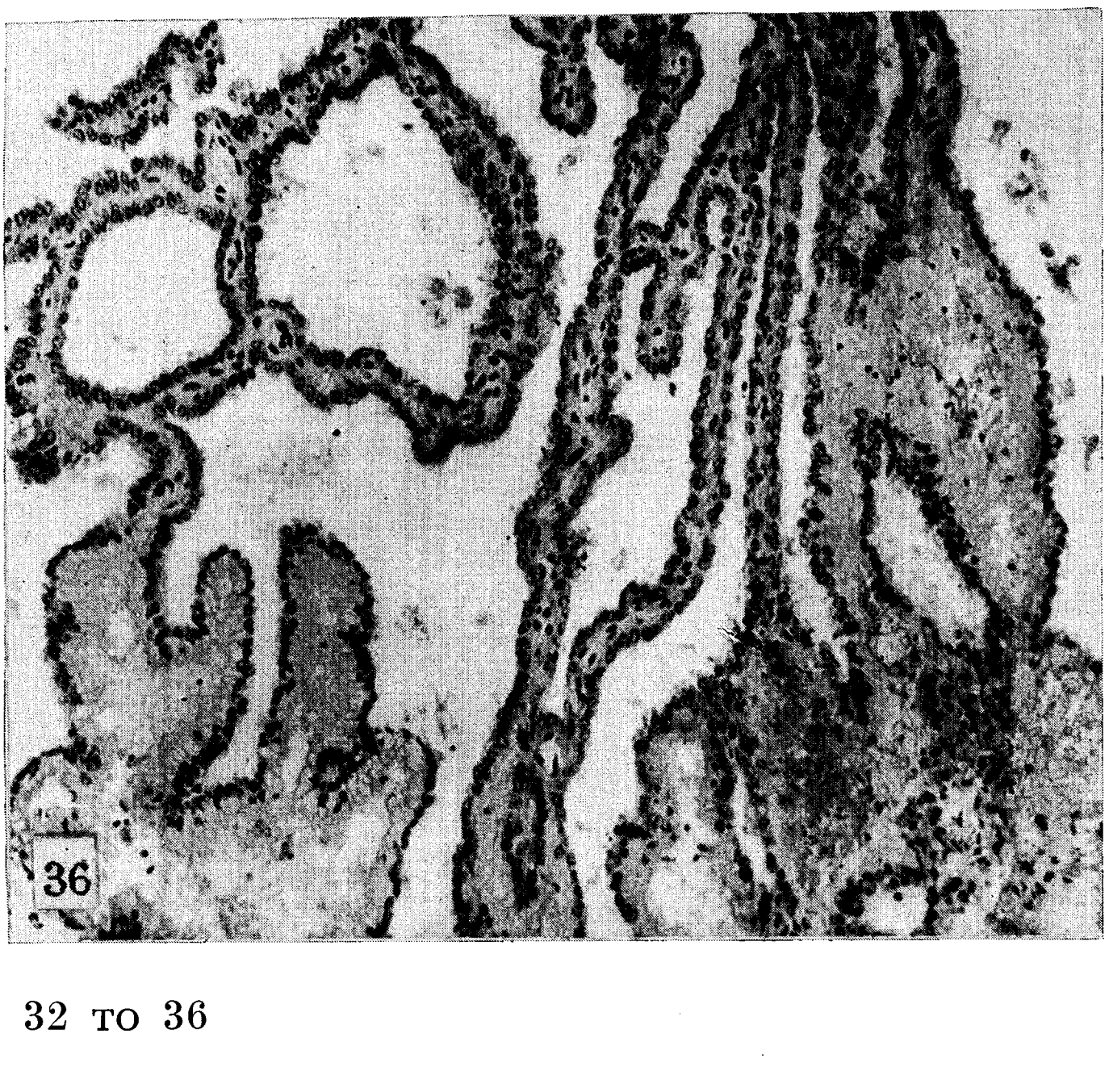
36

FIGURES 32 TO 36

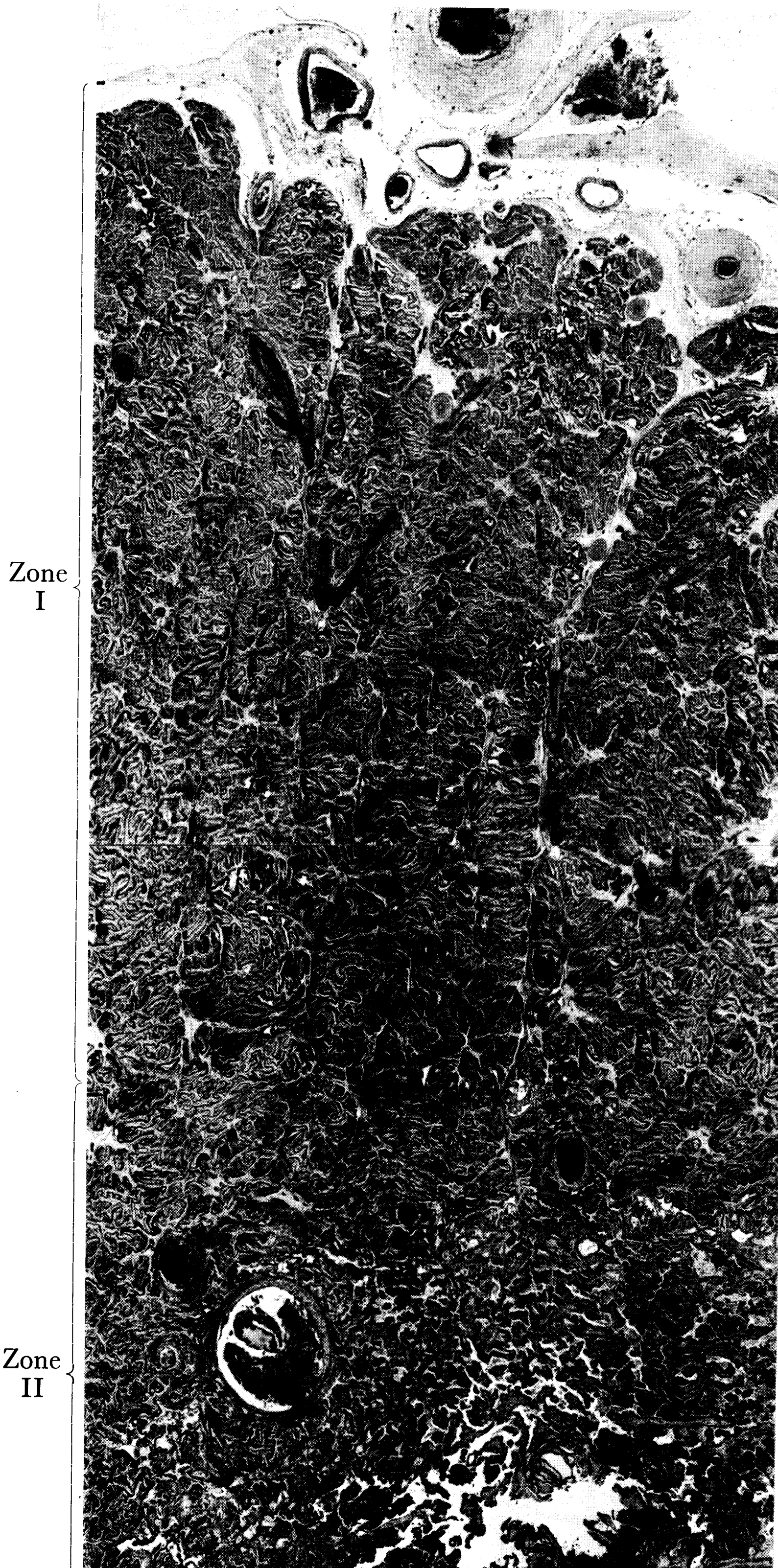

37

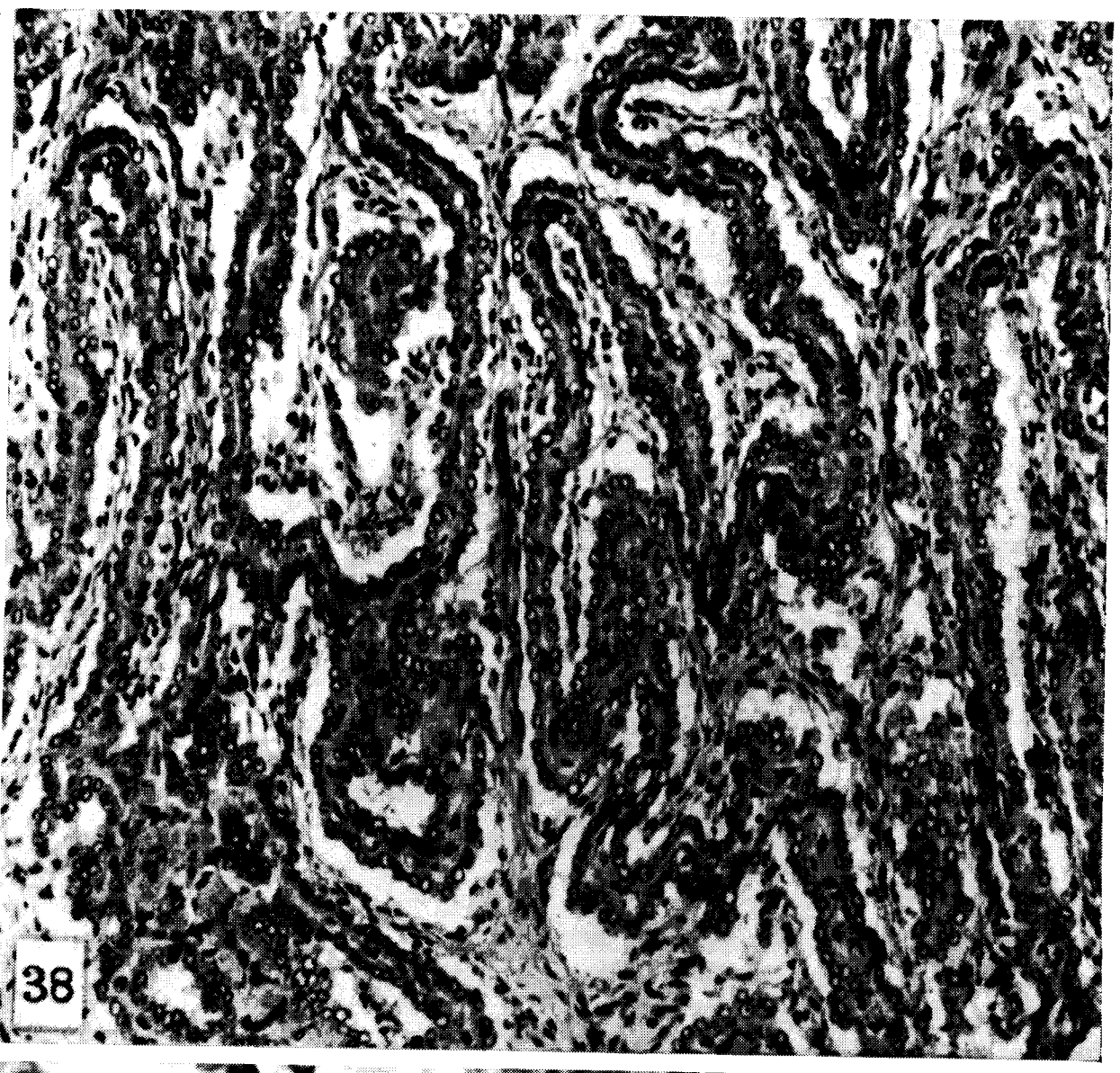

38

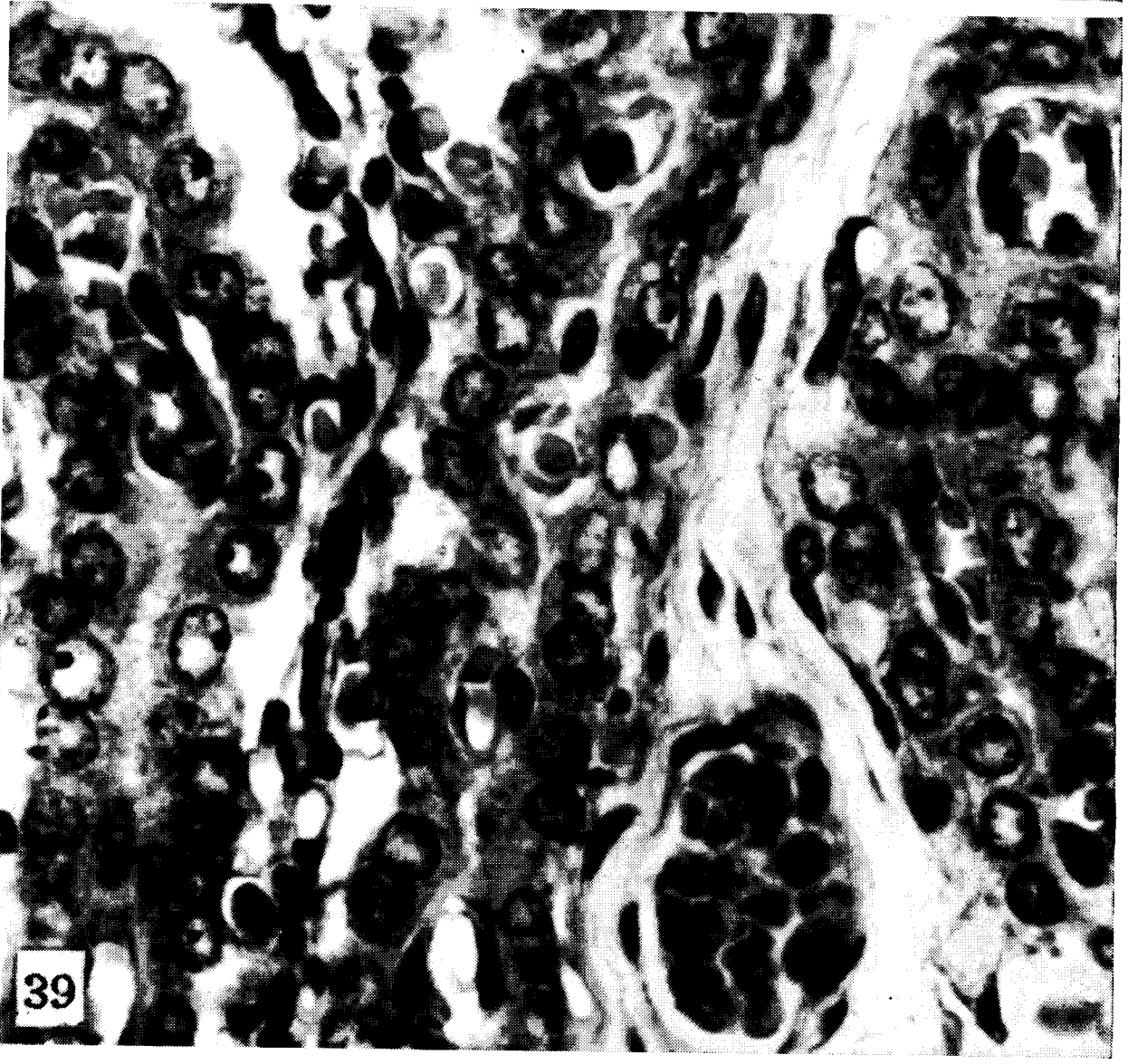

39

40

FIGURES 37 TO 40


41

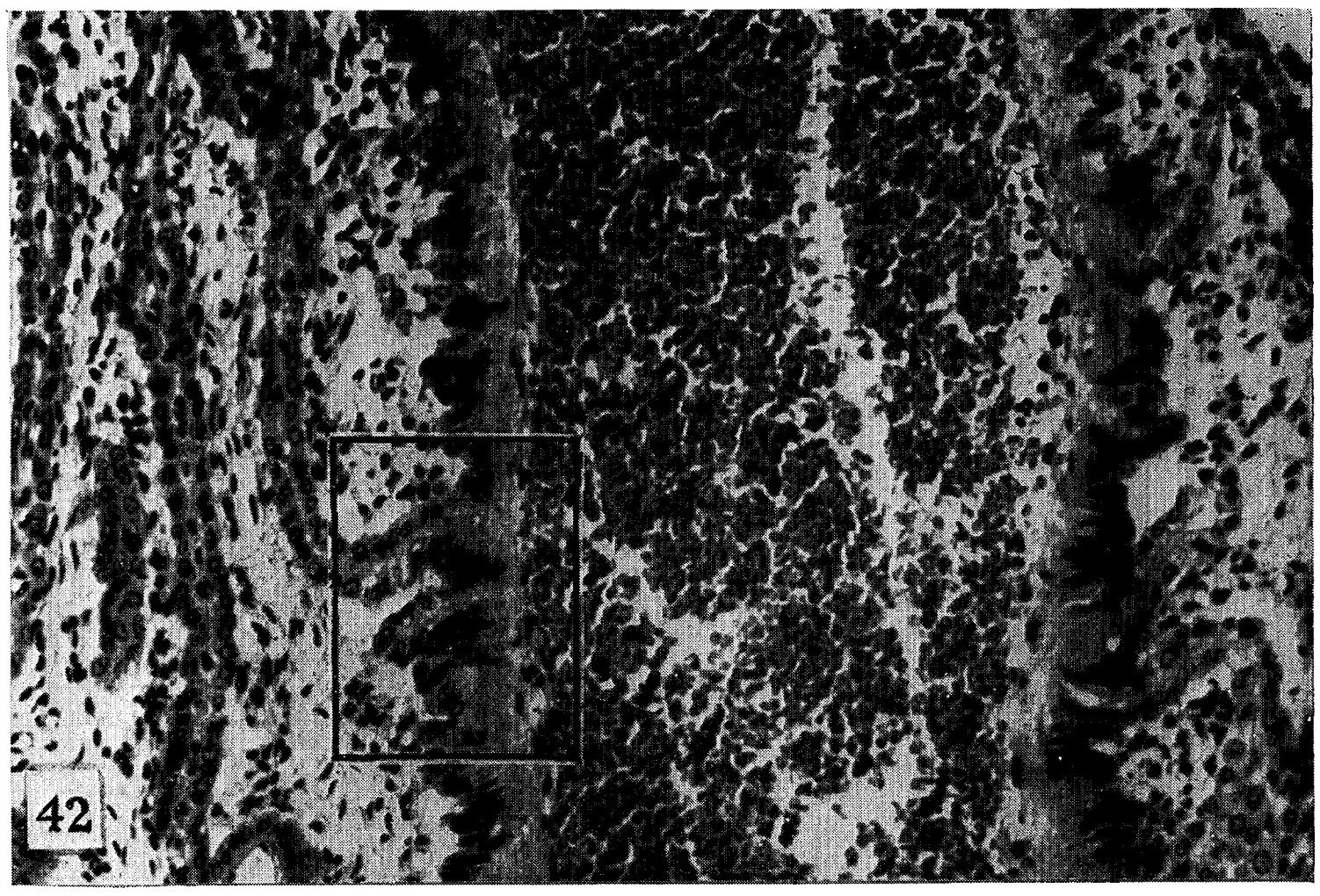
42

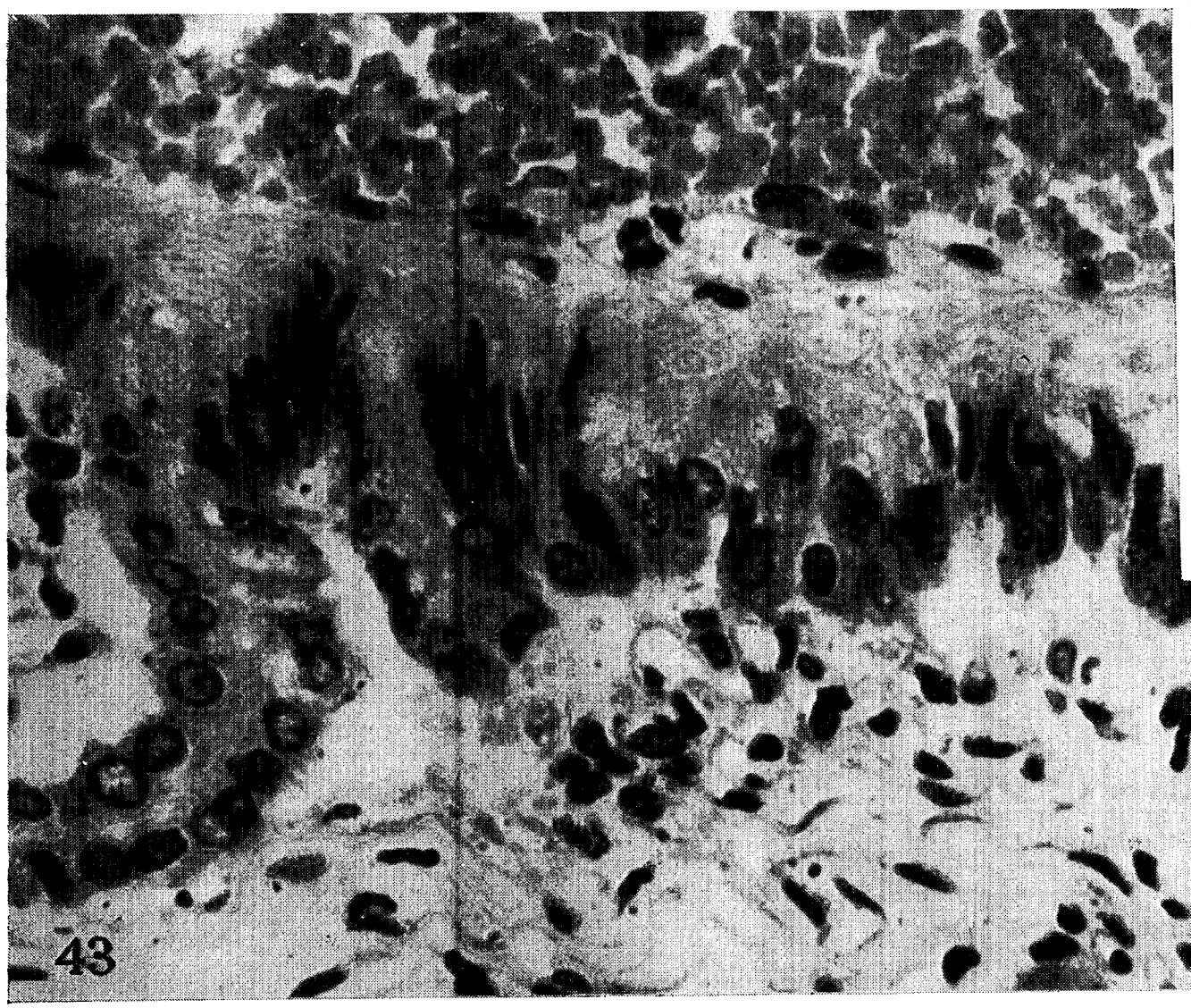
43

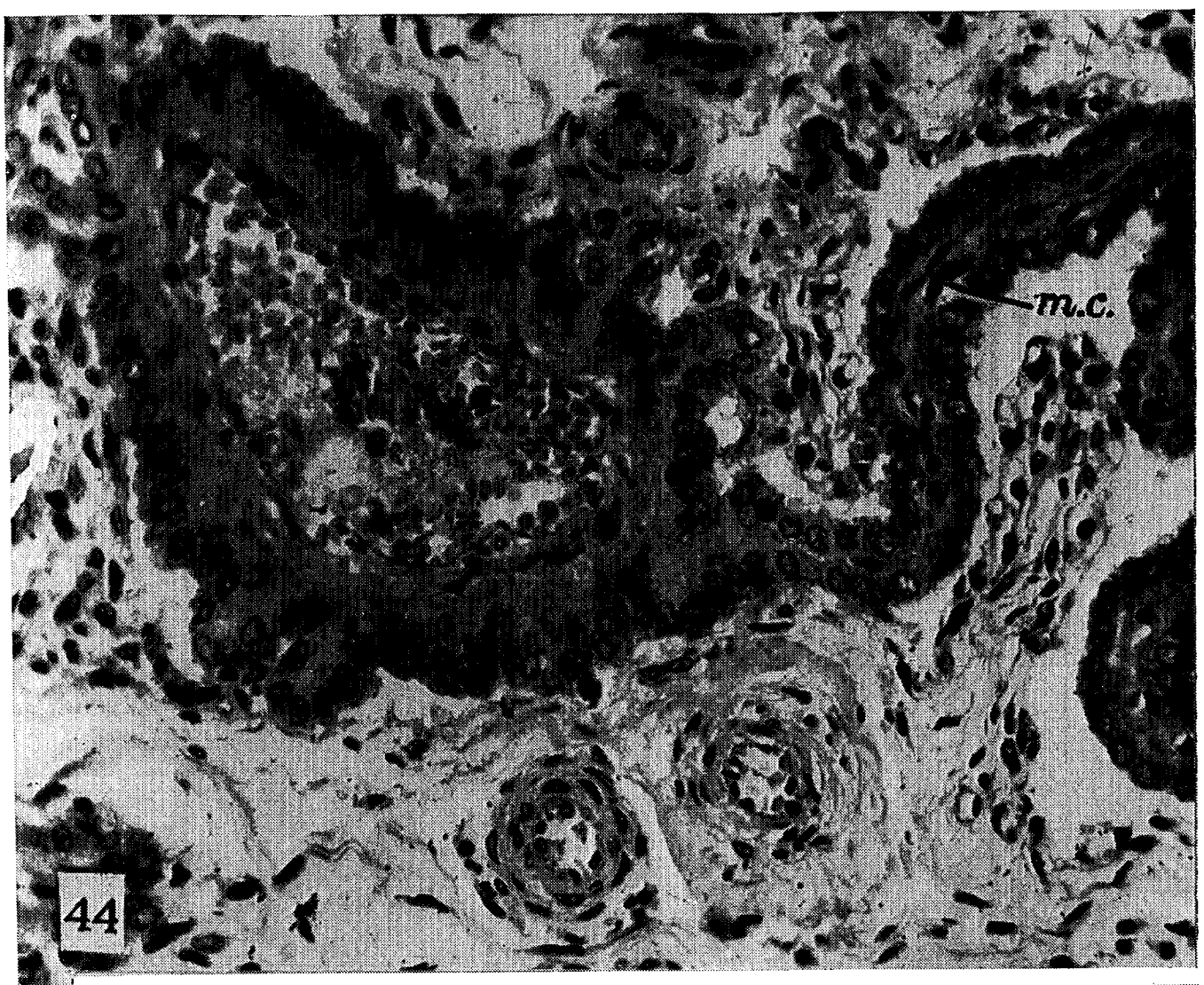
44


45

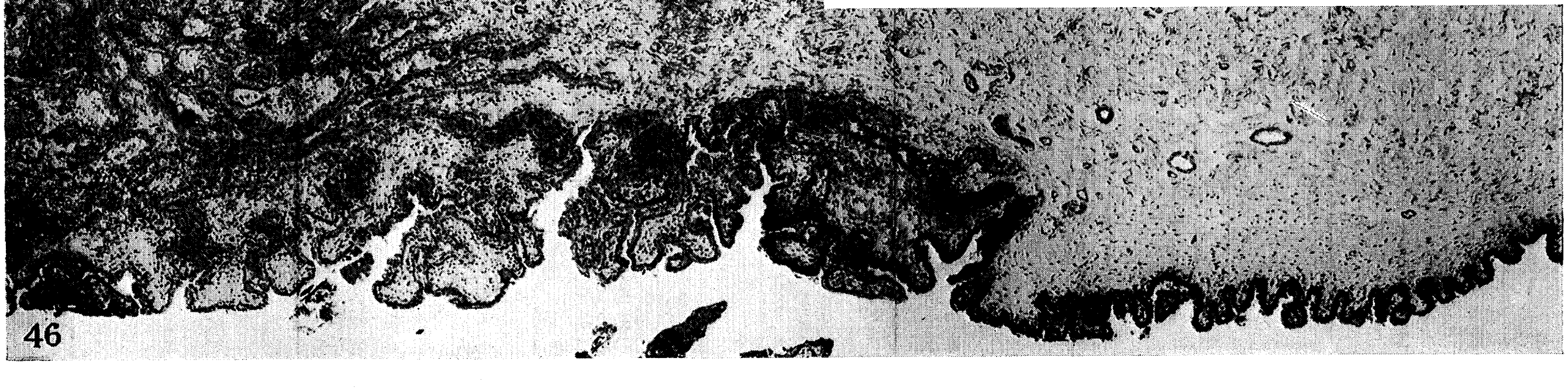
46

FIGURES 41 TO 46

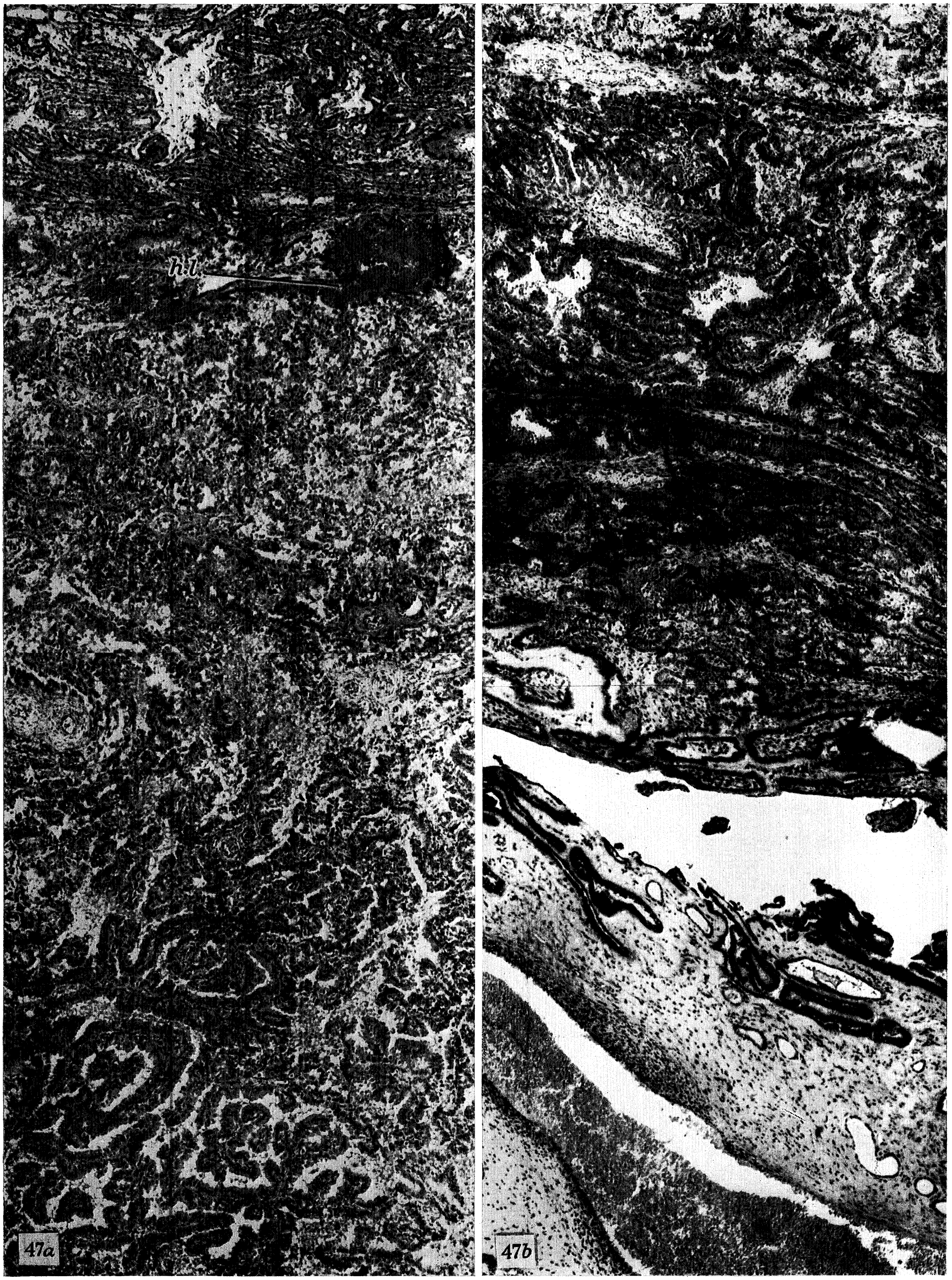

FIGURE 47

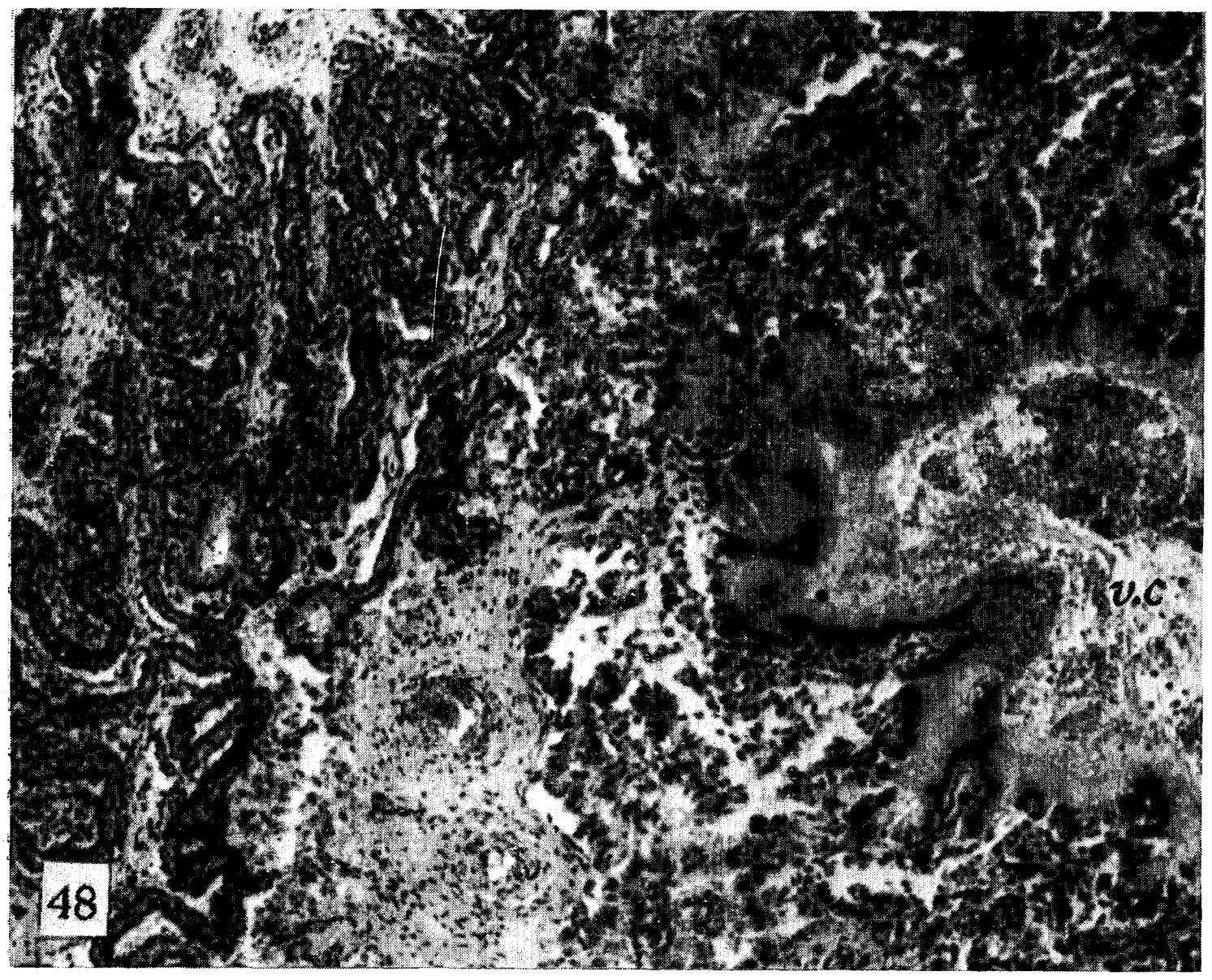
48


49

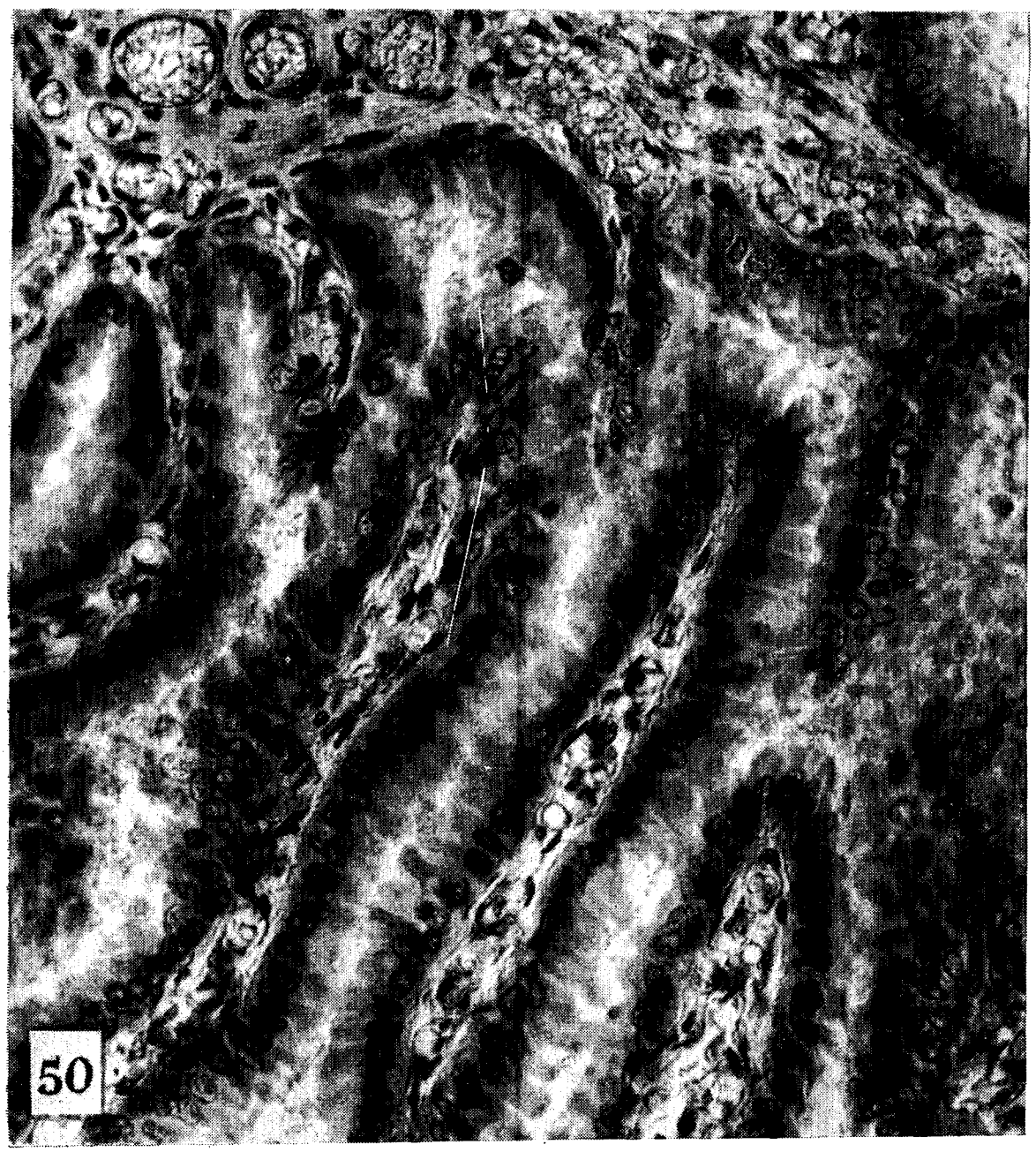
50

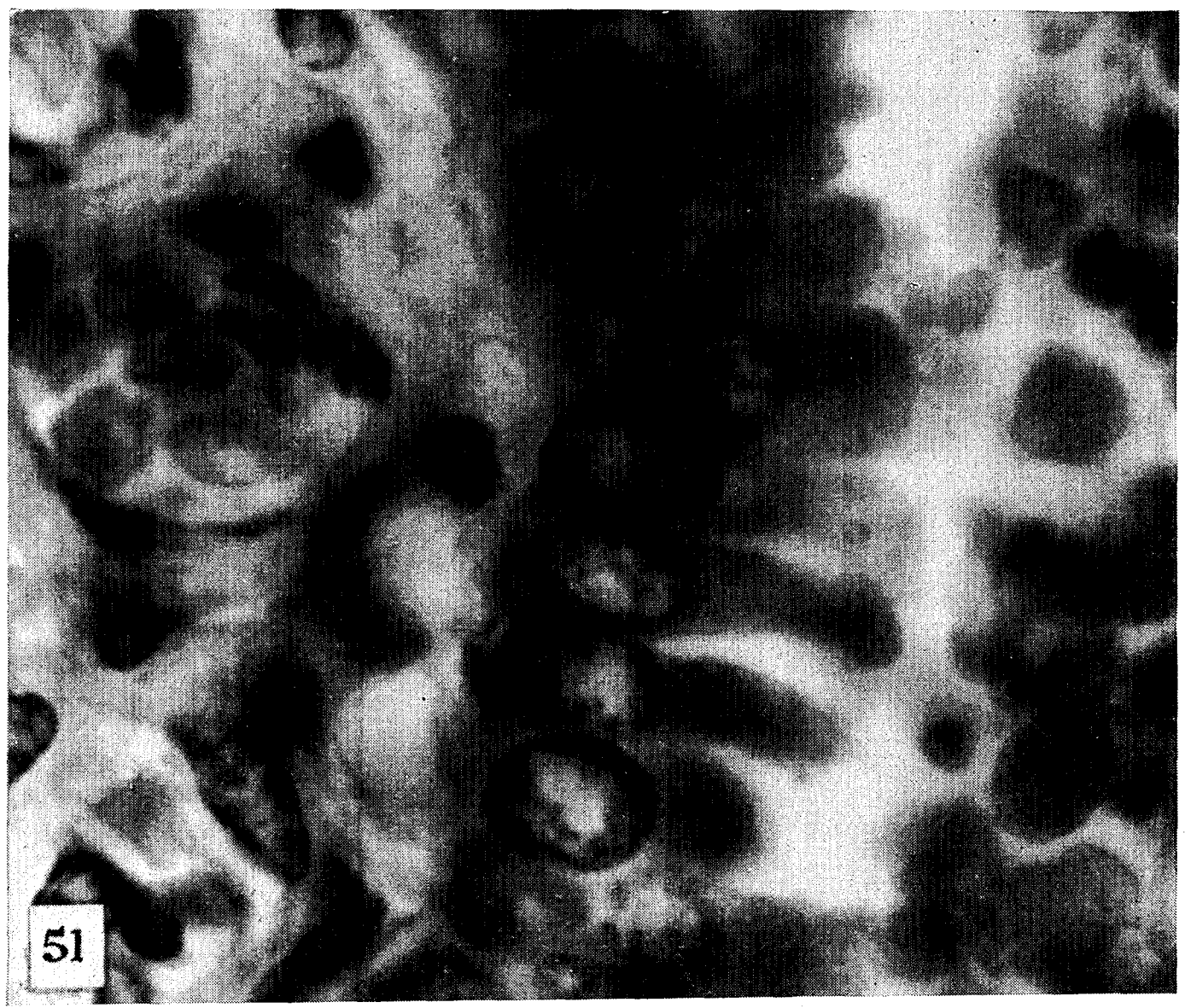
51

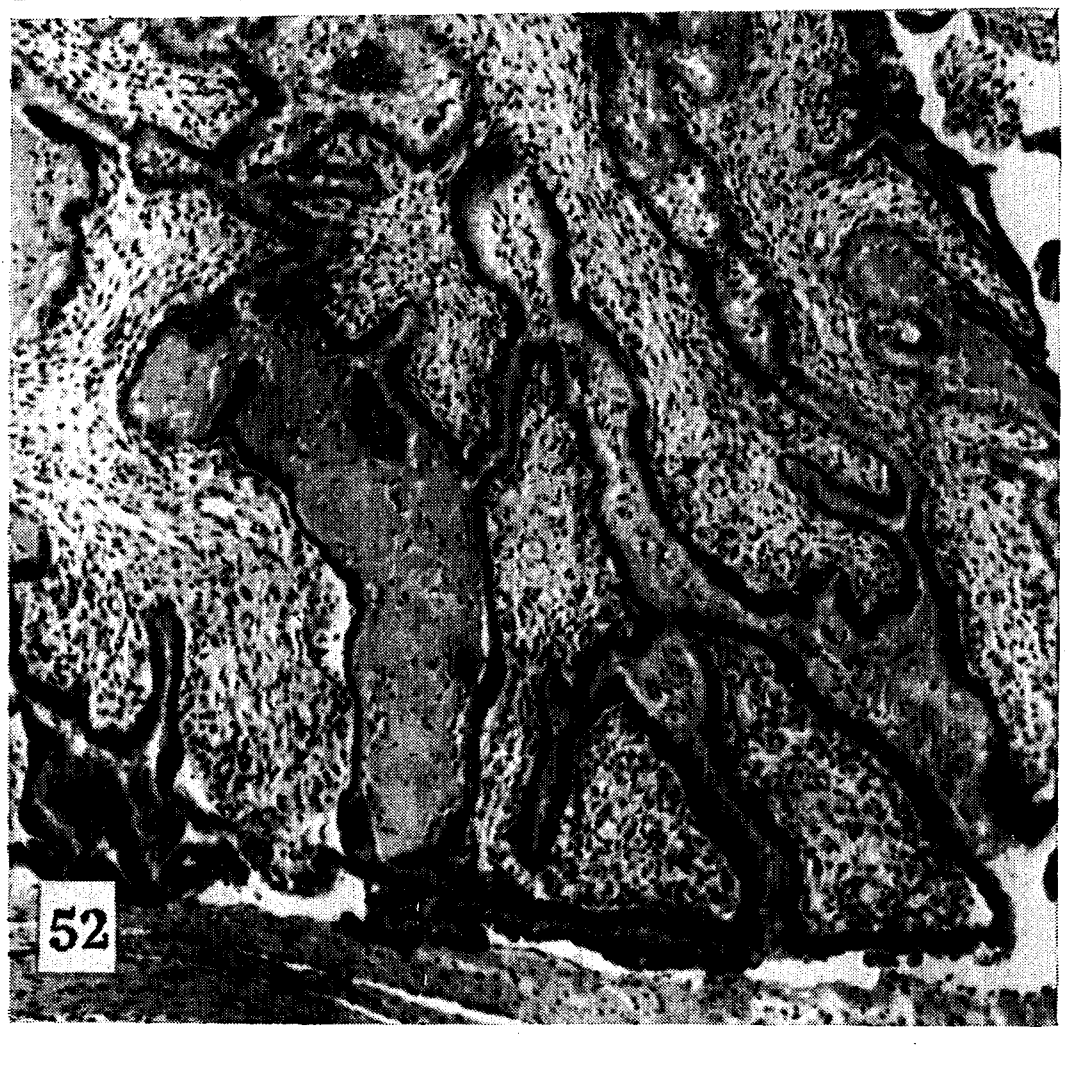
52

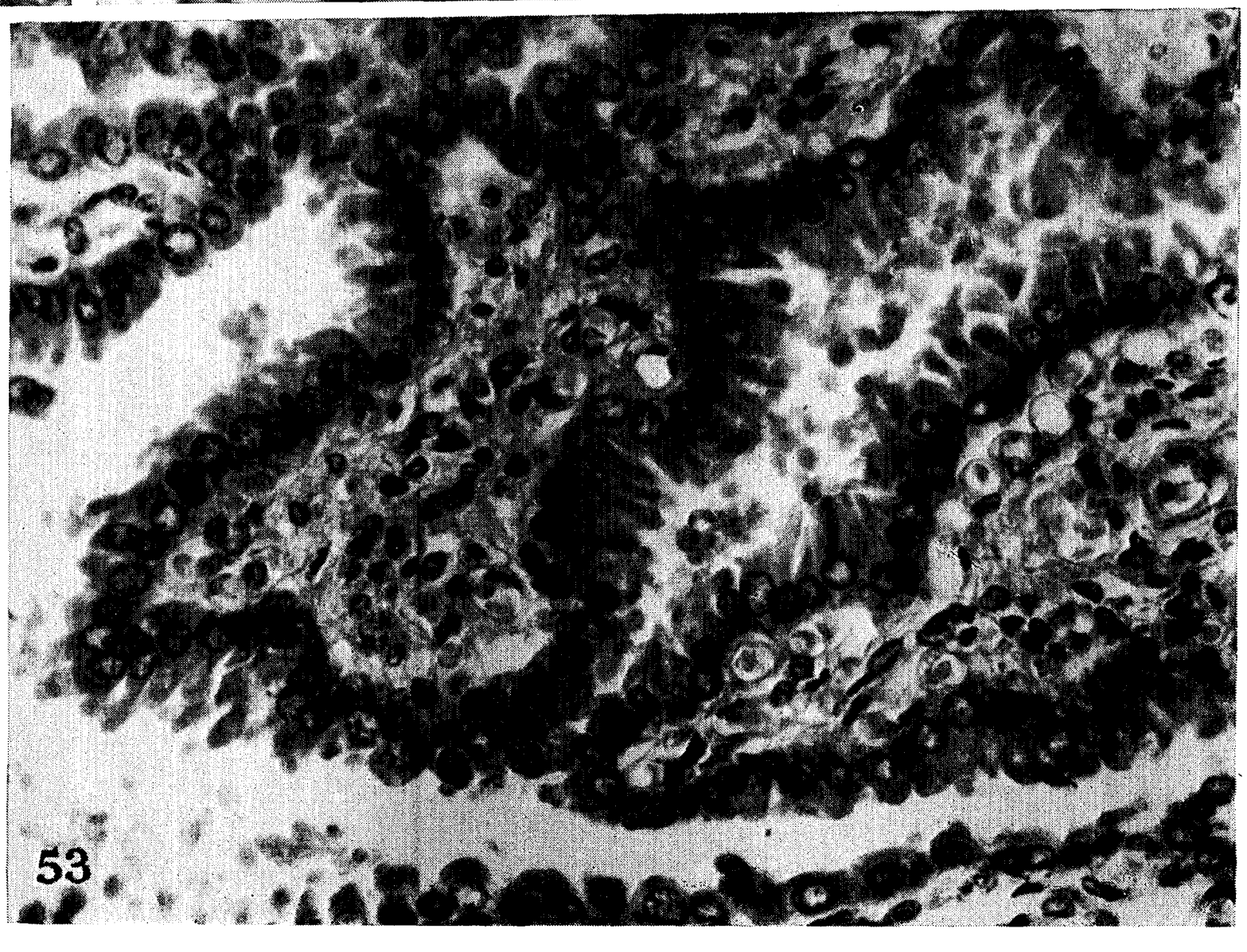
53

FIGURES 48 TO 53


54

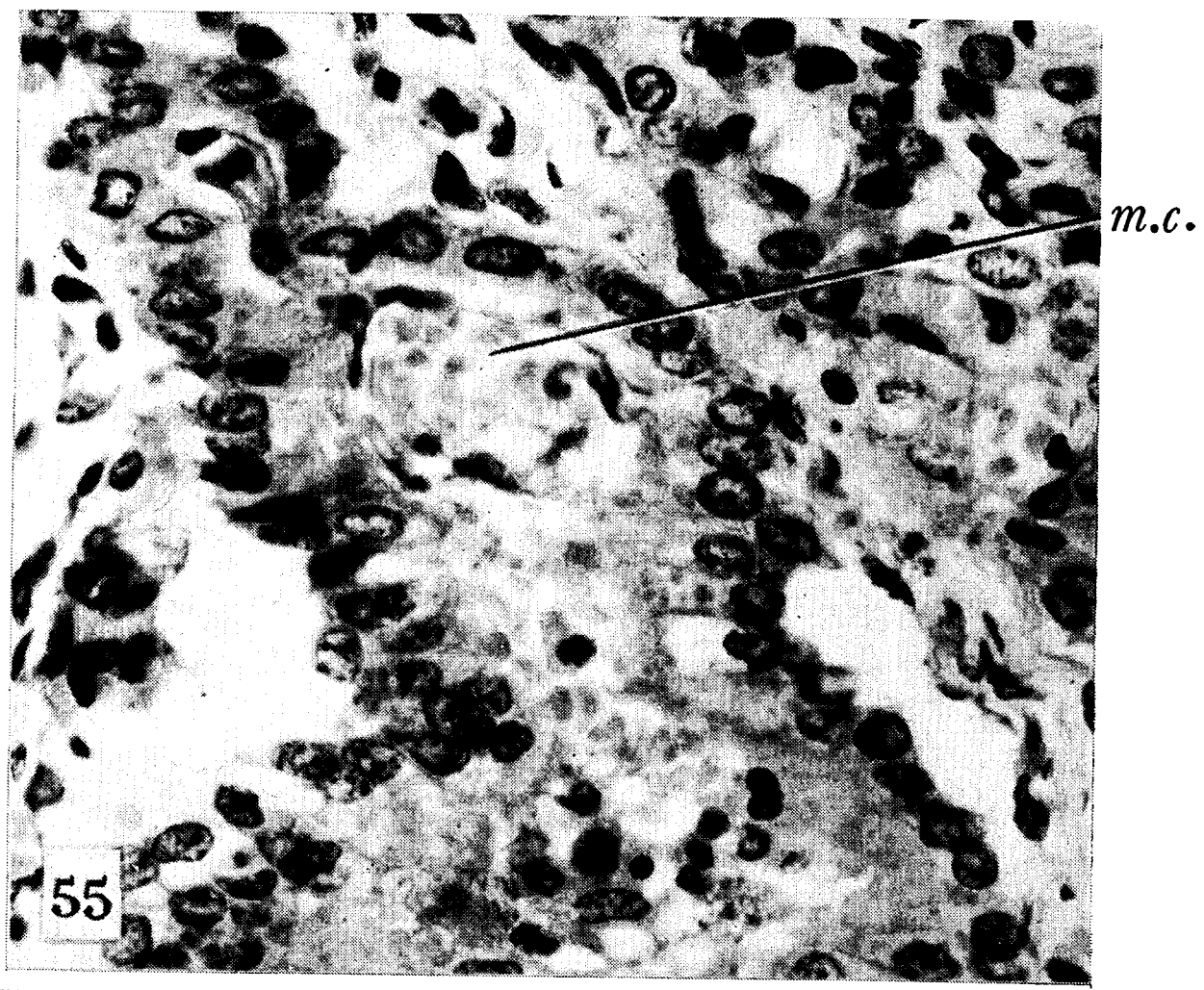
55

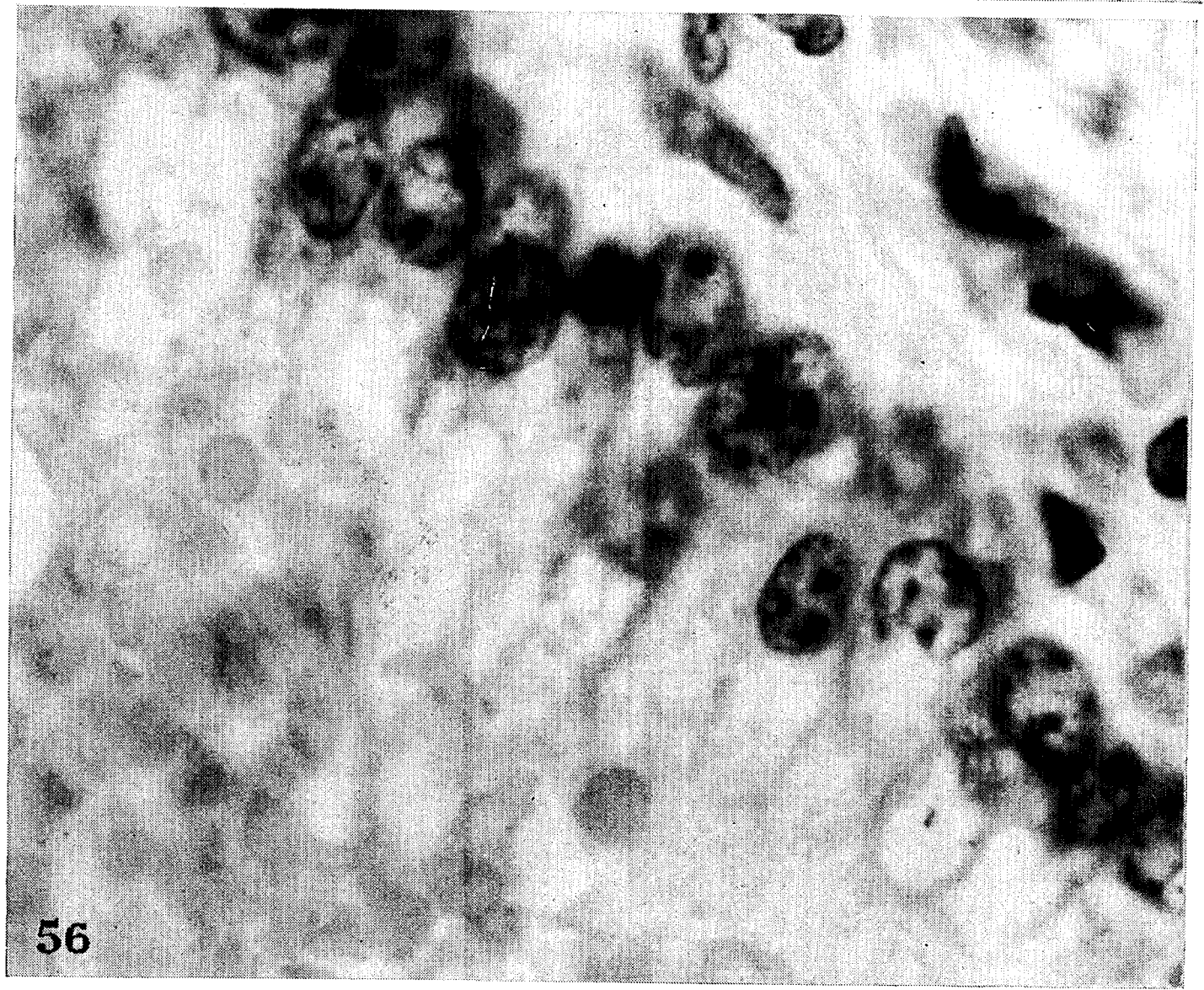
56

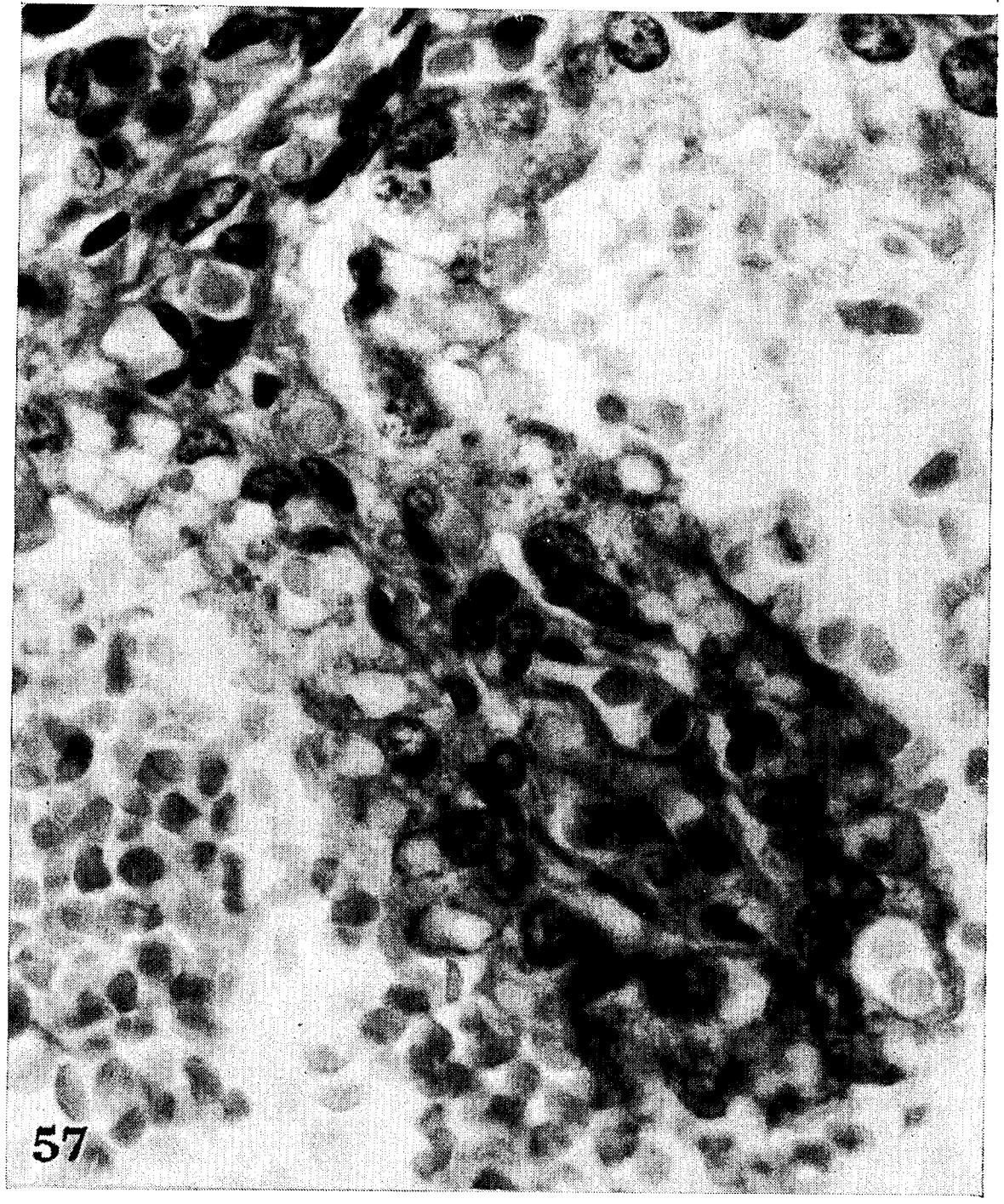
57

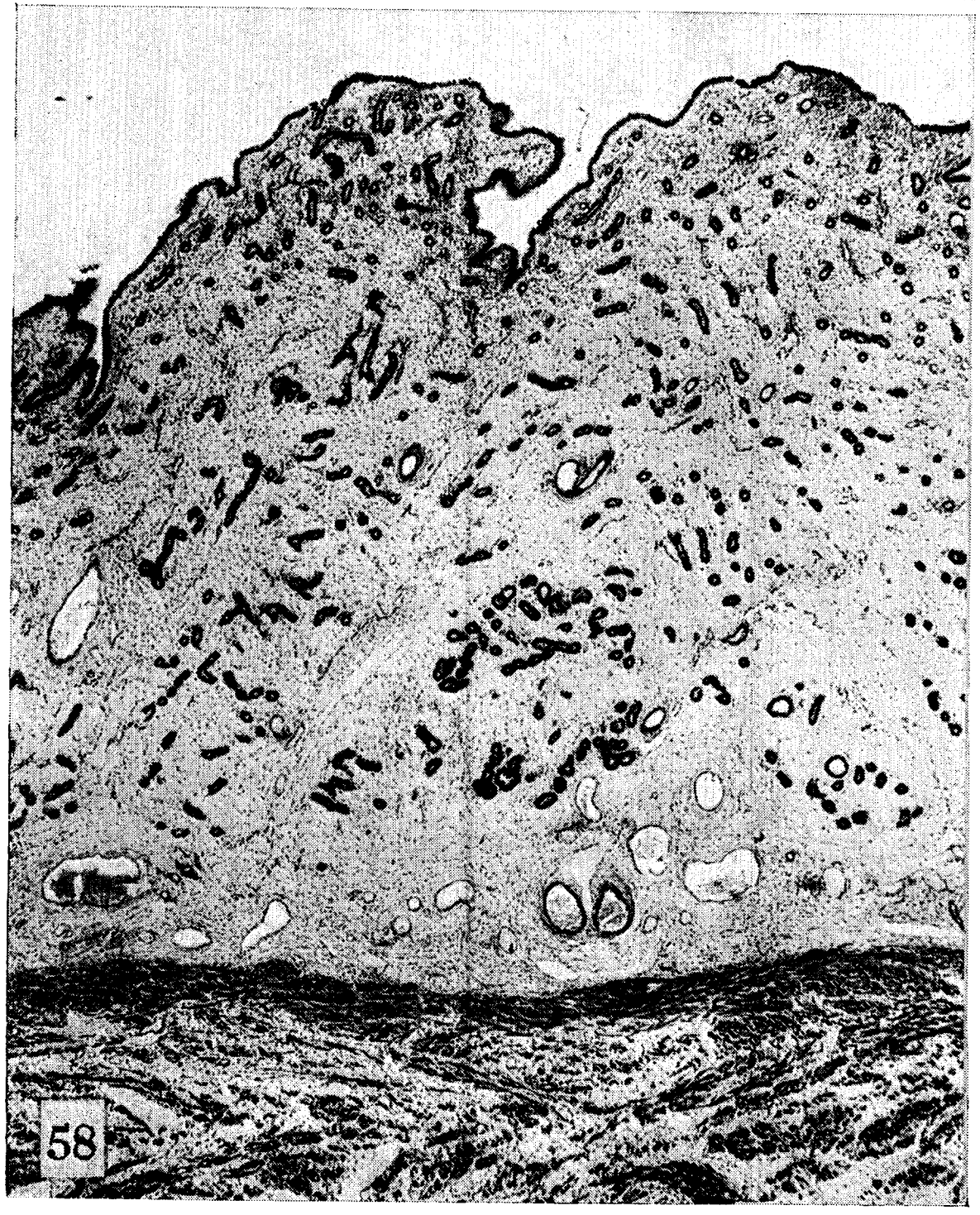
58

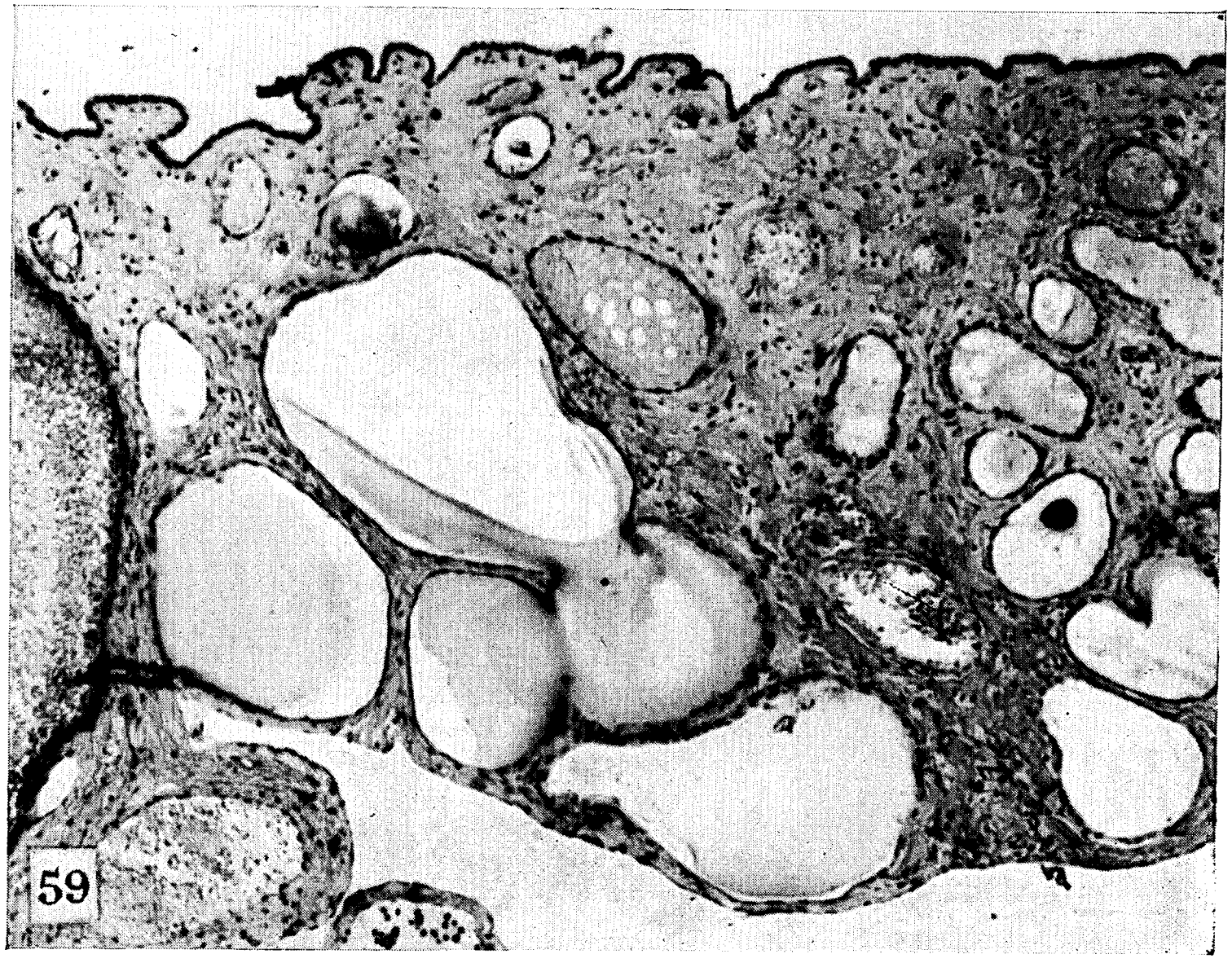
59

FIGURES 54 TO 59

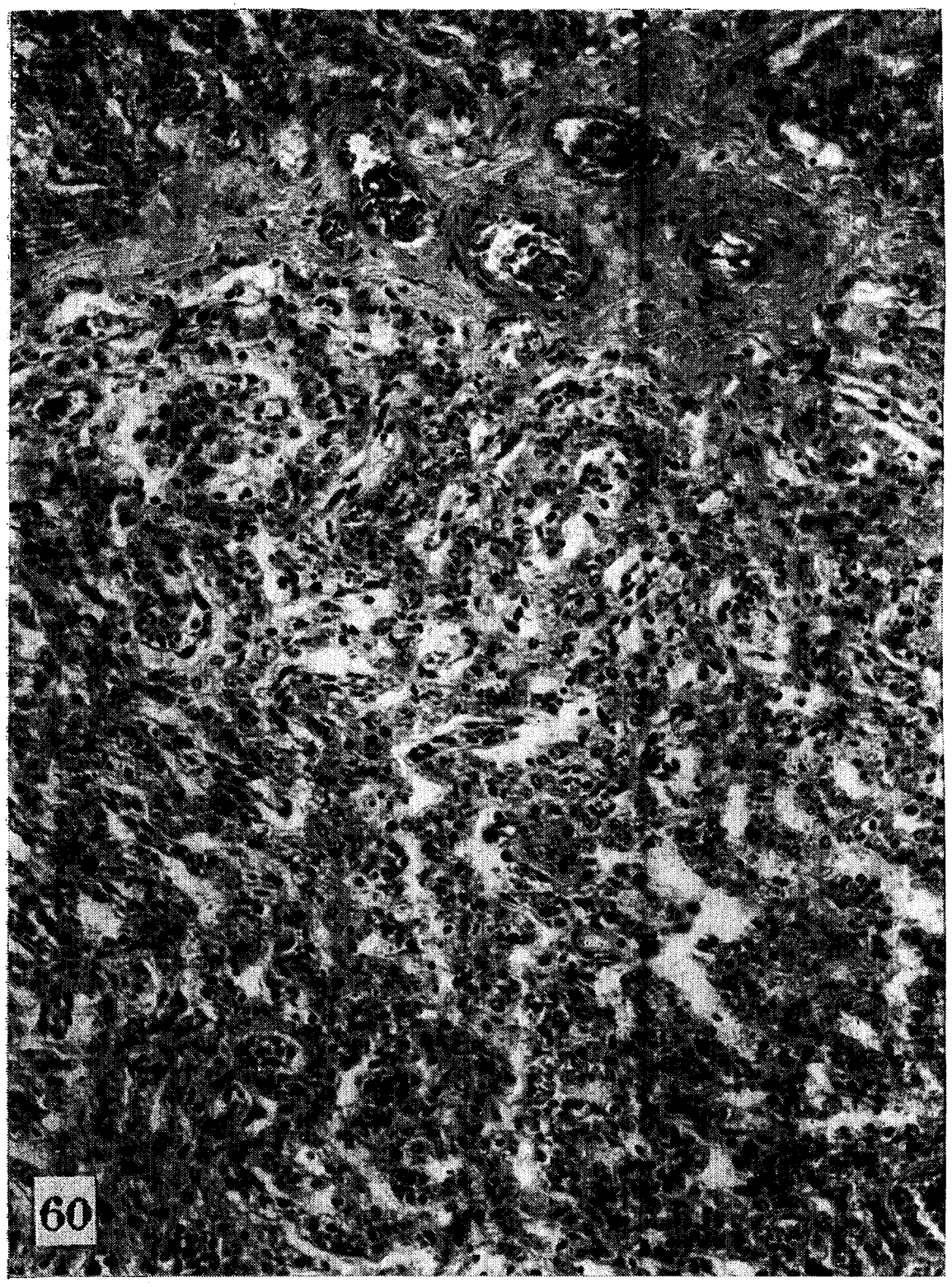
60


62


63


61

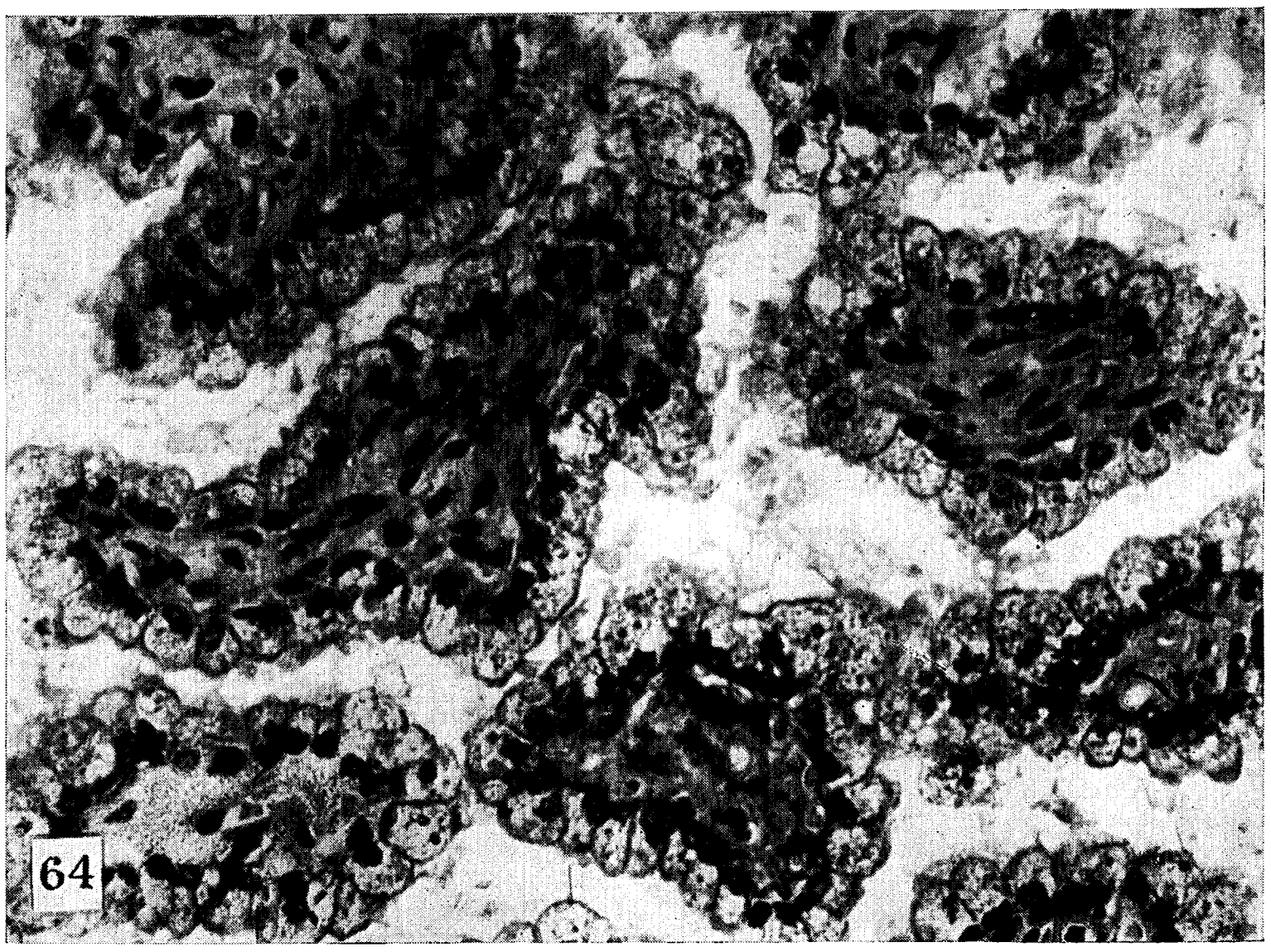
64

FIGURES 60 TO 64


65

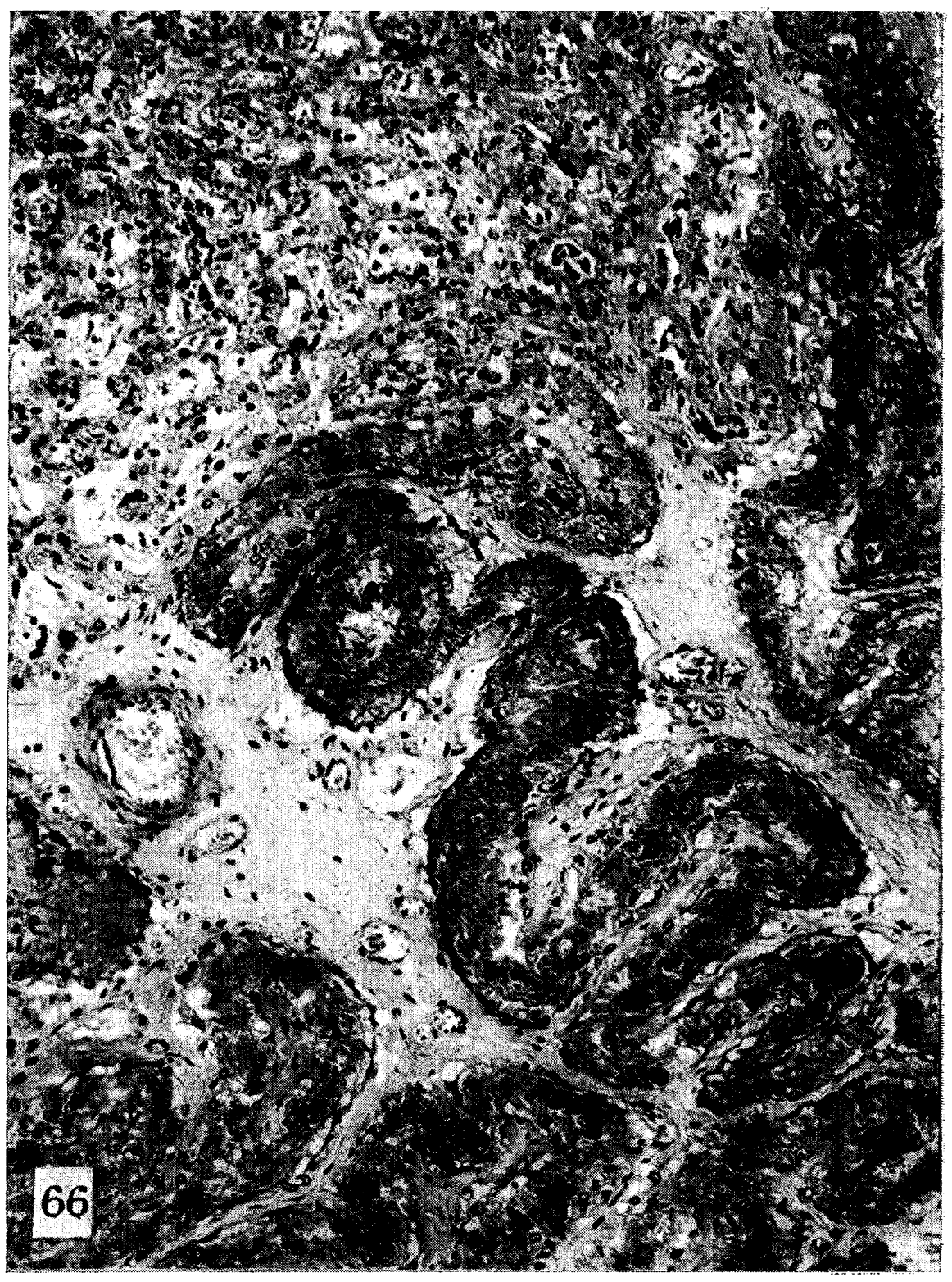
66


67

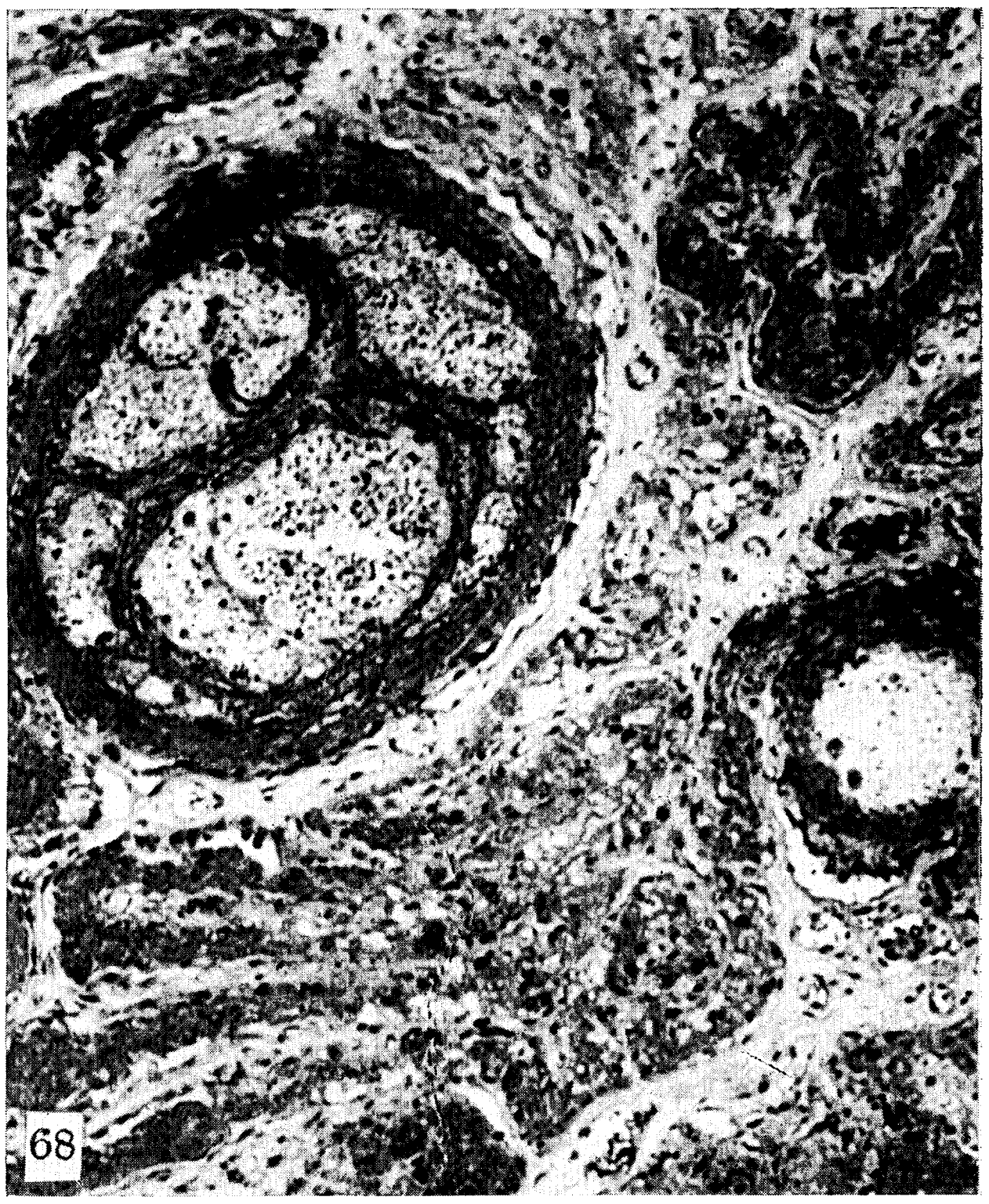
68

FIGURES 65 TO 68

Plate 5

Figure 22. E122. The allantoic 'arcade'; its floor is formed by part of the placental band, its roof by the allanto-amnion beneath the foetus, and the distance between roof and floor is traversed by the four pairs of umbilical vessels. The walls of the allantoic loculi have been cut away. (× 0·47.)

Figure 23. E147. Allantoic pustules; early mid-term. (× 1·0.)

Figure 24. E138. Allantoic pustules; mid-term. (× 3·0.)

Figure 25. E147. Pustules on ectodermal surface of amnion. (× 20.)

Figure 26. E147. Amniotic pustule in section. (× 330.)

Figure 27. E138. Allantoic pustule in section. (× 10·5.)

Plate 6

(All figures from specimen E1)

Figure 28. Vertical section through area of attachment. Zones I and II and part of uterine mucosa. (× 15.)

Figure 29. Local fusion between allantois and amnion. (× 140.)

Figure 30. Vascular yolk-sac wall (bilaminar omphalopleur). (× 630.)

Figure 31. T.S. margin of placental area; there is local extravasation of blood in the basal portions of the marginal crypts, lined by cytotrophoblast. The mucosal surface in the vicinity of the placental band, not yet invaded by foetal tissue, is elaborately folded and dissected. (× 45.)

Plate 7

Figure 32. E1. Portion of labyrinth (Zone I). (× 380.)

Figure 33. E1. Paraplacental chorion. (× 380.)

Figure 34. E1. Tip of an invading trophoblastic villus. (× 720.)

Figure 35. E36. Portion of labyrinth (Zone I), cf. figures 32, 38 and 60. (× 350.)

Figure 36. E36. Placental margin (Zones I and II). The foetal connective tissue has shrunk away from the trophoblast in fixation. Syncytiotrophoblastic trabeculae, enclosing maternal capillaries, are seen in the upper part of the photograph. In the lower part are wider crypts, bounded by cytotrophoblast and containing extravasated maternal blood. (× 120.)

Plate 8

Figure 37. E147. Transection through the central region of the placental band (Zones I and II). (× 10·5.)

Figure 38. E147. Portion of labyrinth (Zone I) shown in figure 37. (× 115.)

Figure 39. E147. Portion of labyrinth (Zone I). (× 600.)

Figure 40. E138. A portion of the marginal region which has become separated from Zone II and enclosed within the labyrinth (Zone I). (× 100.)

Plate 9

Figure 41. E147. The marginal zone (Zone III) and part of the adjoining labyrinth (Zone I). (× 70.)

Figure 42. E138. A large maternal blood vessel, cut longitudinally, within the labyrinth (Zone I). The area enclosed in the rectangle is shown at higher magnification in figure 43. (× 150.)

Figure 43. E138. Part of figure 42, enlarged to show the continuity of the eosinophilic material which lies within the trabeculae of the labyrinth and between the maternal endothelium and the trophoblast. (× 450.)

Figure 44. E138. Large maternal blood vessel and two foetal vessels in T.S. (× 250.)

Figure 45. E138. Part of figure 42, showing elongated nuclei of the cytotrophoblast which is applied to the wall of the maternal vessel. (× 1200.)

Figure 46. E 138. The edge of the placental band, showing the transition from the simple epithelium of the extraplacental chorion, through a region of simple folds or crypts (cf. figure 33) to the complex villous structure of the placental band. (× 45.)

Plate 10

Figure 47 *a*, *b*. E 138. T.S. through the junctional zone (Zone II) from the base of the labyrinth (Zone I) to the uterine mucosa. The bottom edge of *a* slightly overlaps the top edge of *b*. (× 70.)

Plate 11

Figure 48. E 138. The necrotic portion of Zone II, near the labyrinth, part of which is seen at the left. Maternal blood is collected into a venous channel (*v.c.*) on the right of the photograph. (× 70.)

Figures 49 to 51. The middle part of the junctional zone. Figure 49 (× 45) was photographed from specimen E 117, figure 50 (× 240) from specimen E 138, and figure 51 is a H.P. photograph (× 1200) of the trophoblast in the area shown in figure 49.

Figure 52. E 138. The 'lobate' villi of the base of the junctional zone (cf. figure 47) in a region where the foetal-maternal contact has been preserved. (× 70.)

Figure 53. E 147. The 'lobate' villi in early mid-pregnancy, showing their highly vascular mesenchyme, active-looking cytotrophoblastic epithelium, and entrapped detritus. (× 335.)

Plate 12

Figure 54. E 138. The placental border. The mouths of the crypts of the margin (Zone III) are sealed by a non-cellular eosinophilic coagulum. The uterine mucosa is seen (lower right), and villi of the central attachment area have been squeezed outwards so that they lie between, but not attached to, the coagulum above and the uterine wall below. (× 20.)

Figure 55. E 138. Junction of Zones I and III showing the terminal portion of a maternal capillary (*m.c.*) which traverses Zone I and is ruptured at the junction with Zone III. There are blood corpuscles in the lumen of the crypt and some have been ingested by cytotrophoblast cells. (× 440.)

Figure 56. E 138. H.P. of cytotrophoblast lining the upper part of the crypt shown in figure 55. (× 1200.)

Figure 57. E 138. The tip of a cytotrophoblastic villus in the marginal region (Zone III); cf. corresponding villus in the central region (Zone II) in figure 53. (× 615.)

Figure 58. Uterine endometrium of a non-pregnant adult. (× 24.)

Figure 59. E 138. Paraplacental endometrium. (× 85.)

Plate 13

(All photographs of E 148, full term)

Figure 60. Labyrinth (Zone I). (× 120.)

Figure 61. H.P. of labyrinth, showing intra-epithelial capillaries. (× 860.)

Figure 62. Upper part of junctional zone (Zone II); cf. figure 48. (× 67.)

Figure 63. Basal part of junctional zone; foetal tissue abuts directly on myometrium; cf. figure 52. (× 52.)

Figure 64. Marginal villi (Zone III). (× 300.)

Plate 14

Figures 65 to 67. Successive stages in the occlusion of maternal capillaries in lamellae (Zone I). One of the larger maternal vessels is occluded in figure 67. Figure 65 (× 240); figure 66 (× 105); figure 67 (× 130.)

Figure 68. Fibrous growth occluding one of the larger maternal vessels, seen in T.S. (× 110.)

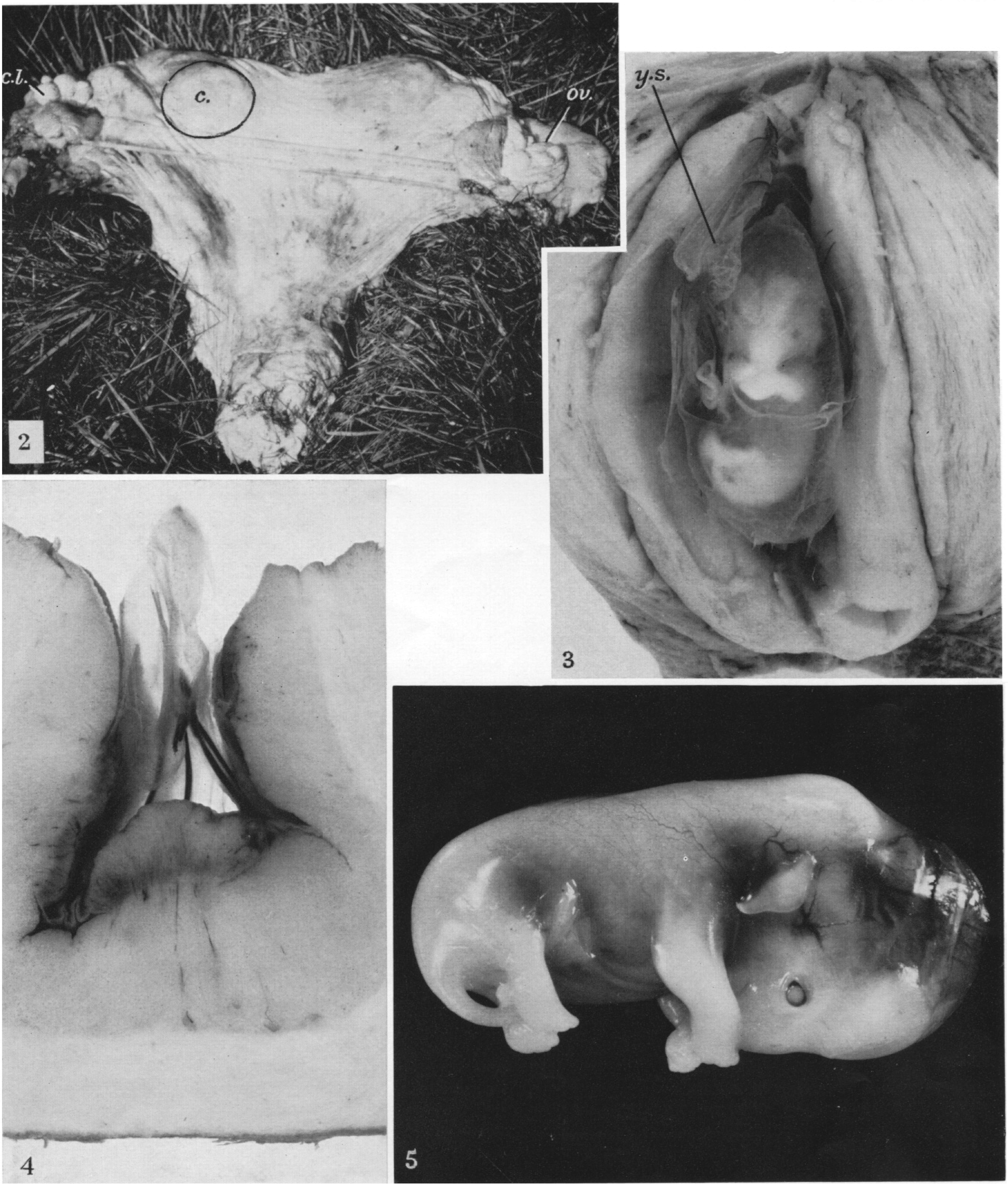

FIGURES 2 TO 5

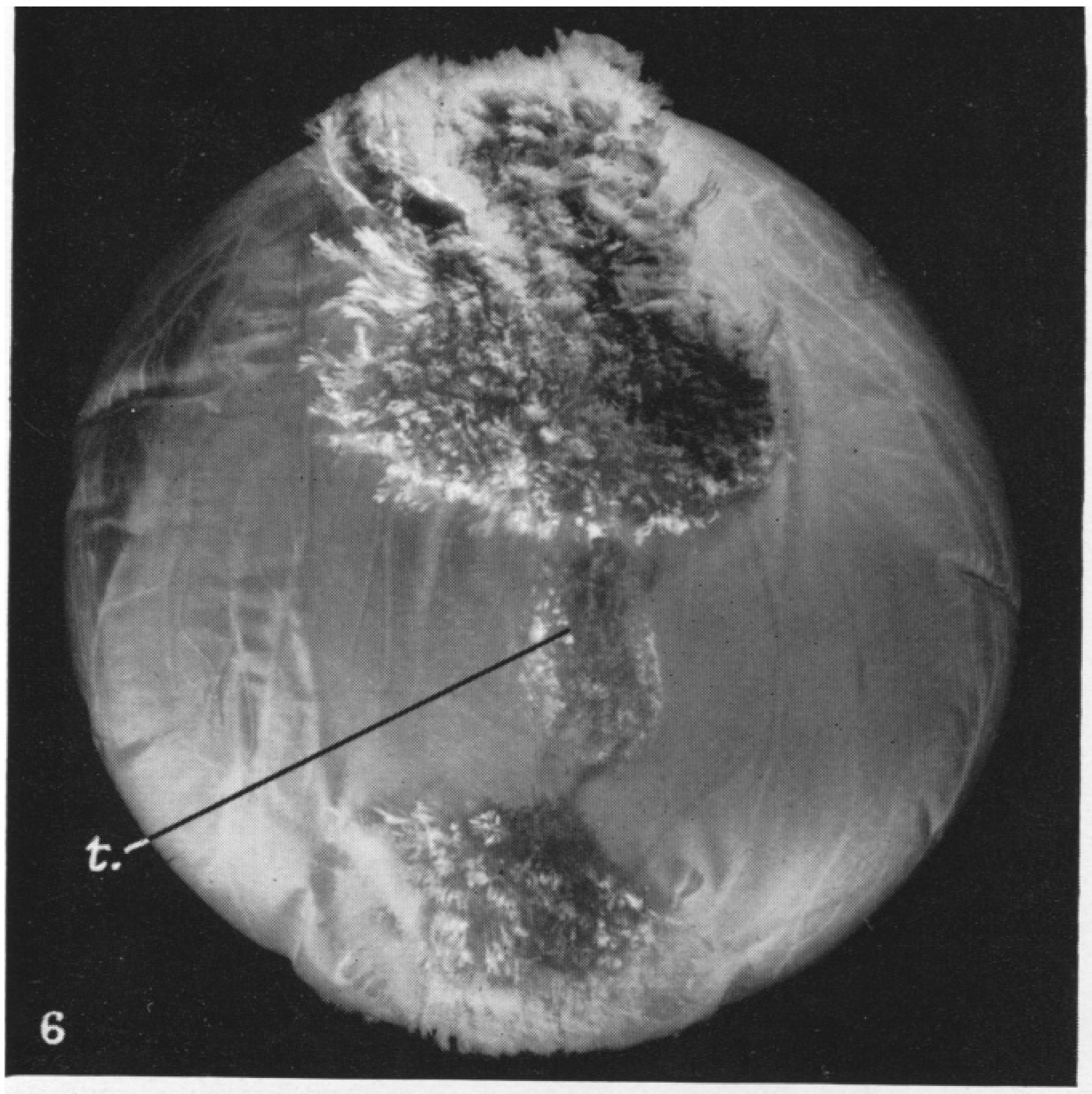

6

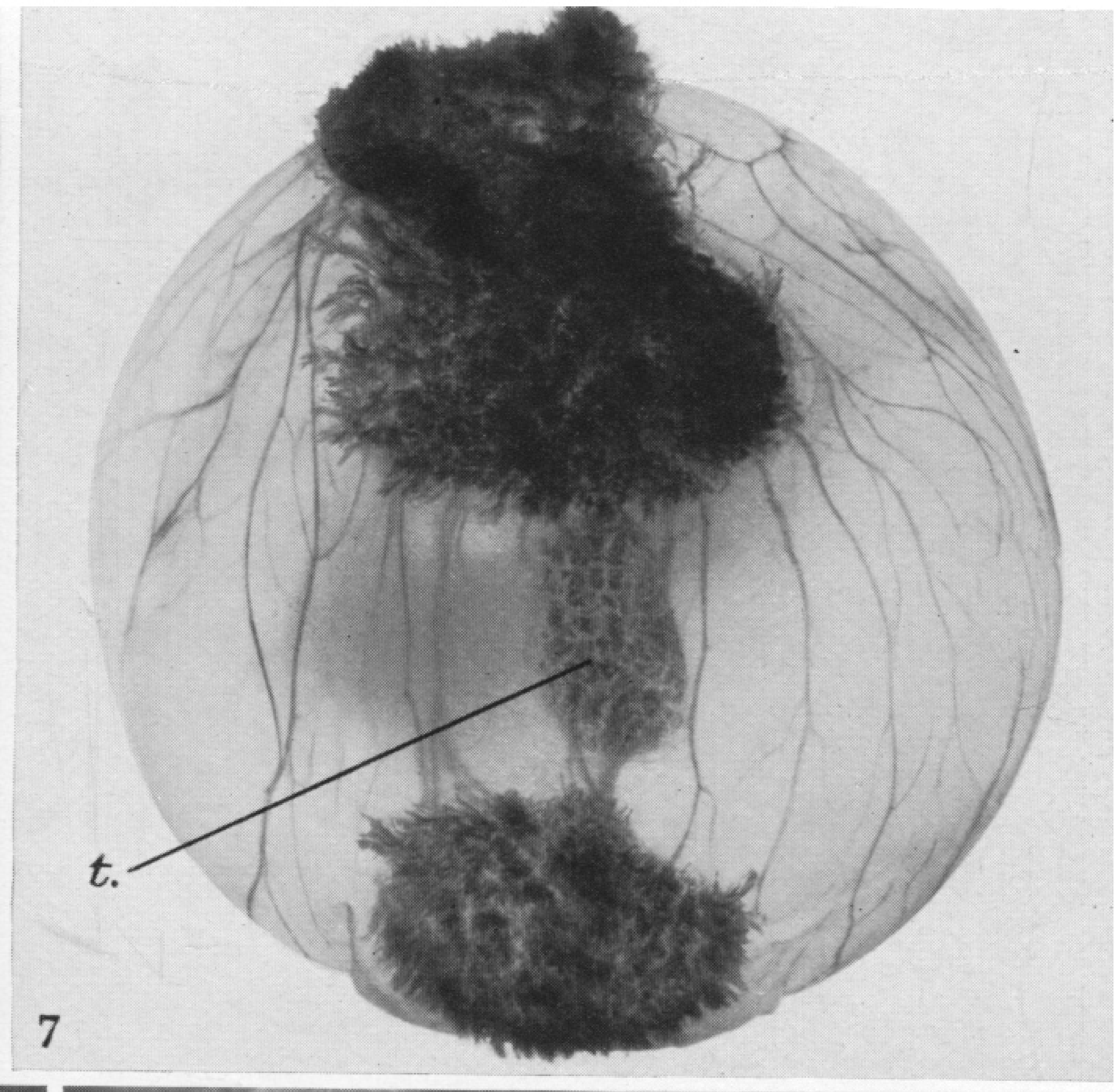

7

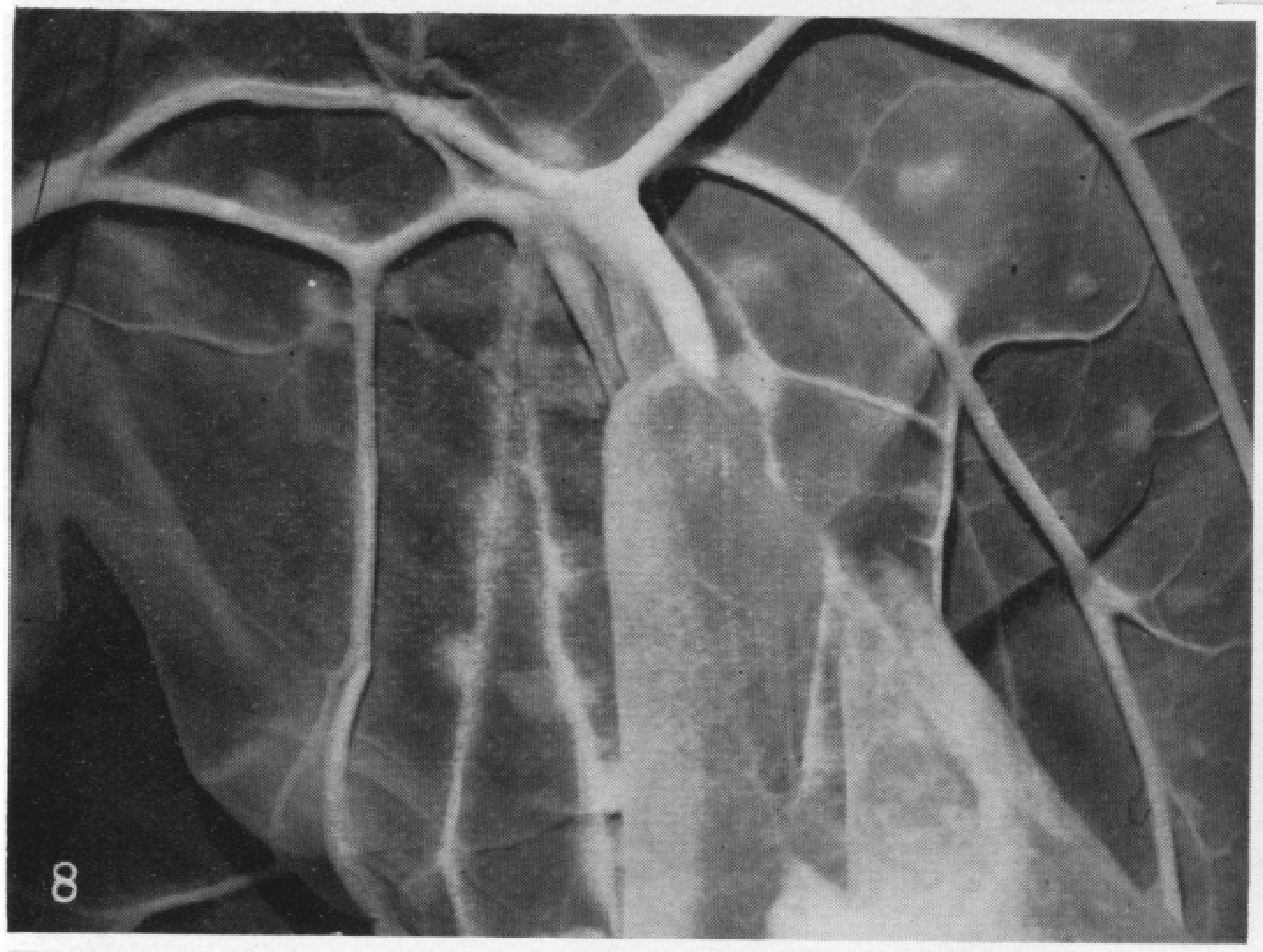

8

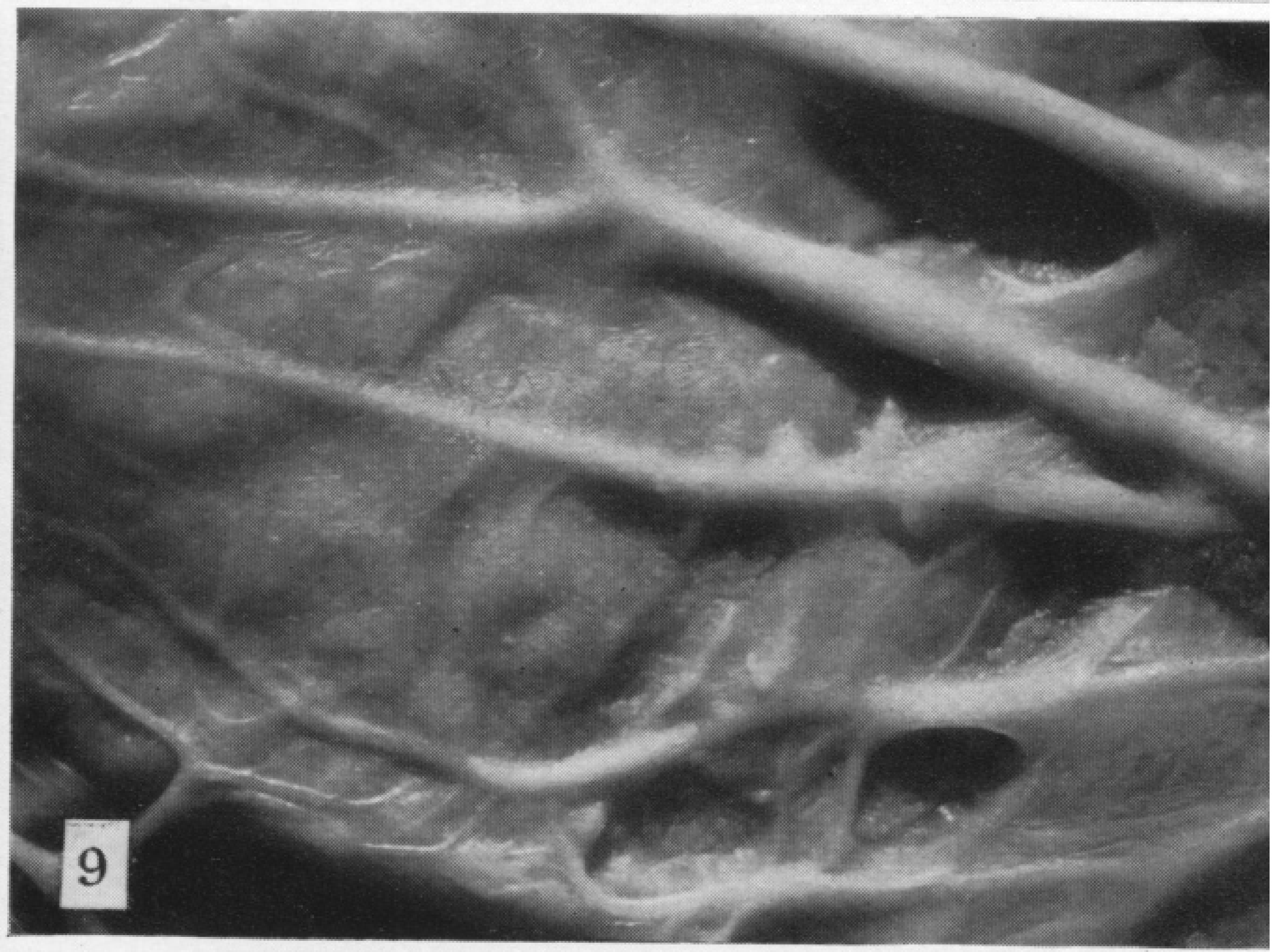

9

10

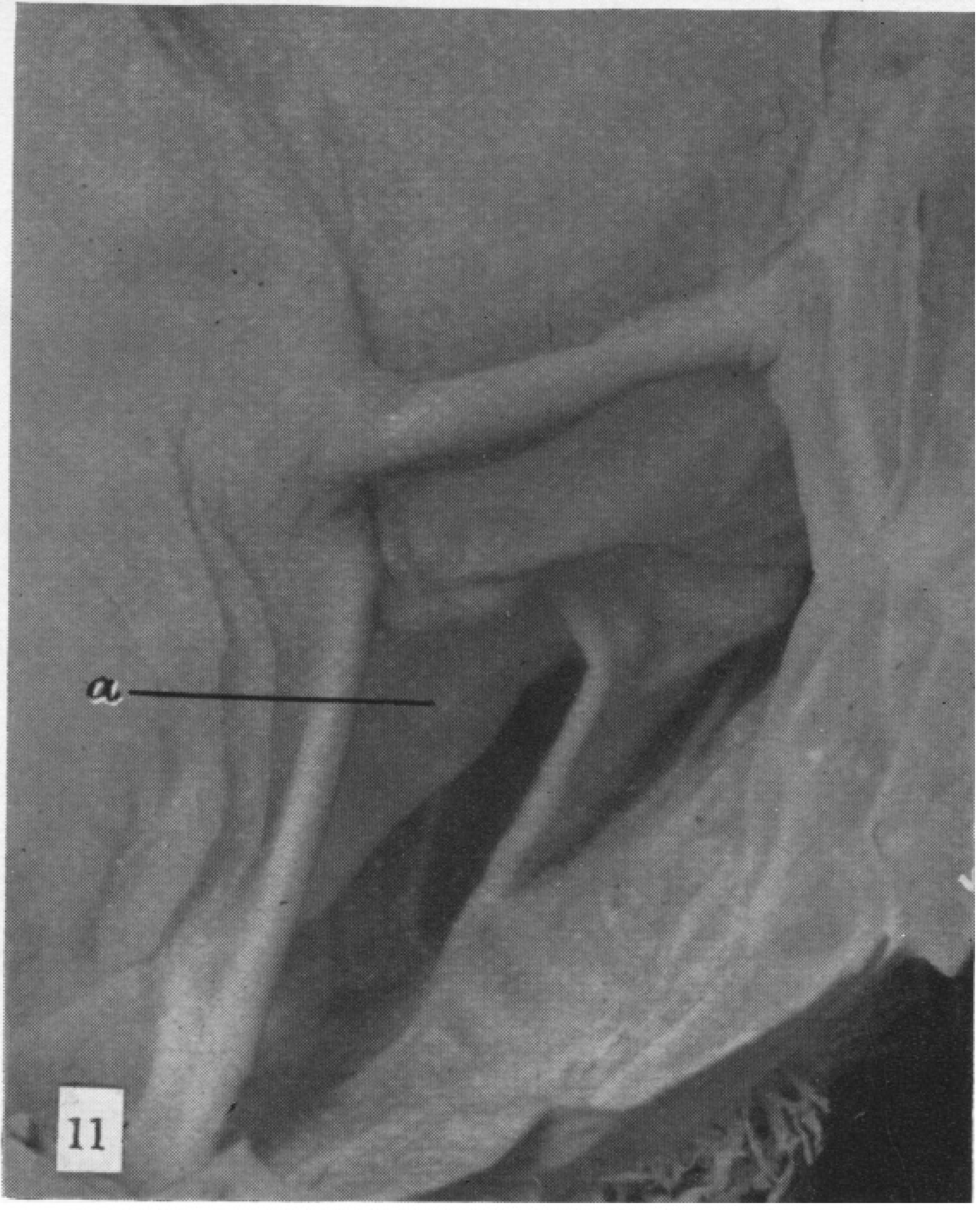

11

Figures 6 to 11

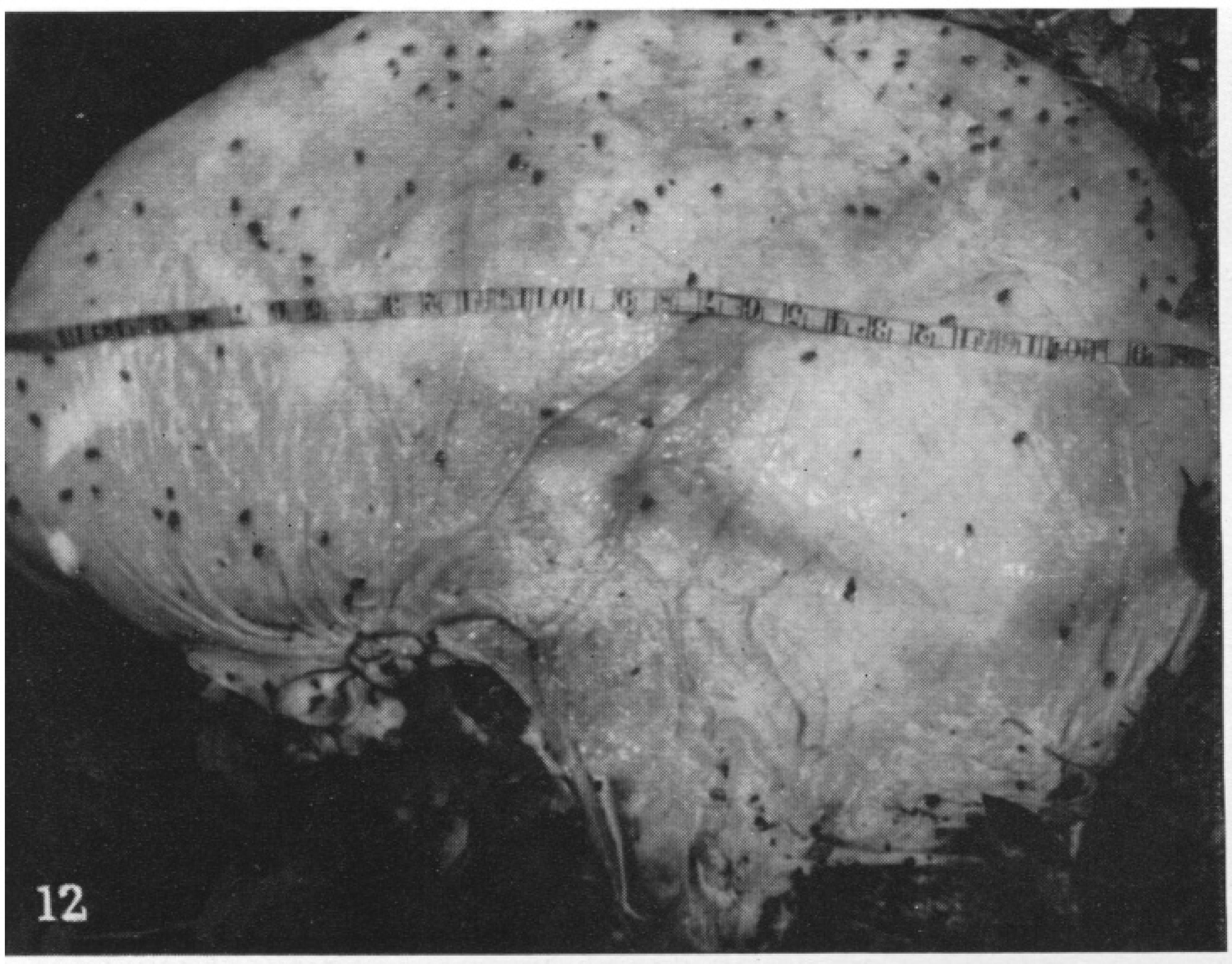
12

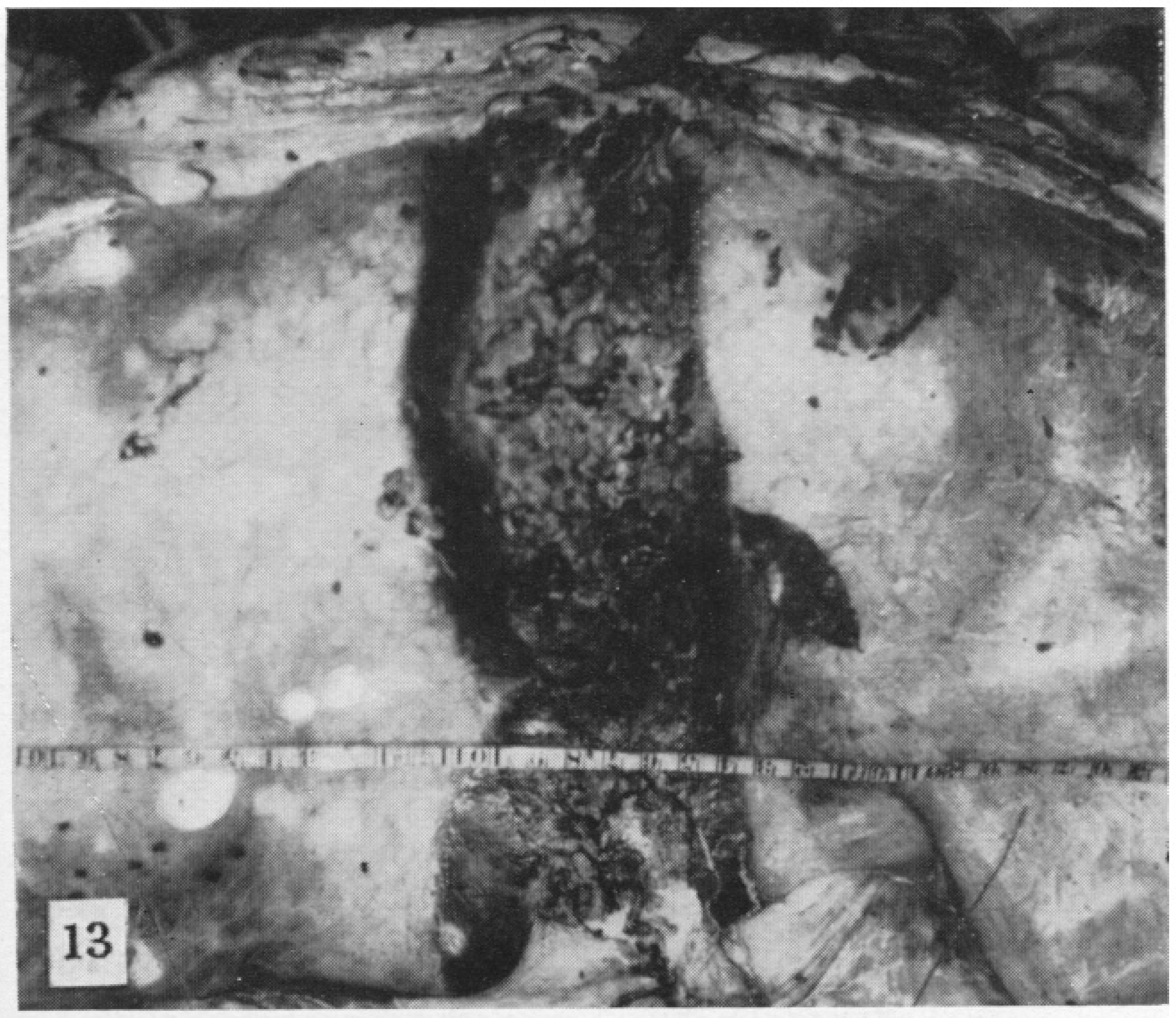
13

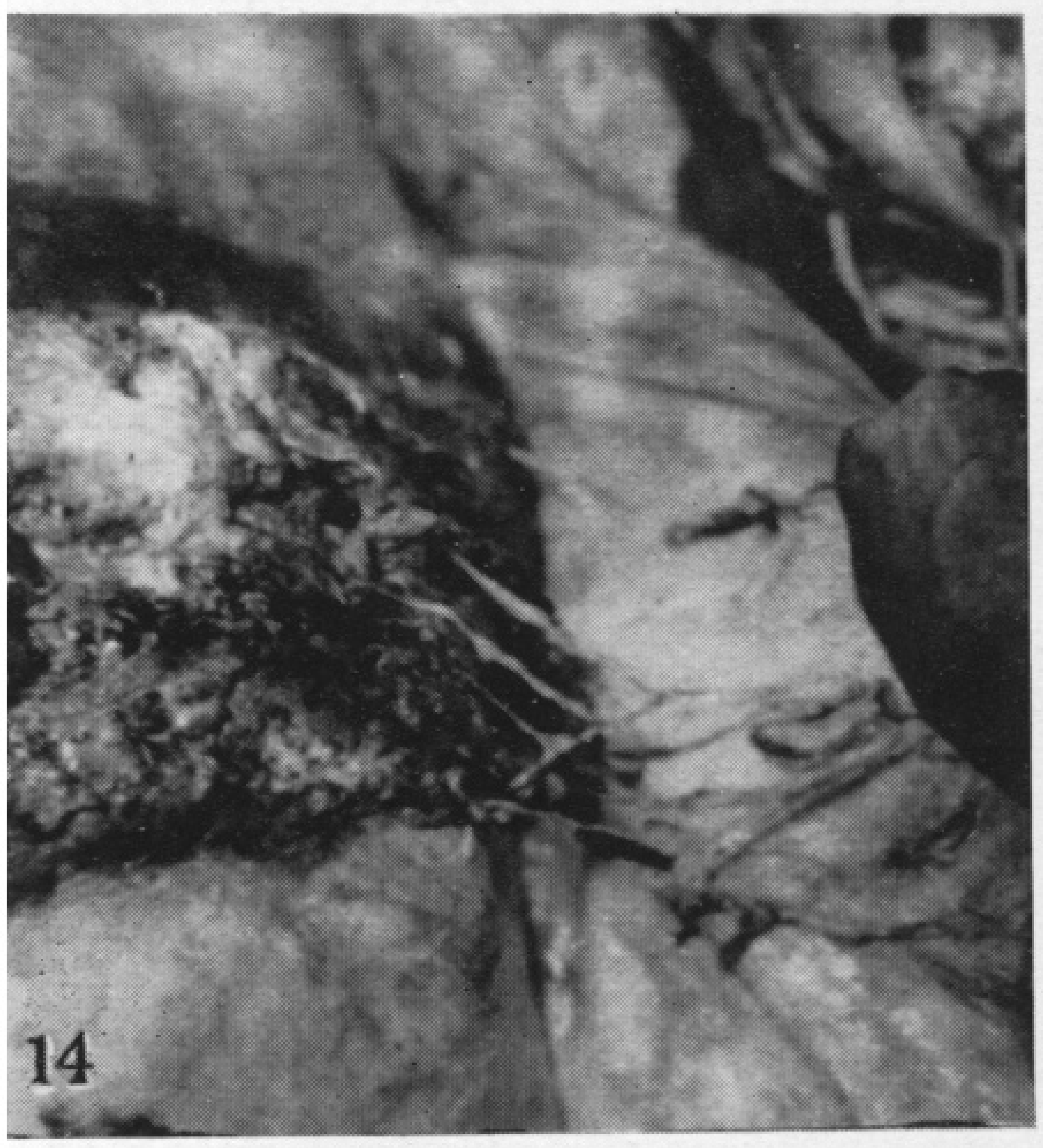
14

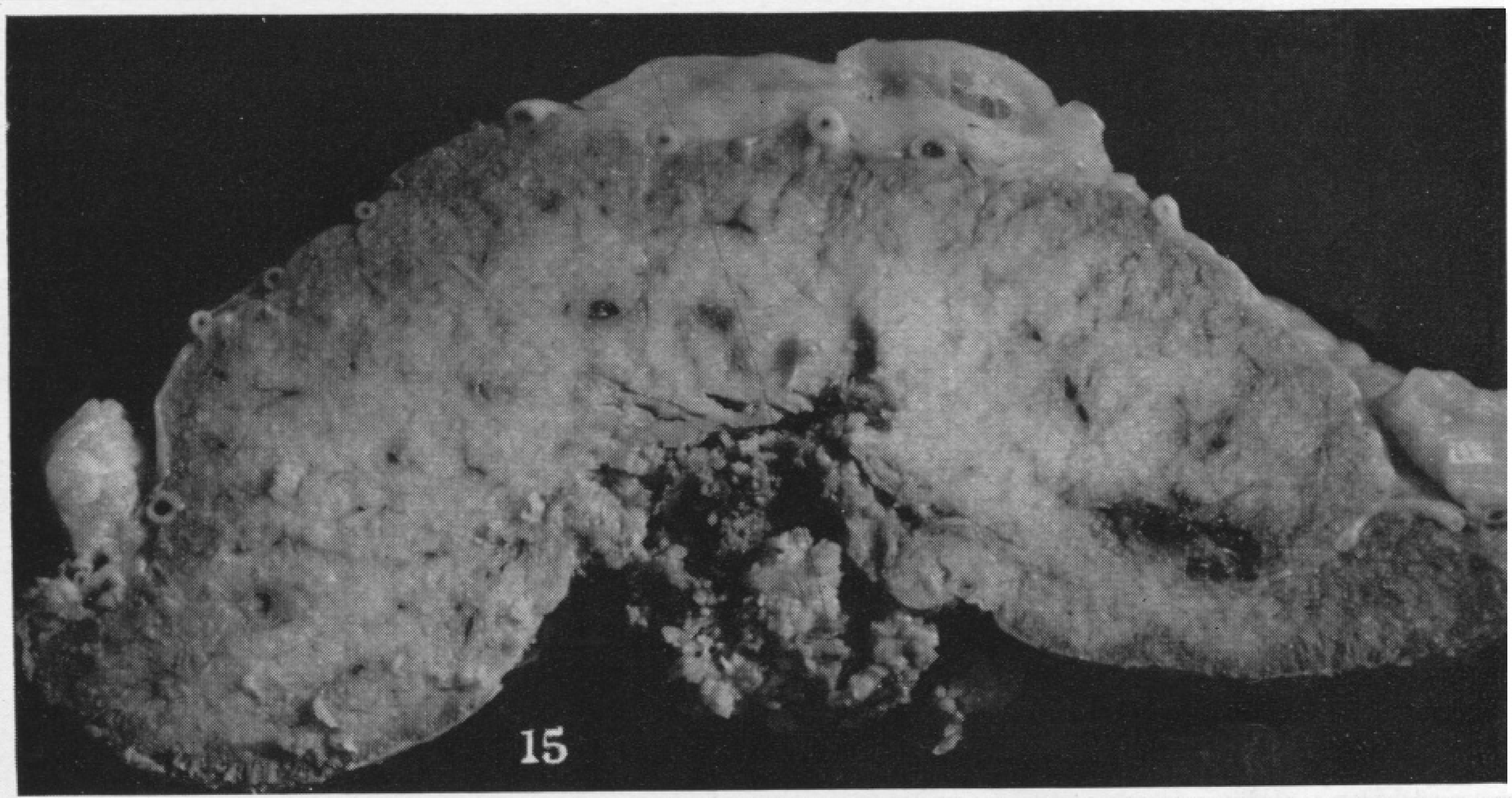
15


16

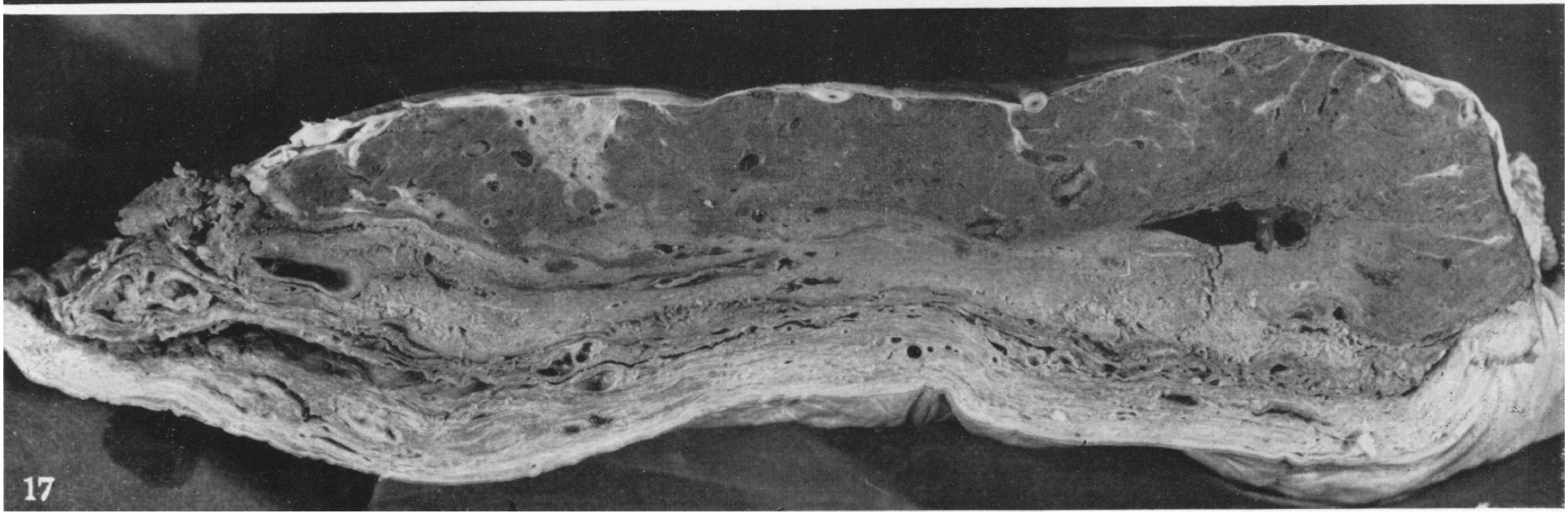
17

Figures 12 to 17

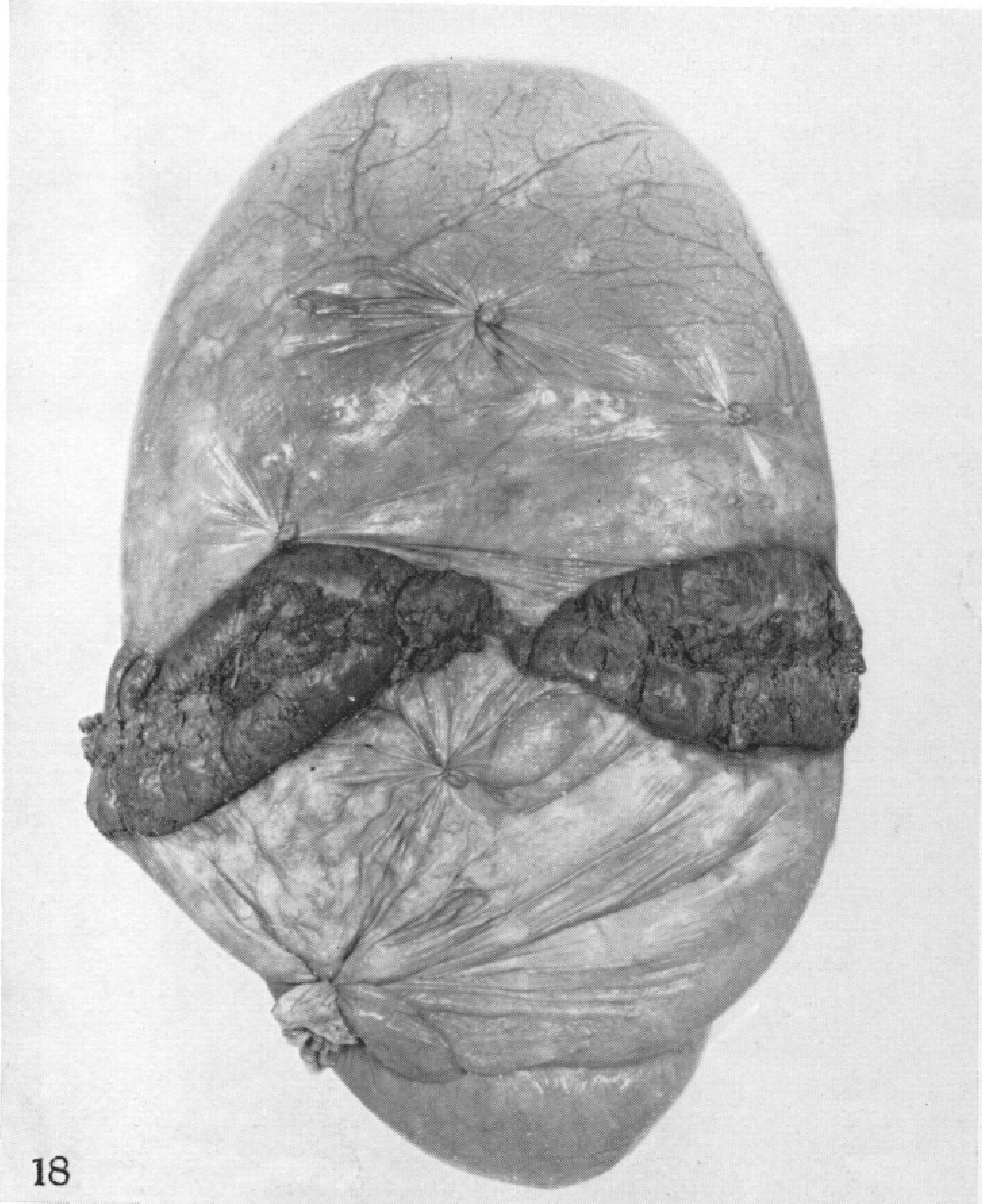

18

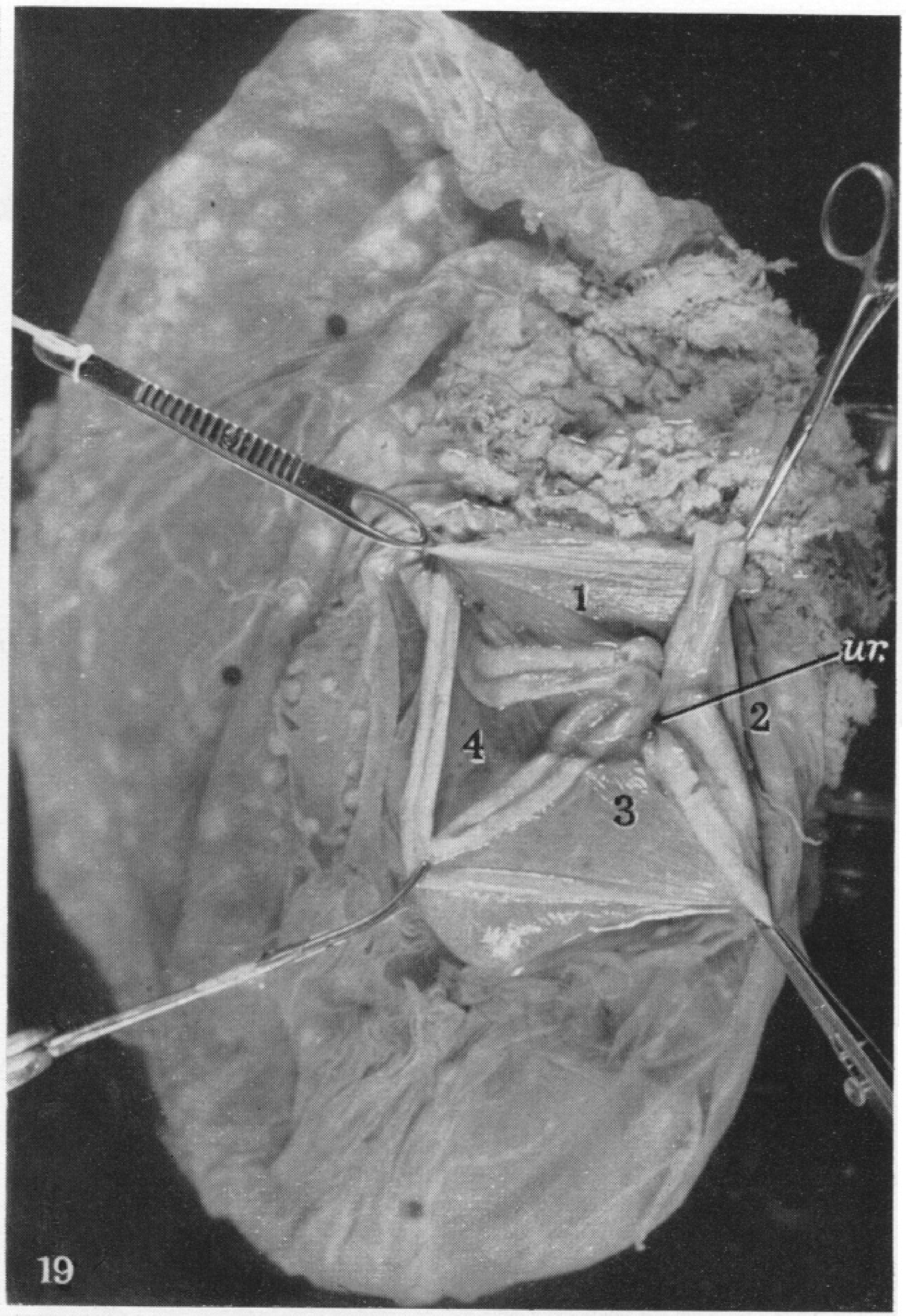

19

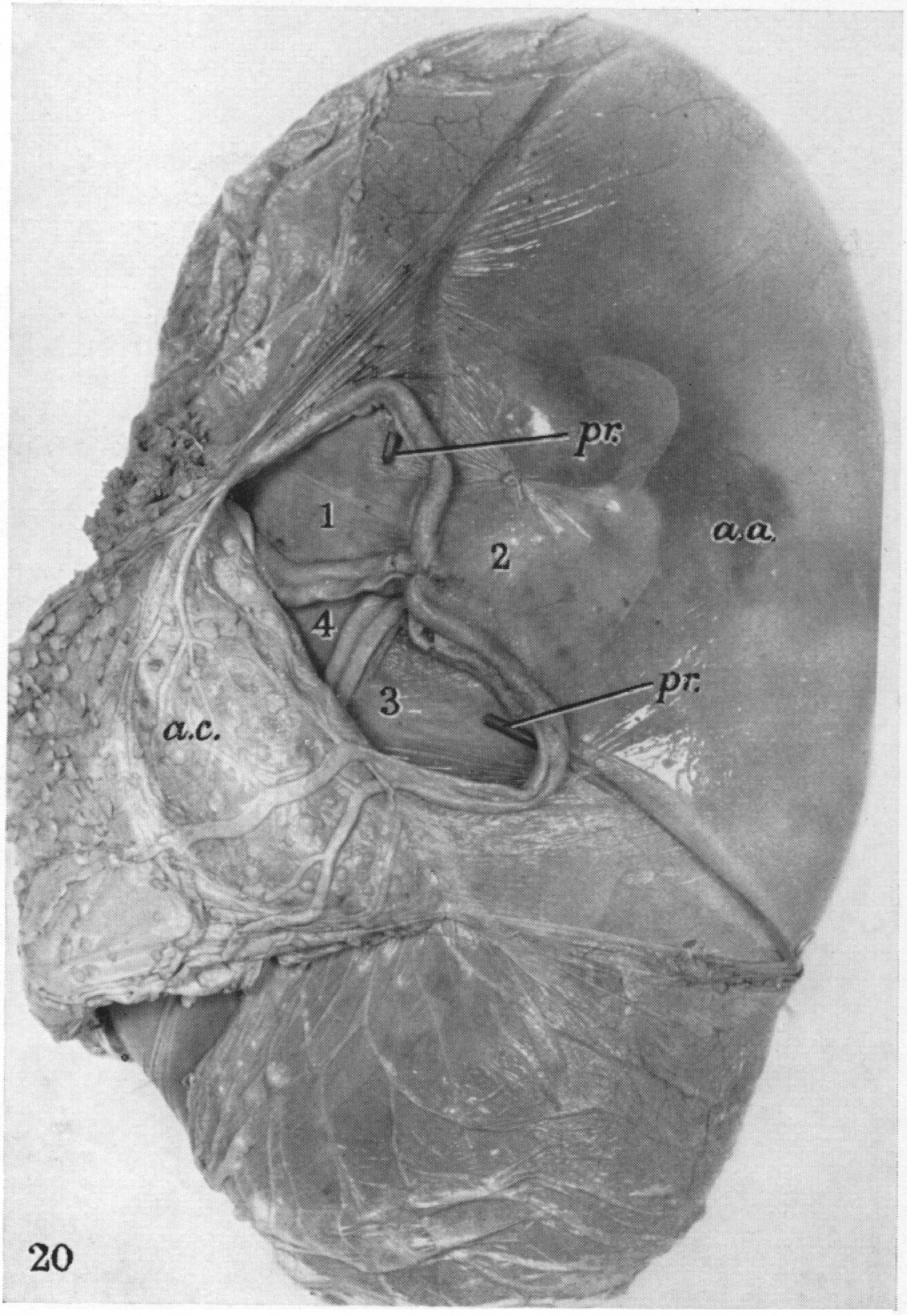

20

21

Figures 18 to 21

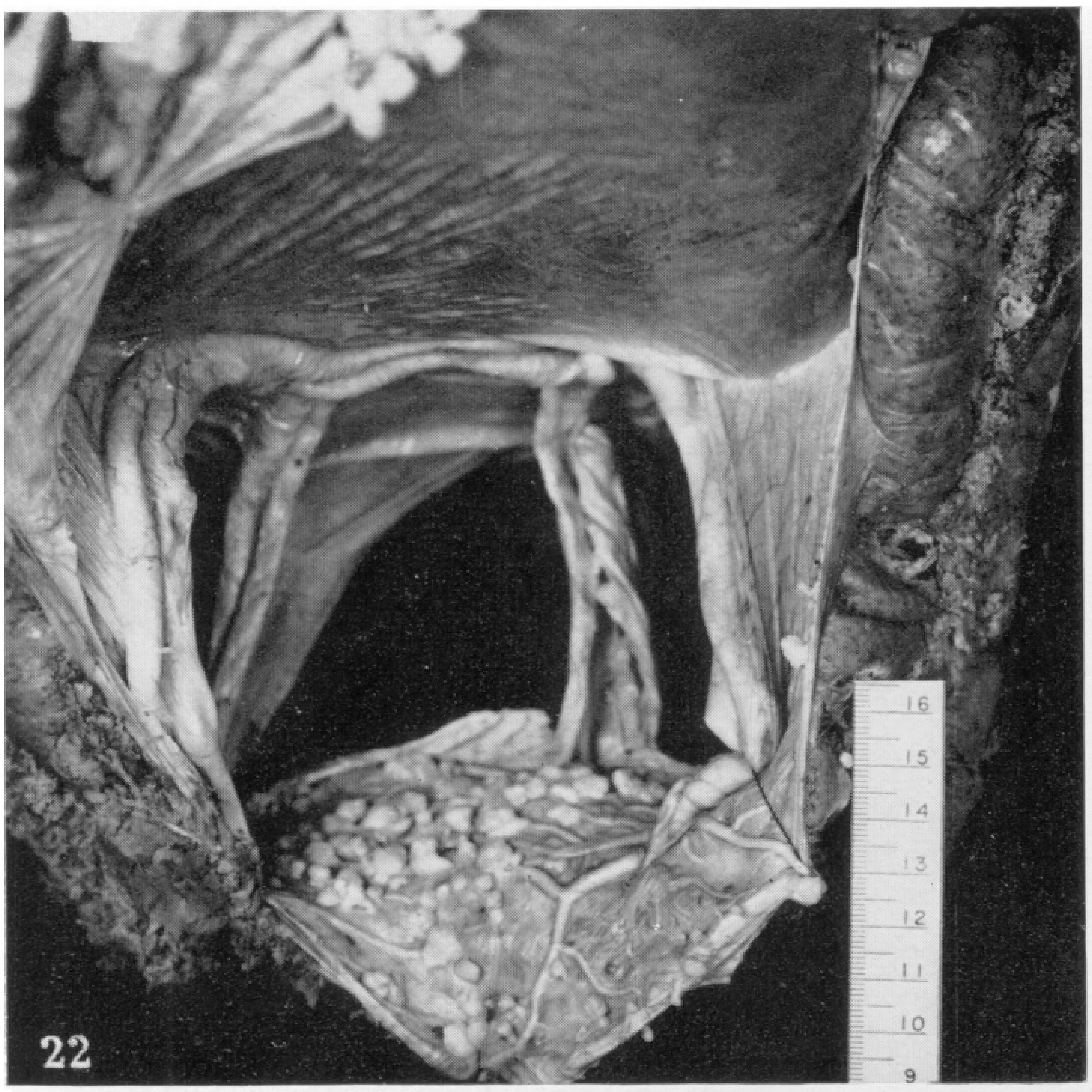

22

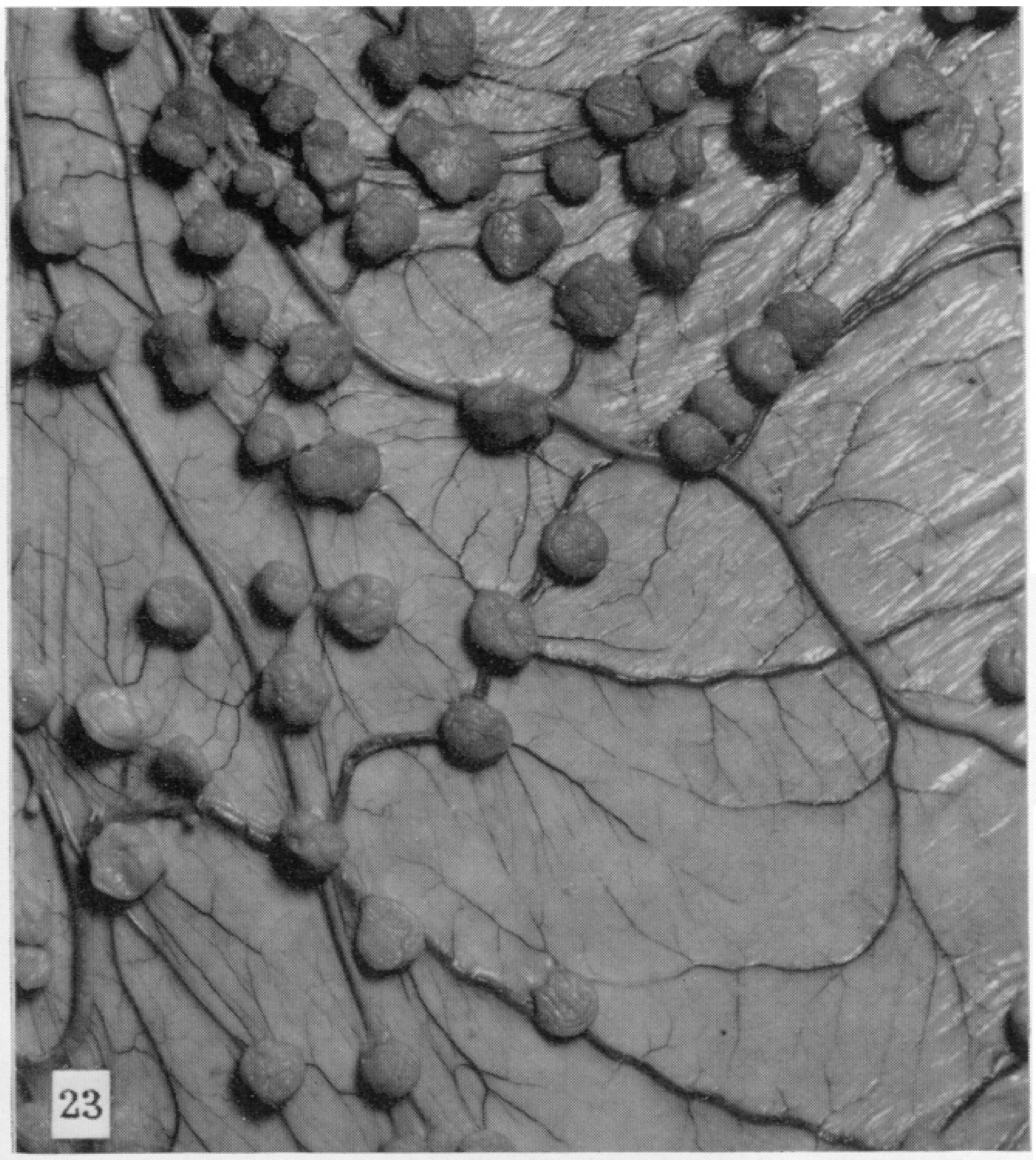

23

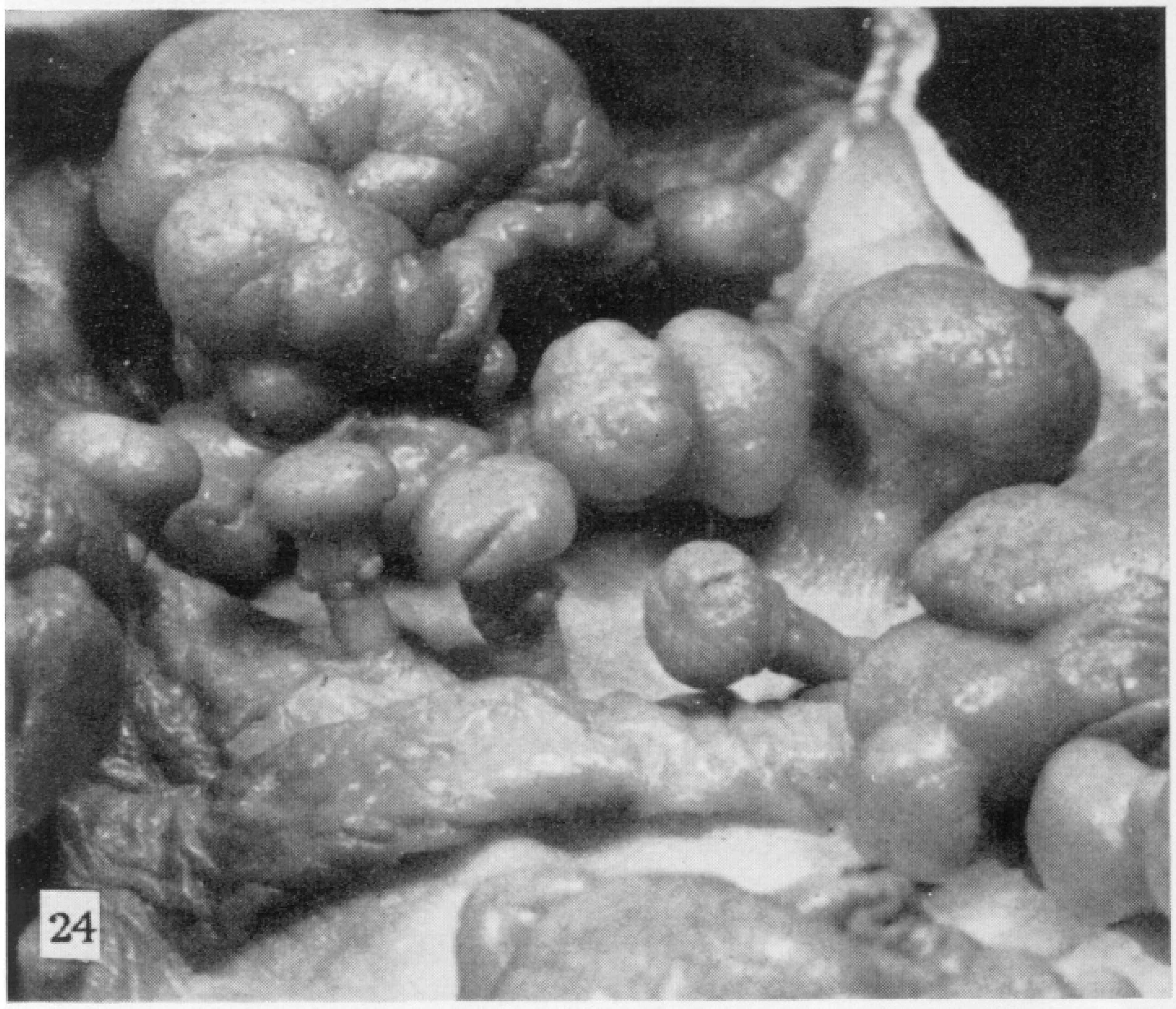

24



25

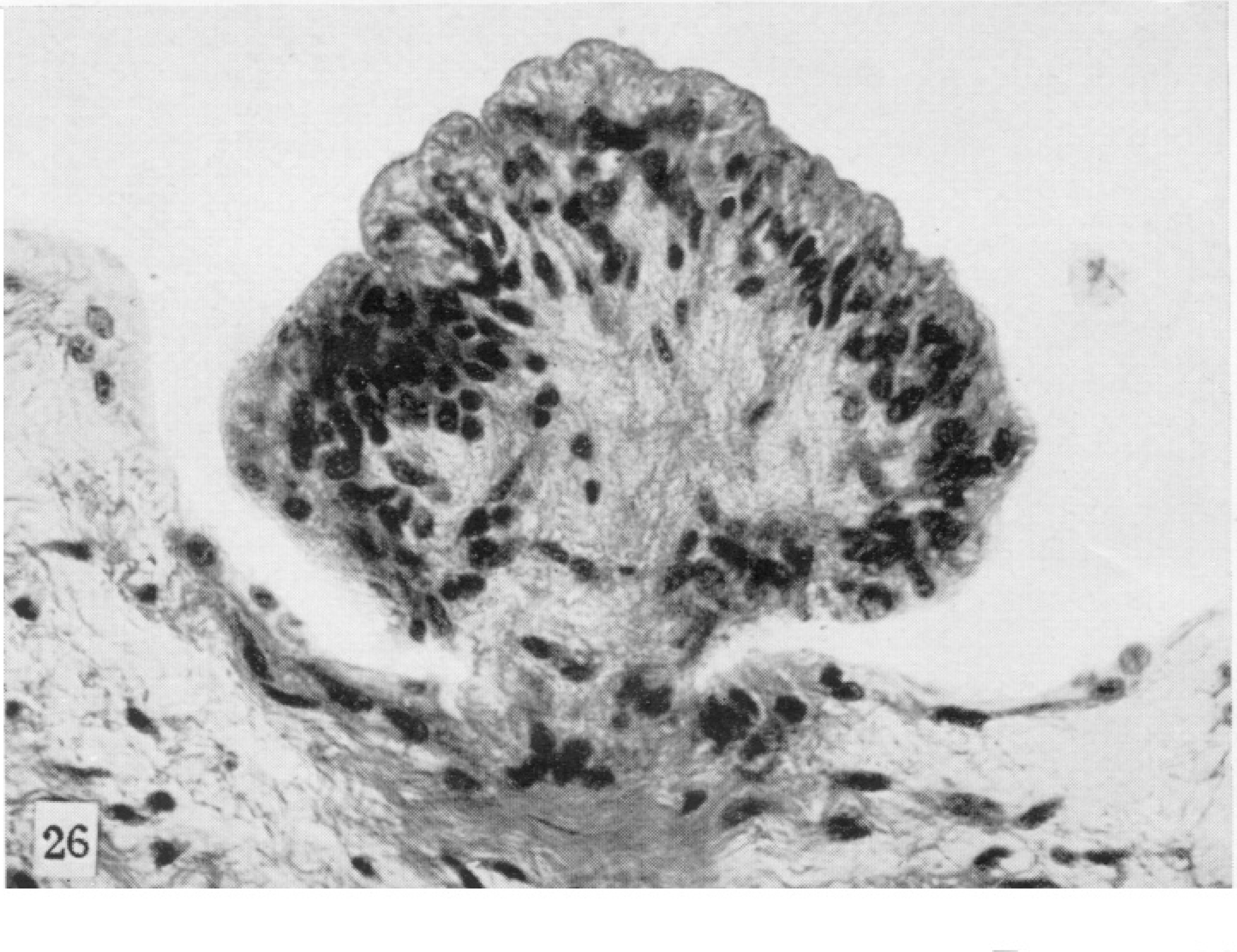

26

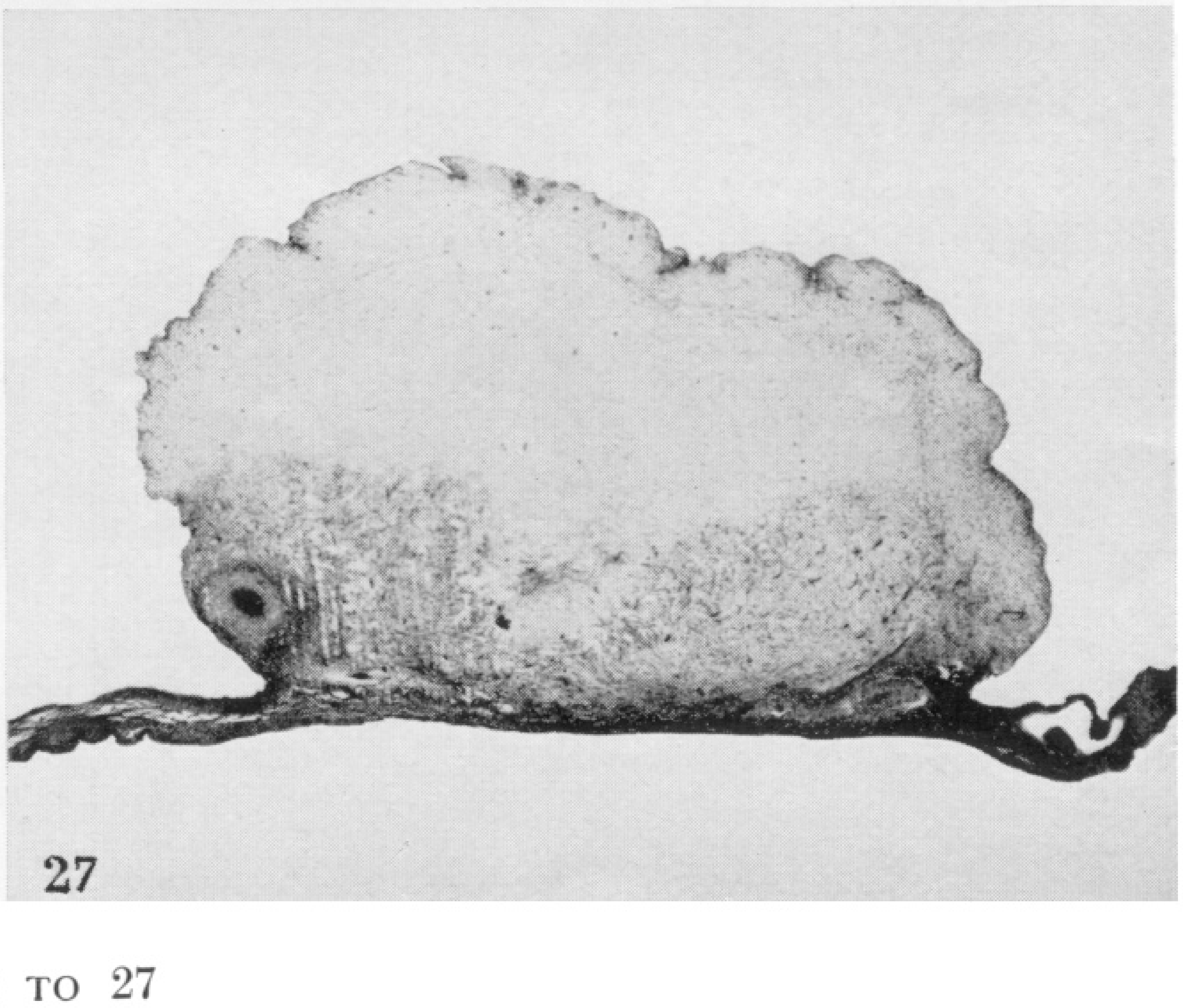

27

Figures 22 to 27

28

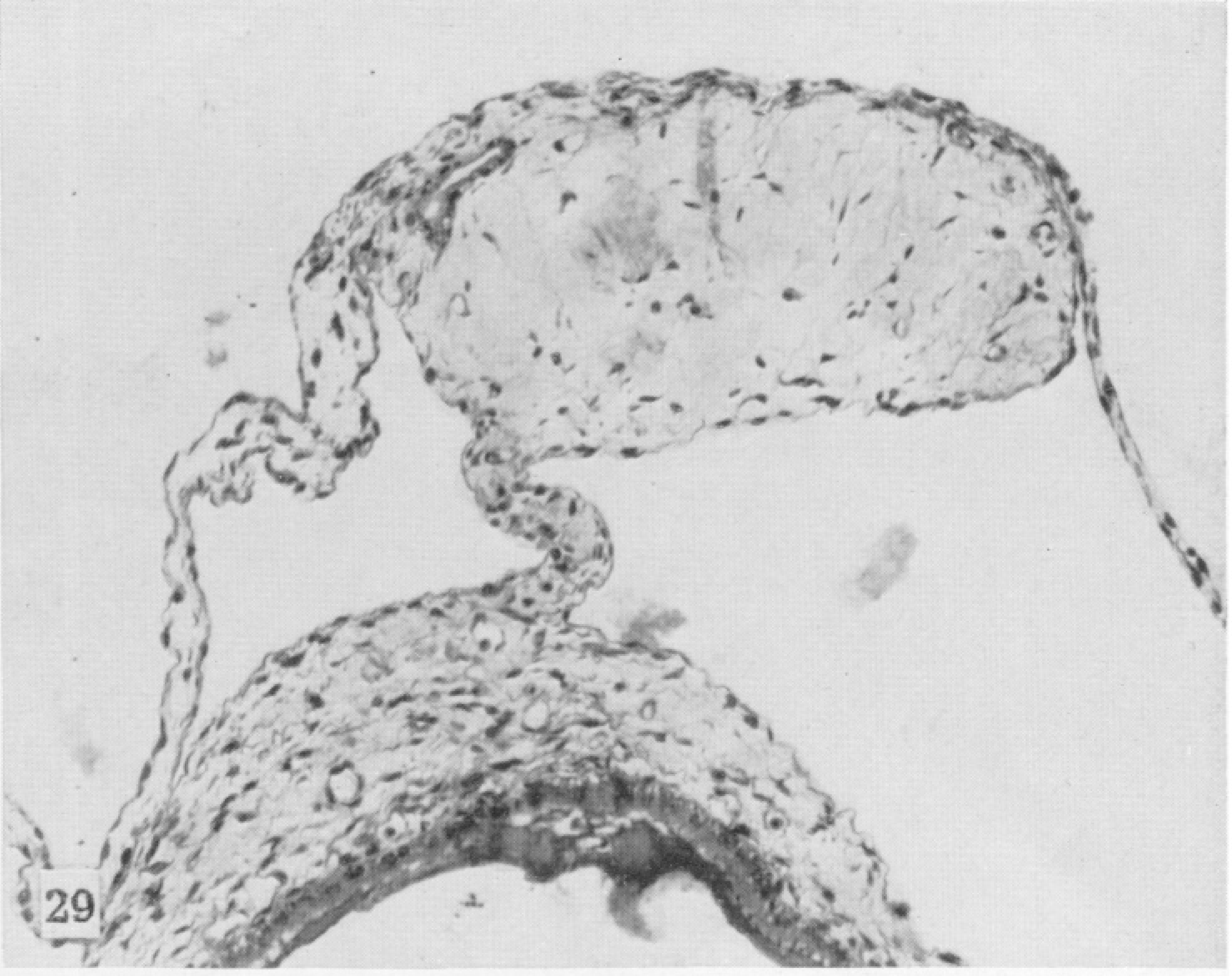

29

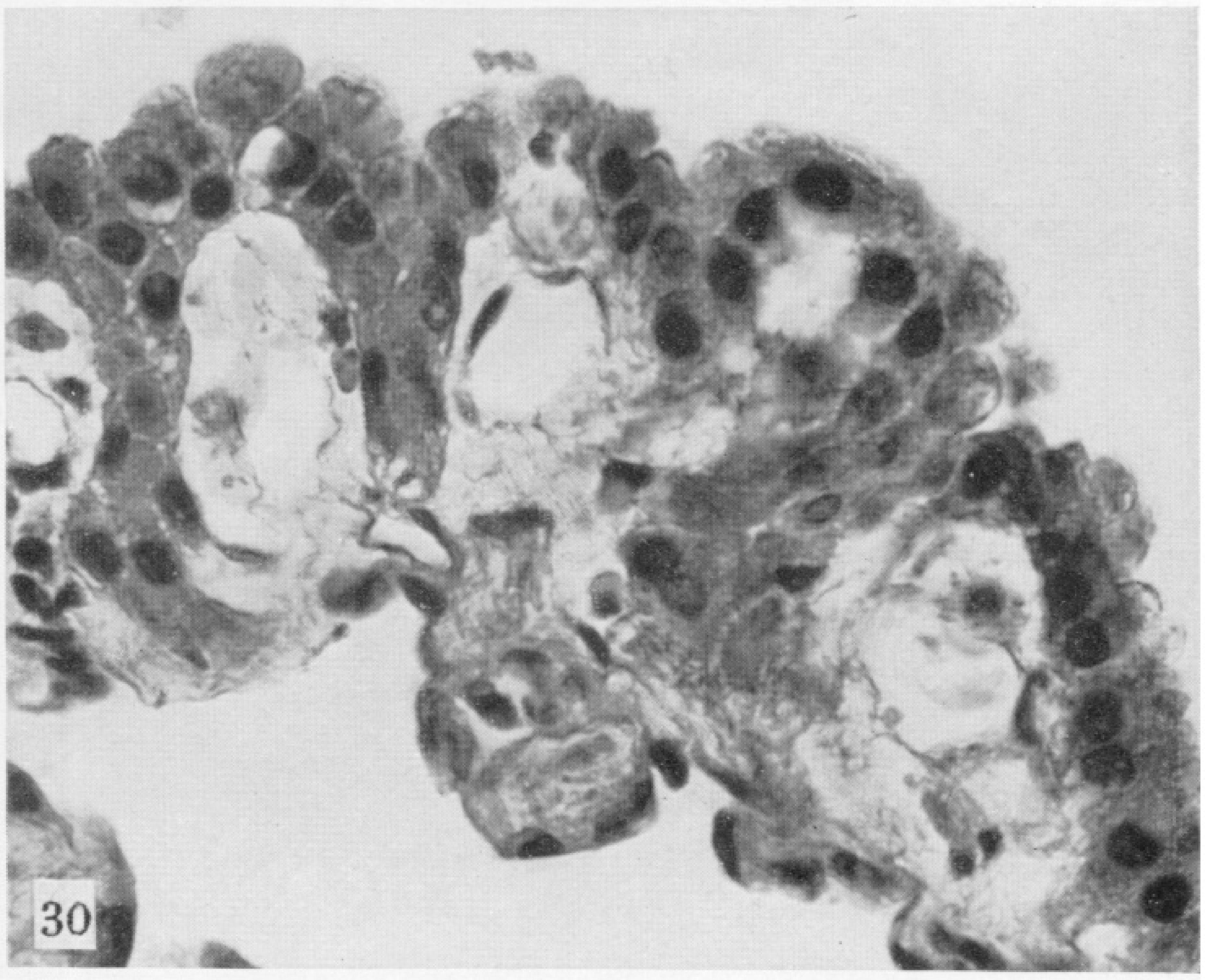

30

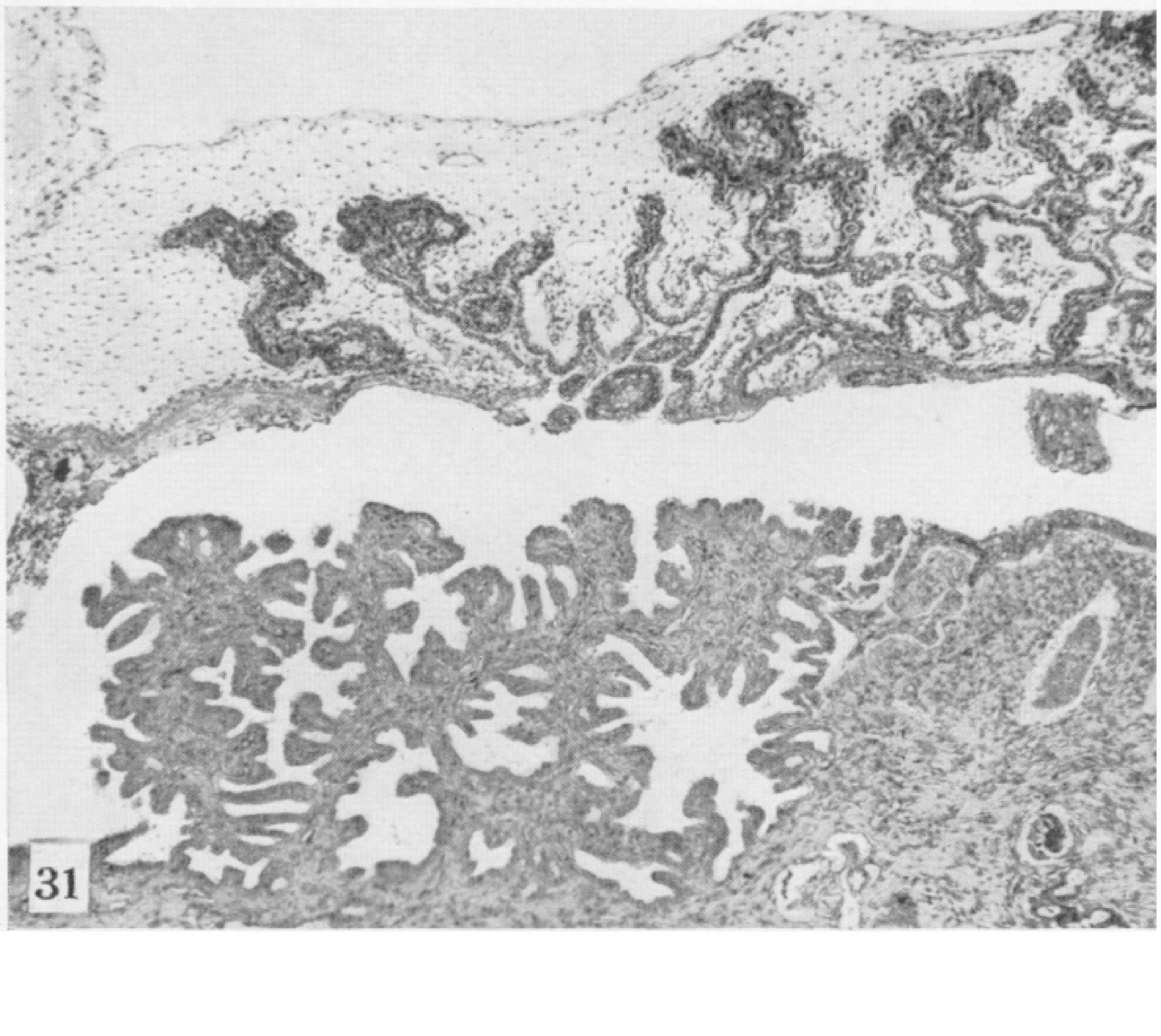

31

FIGURES 28 TO 31

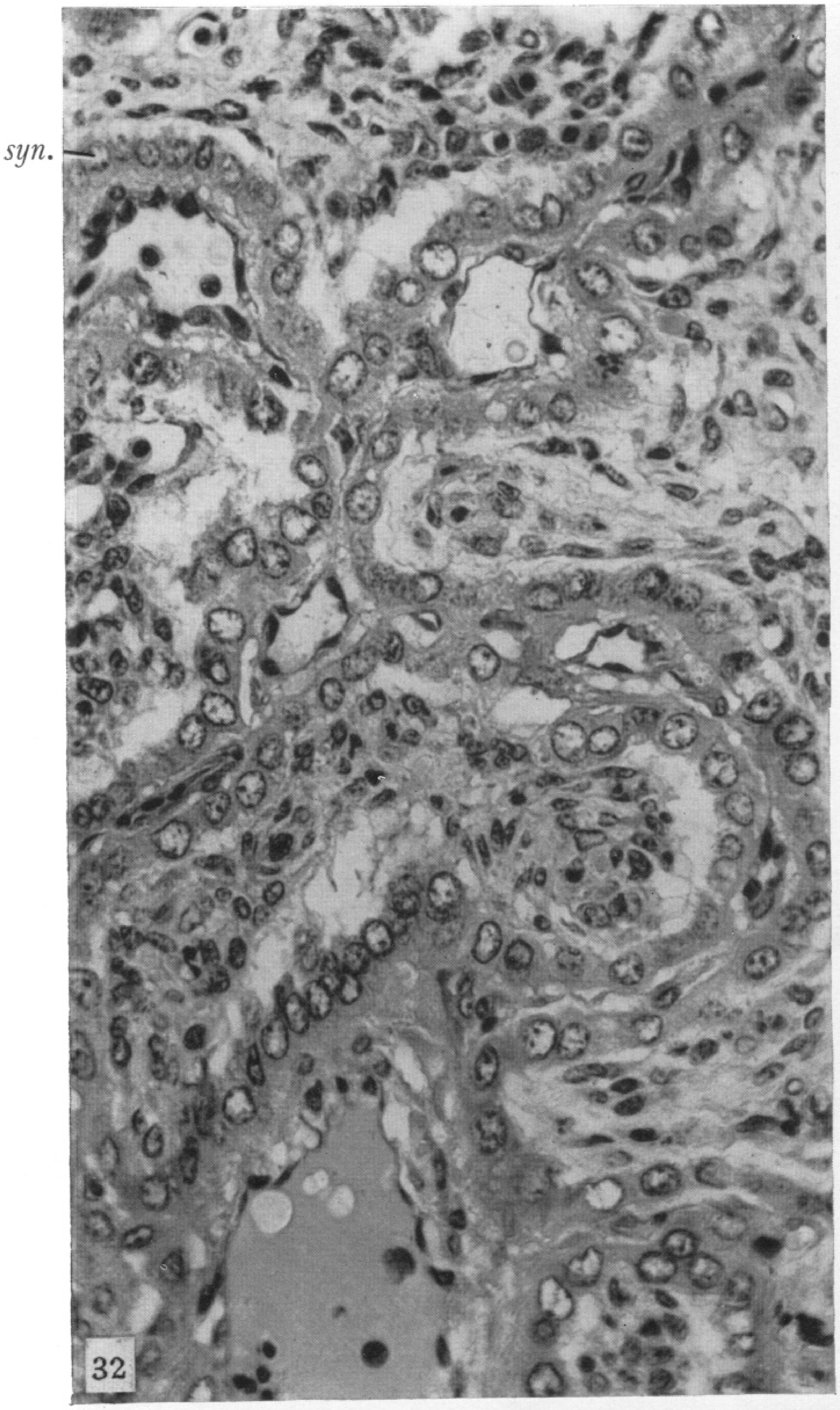

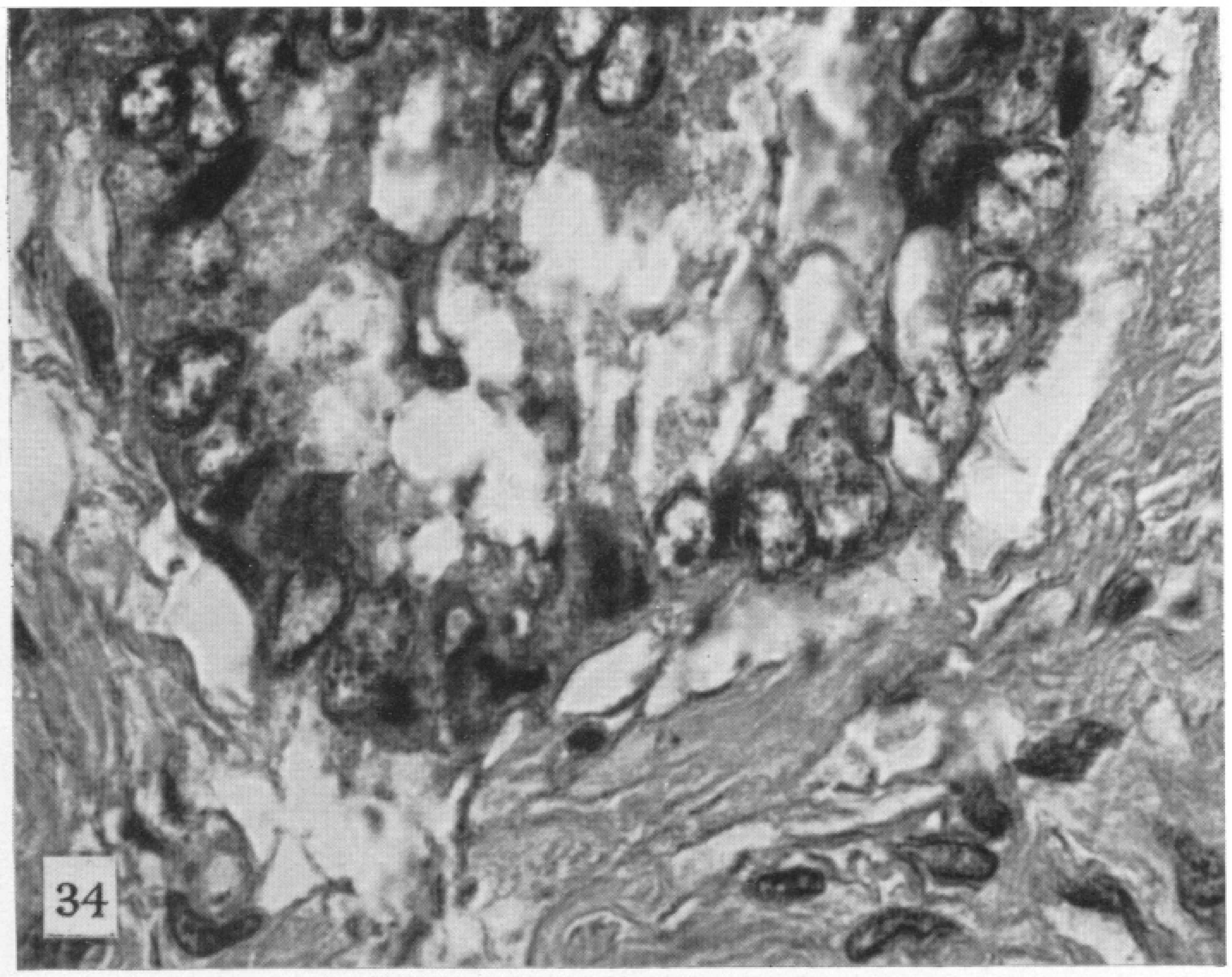

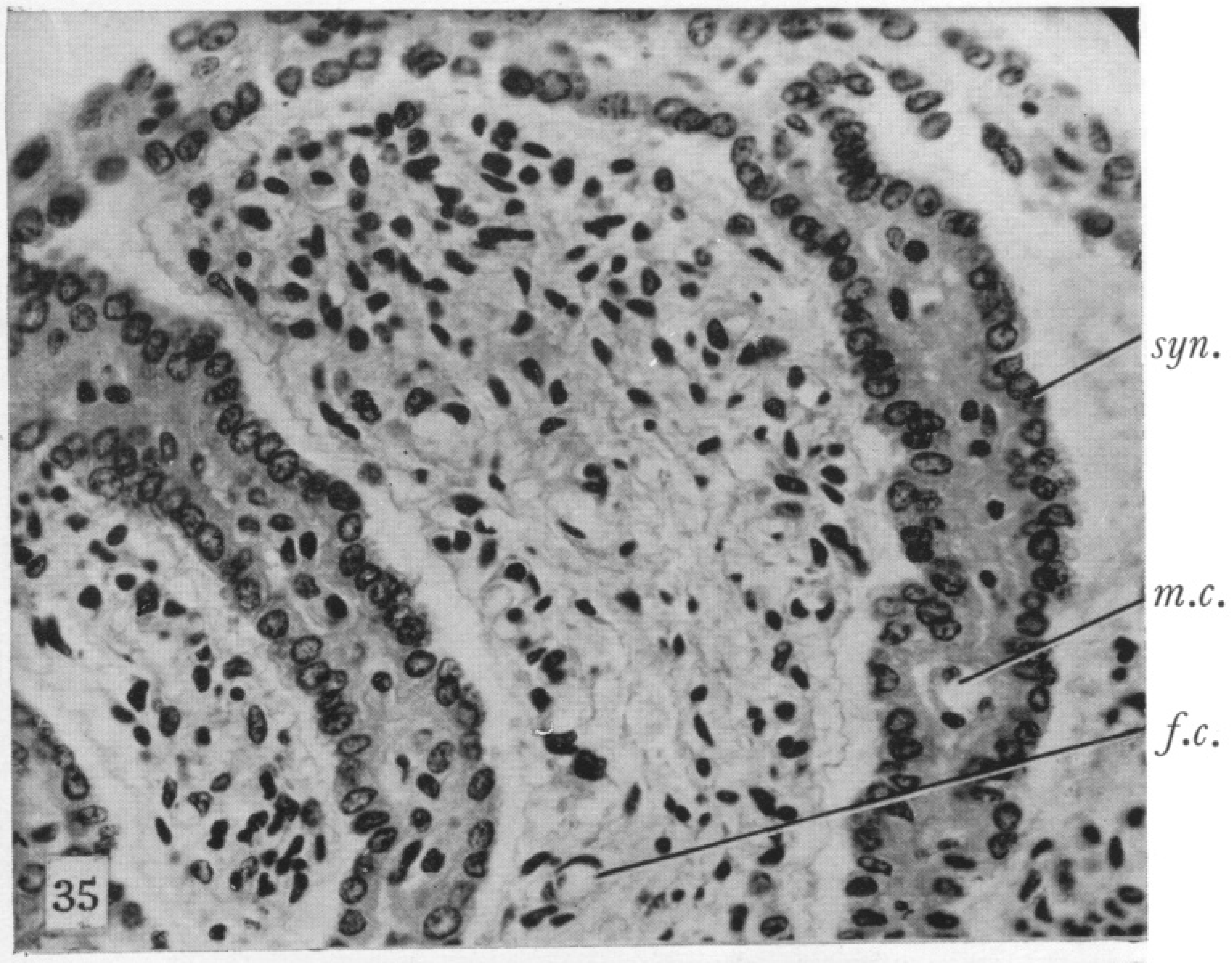

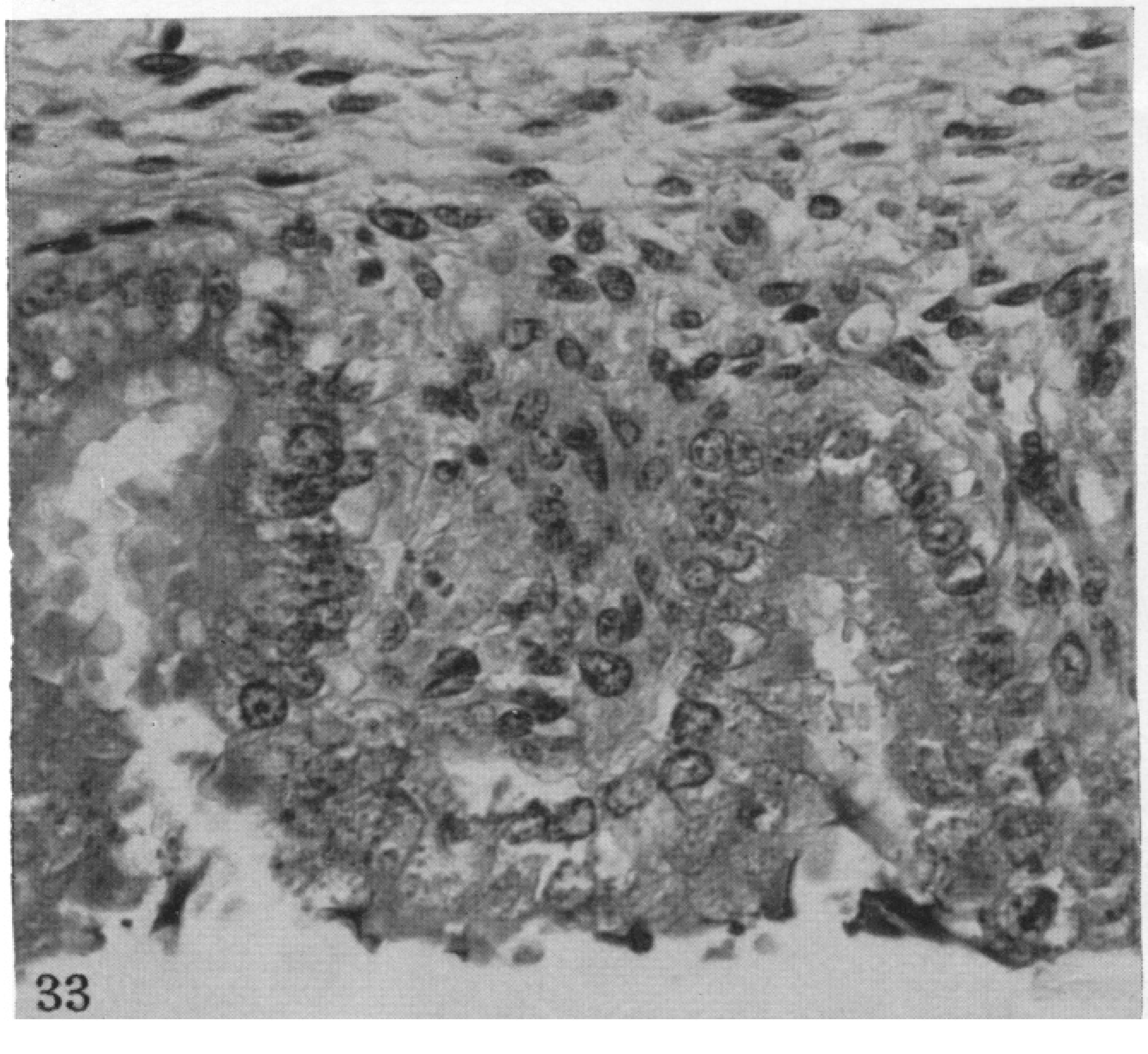

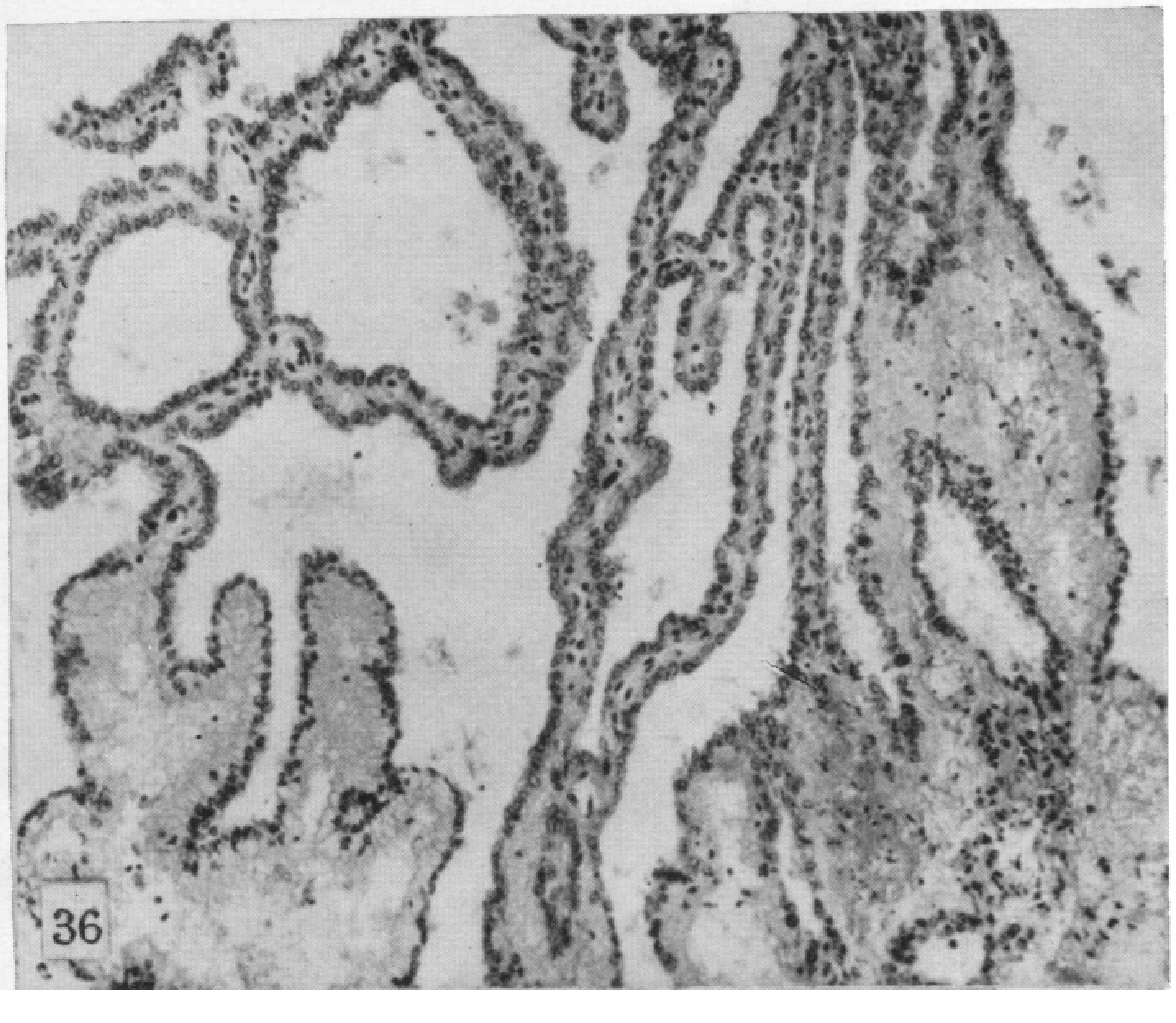

Figures 32 to 36

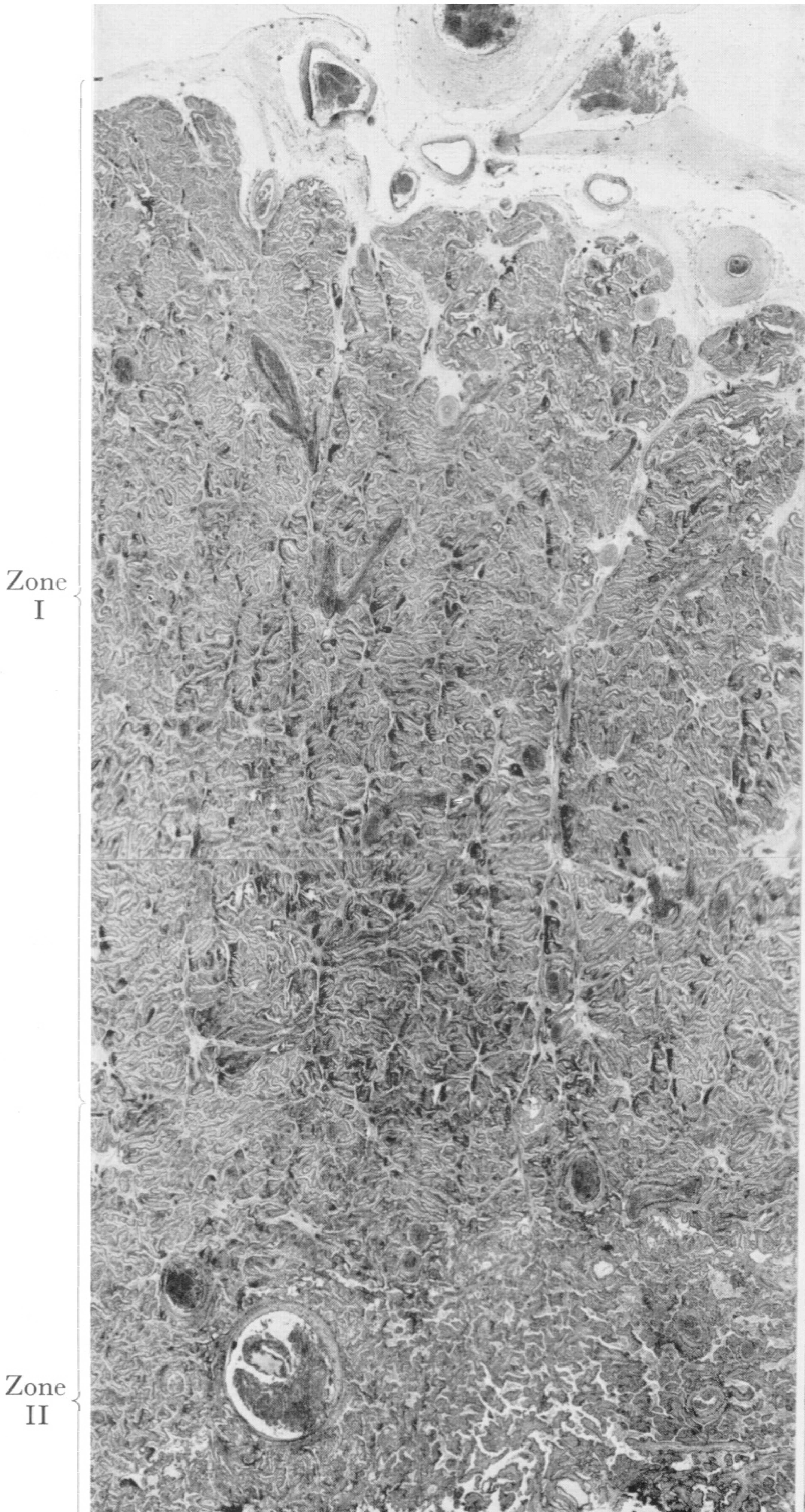

37

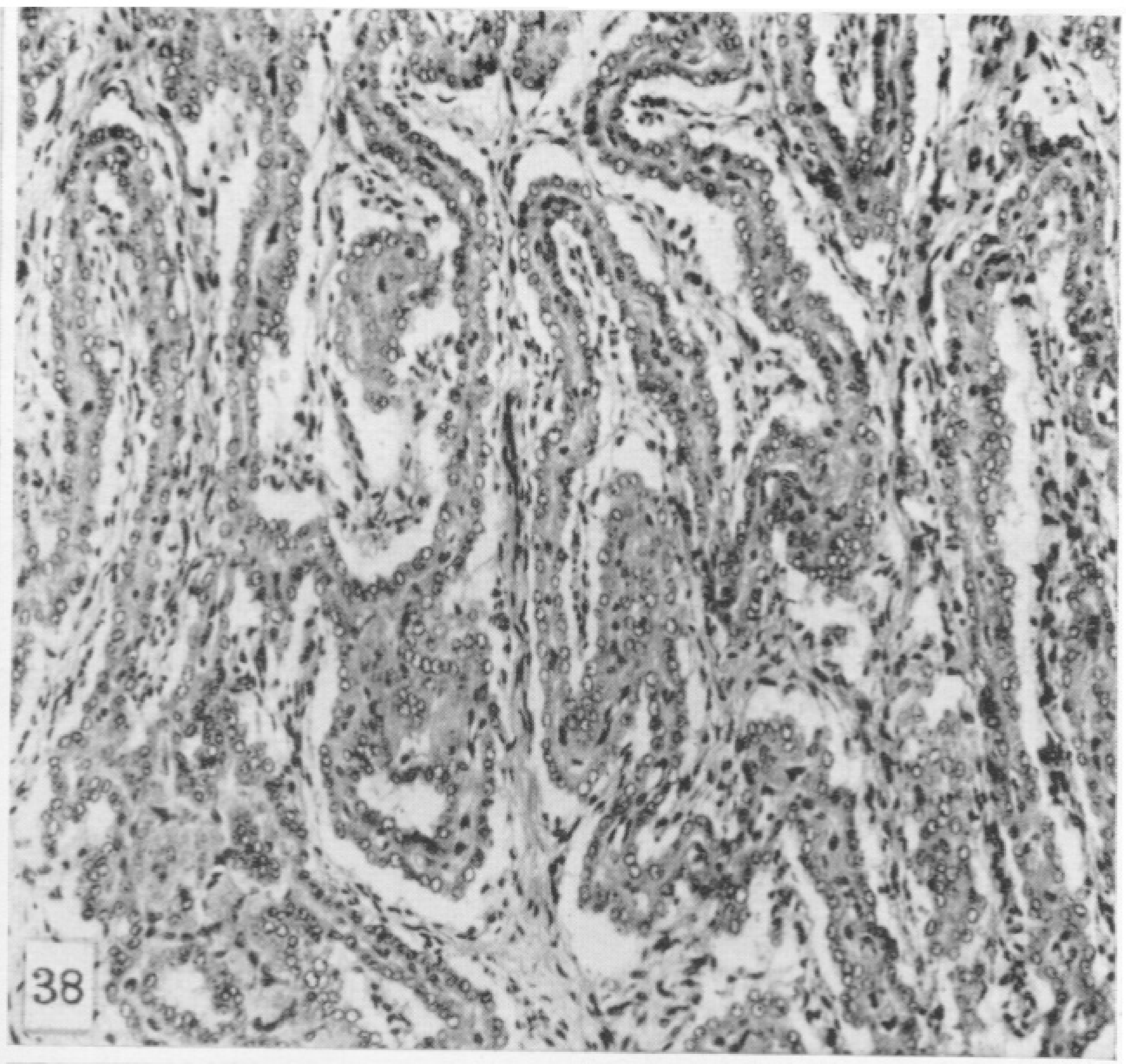

38

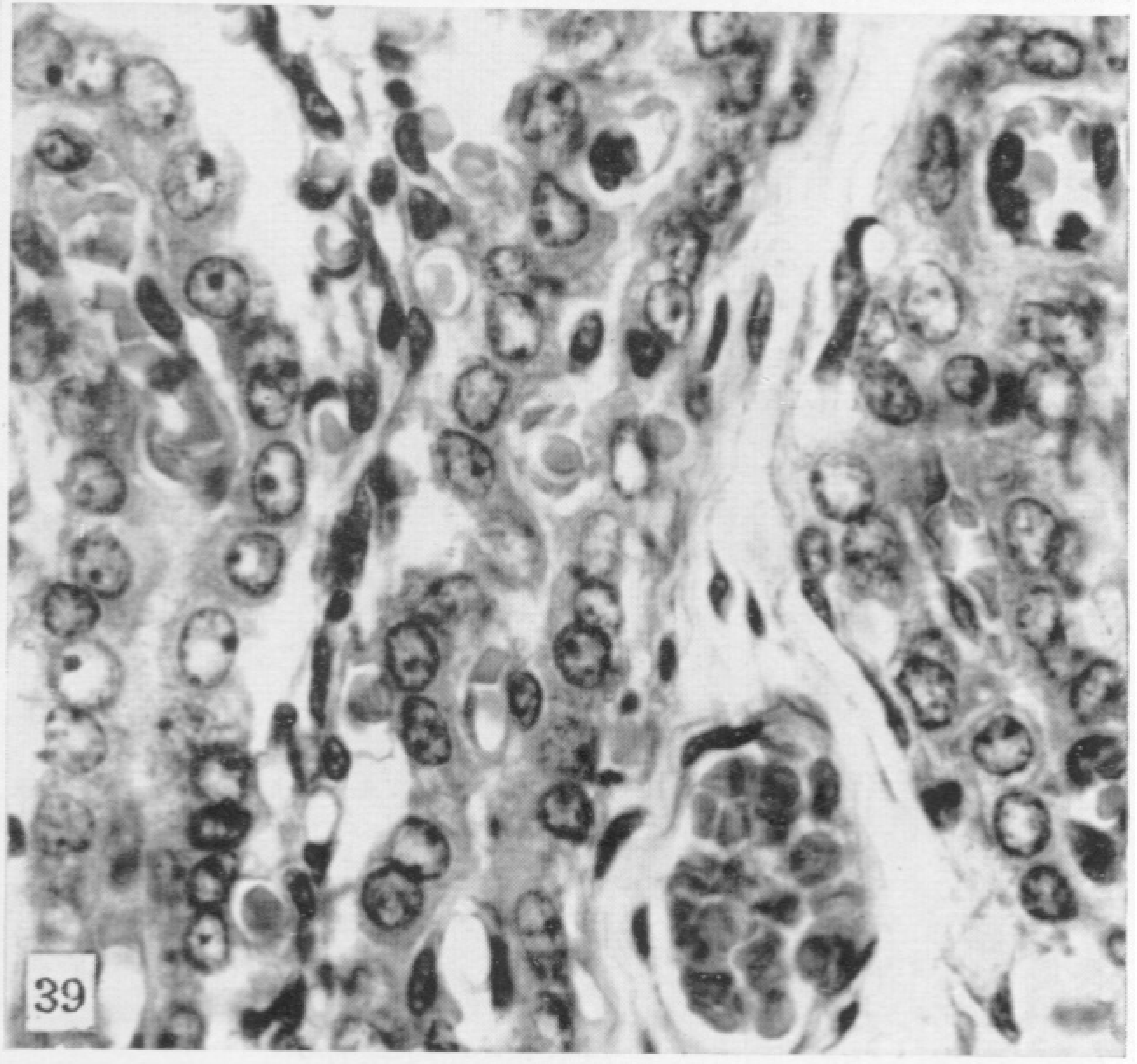

39

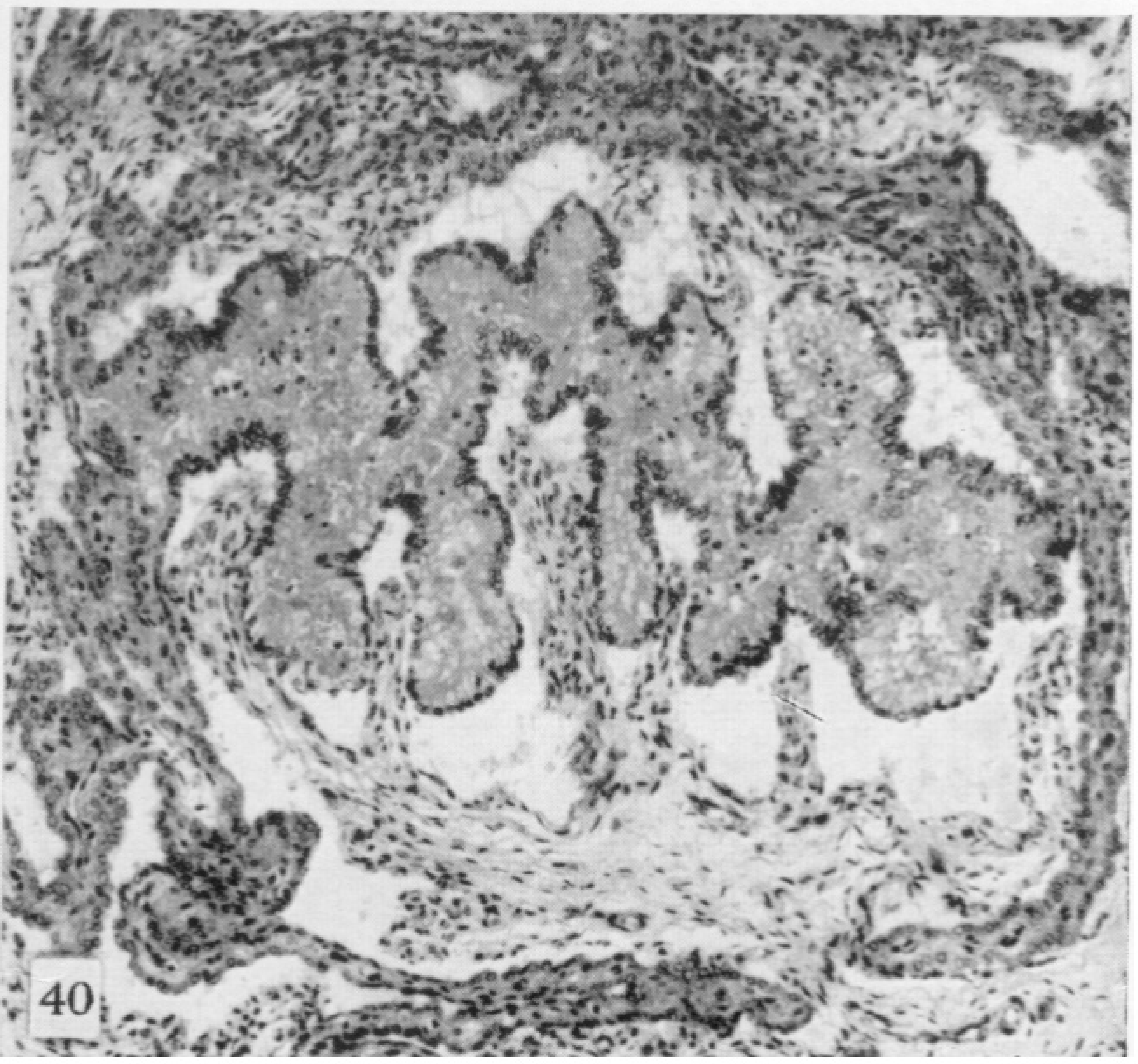

40

FIGURES 37 TO 40

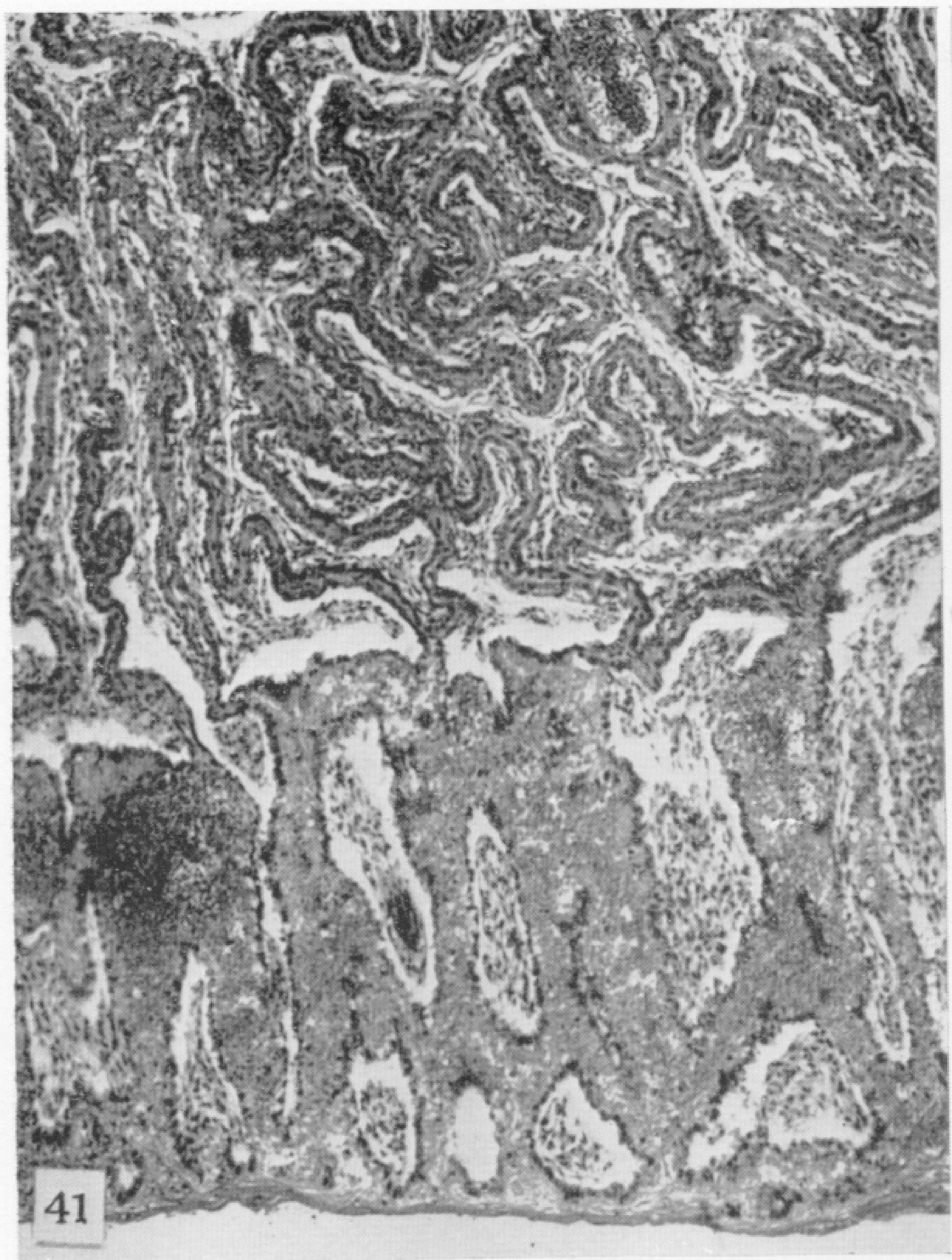
41

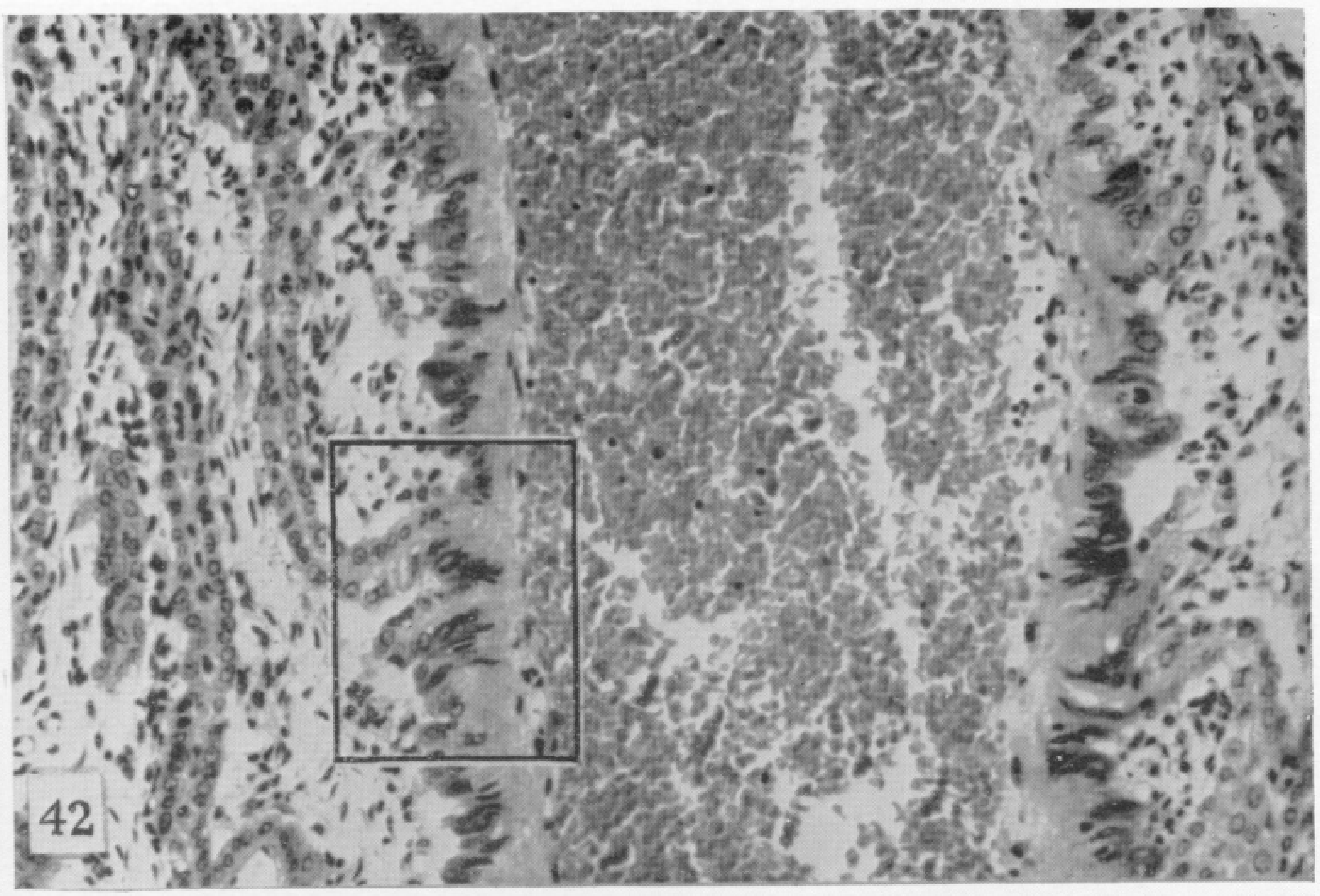
42

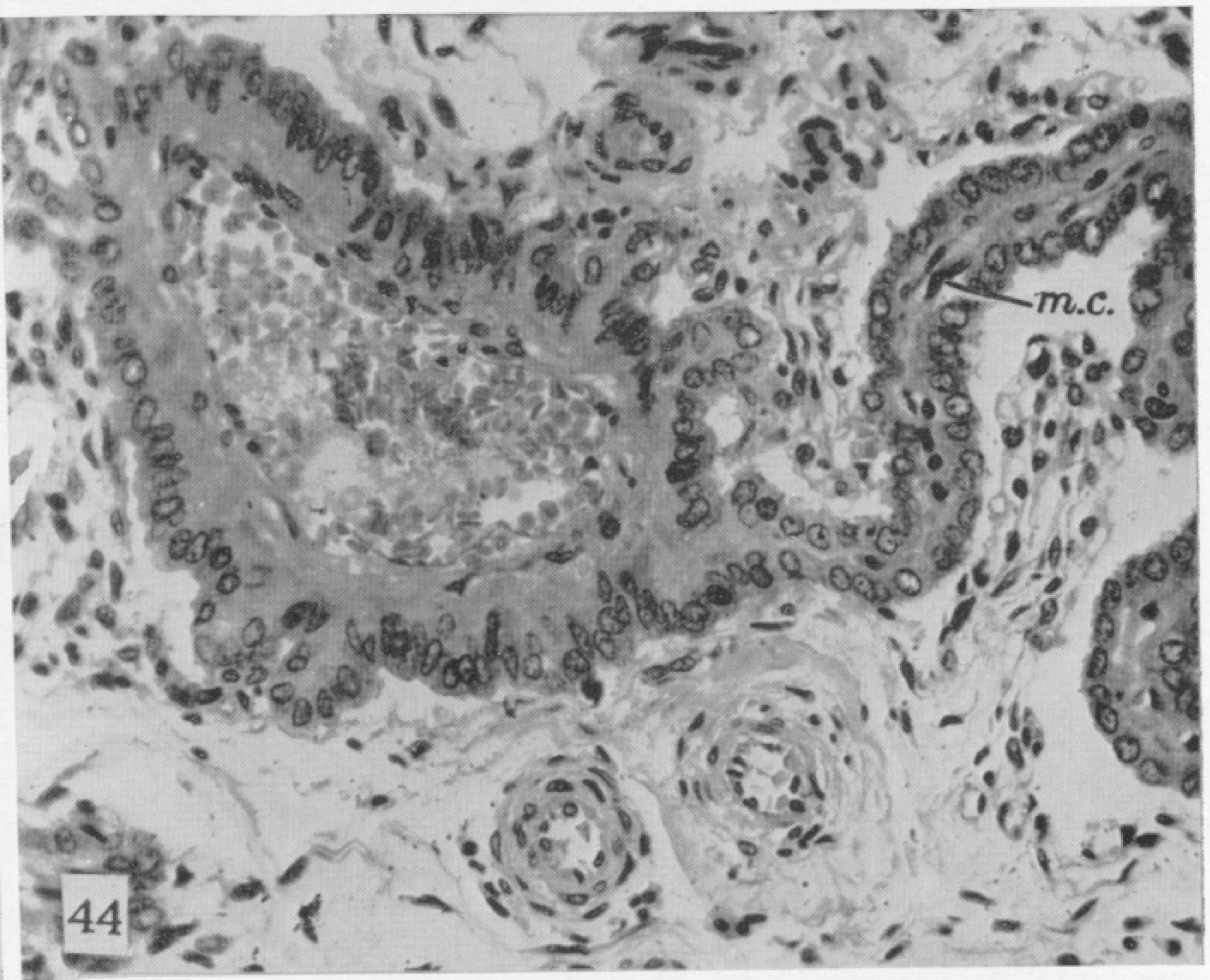

44

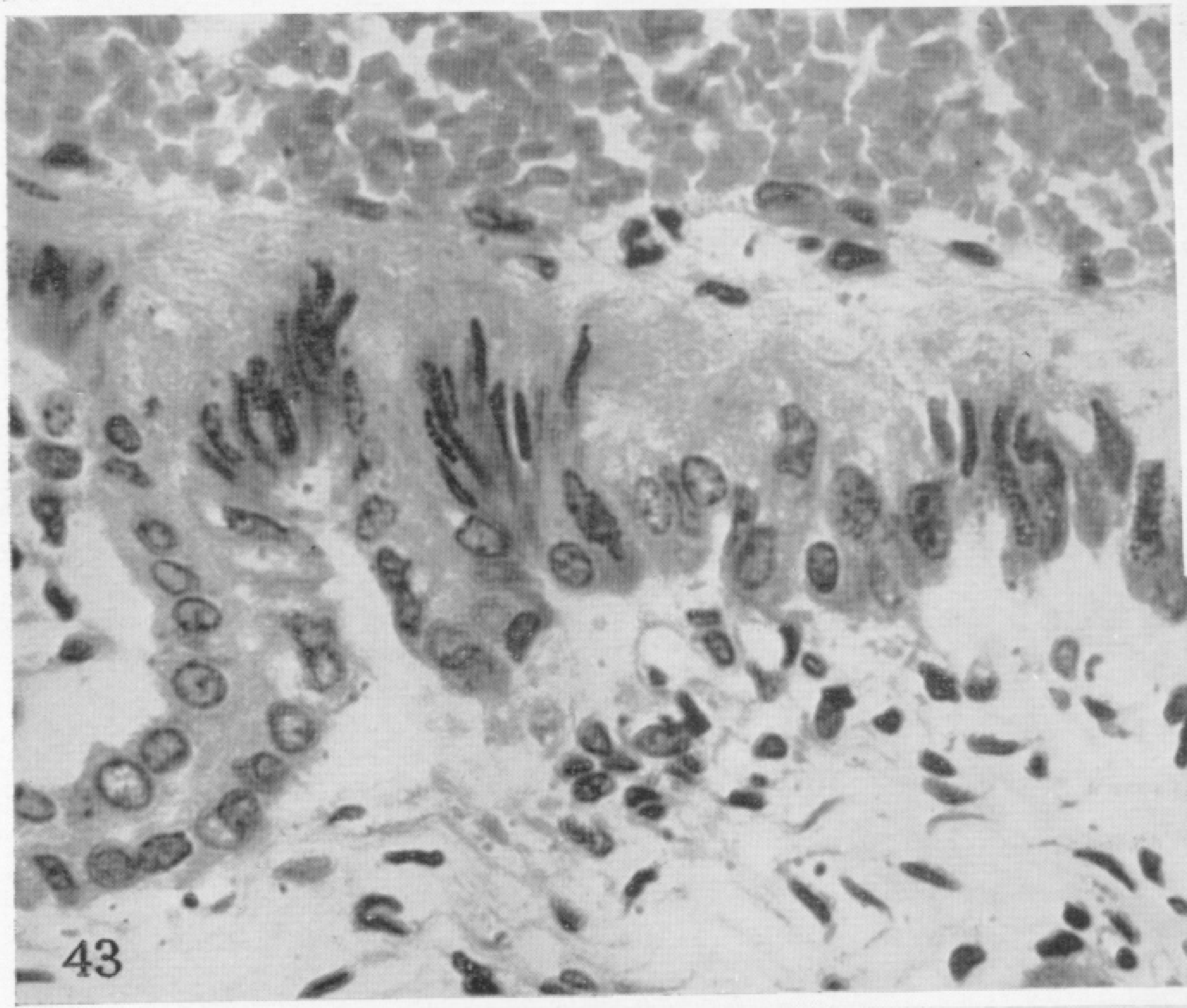
43

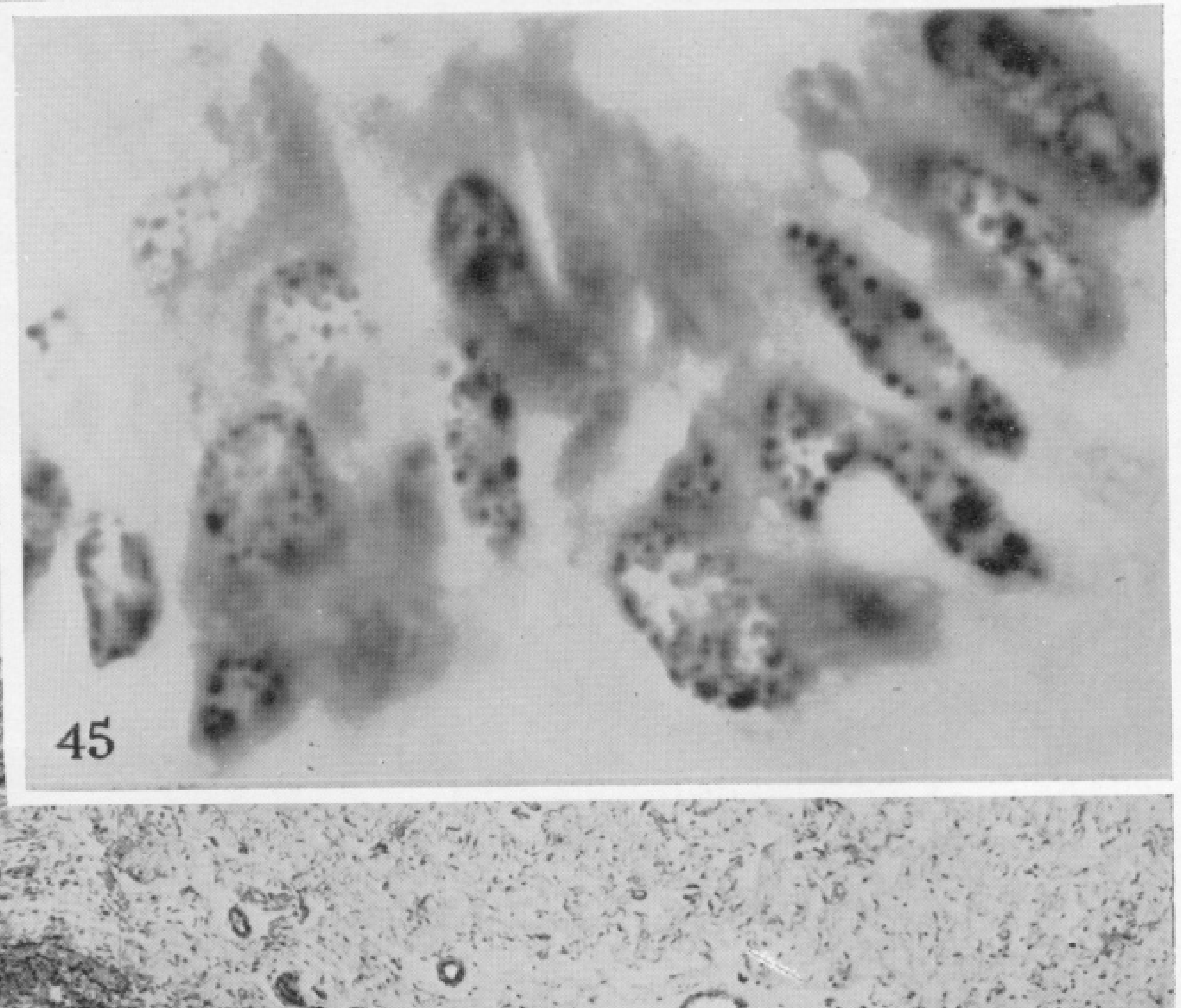
45

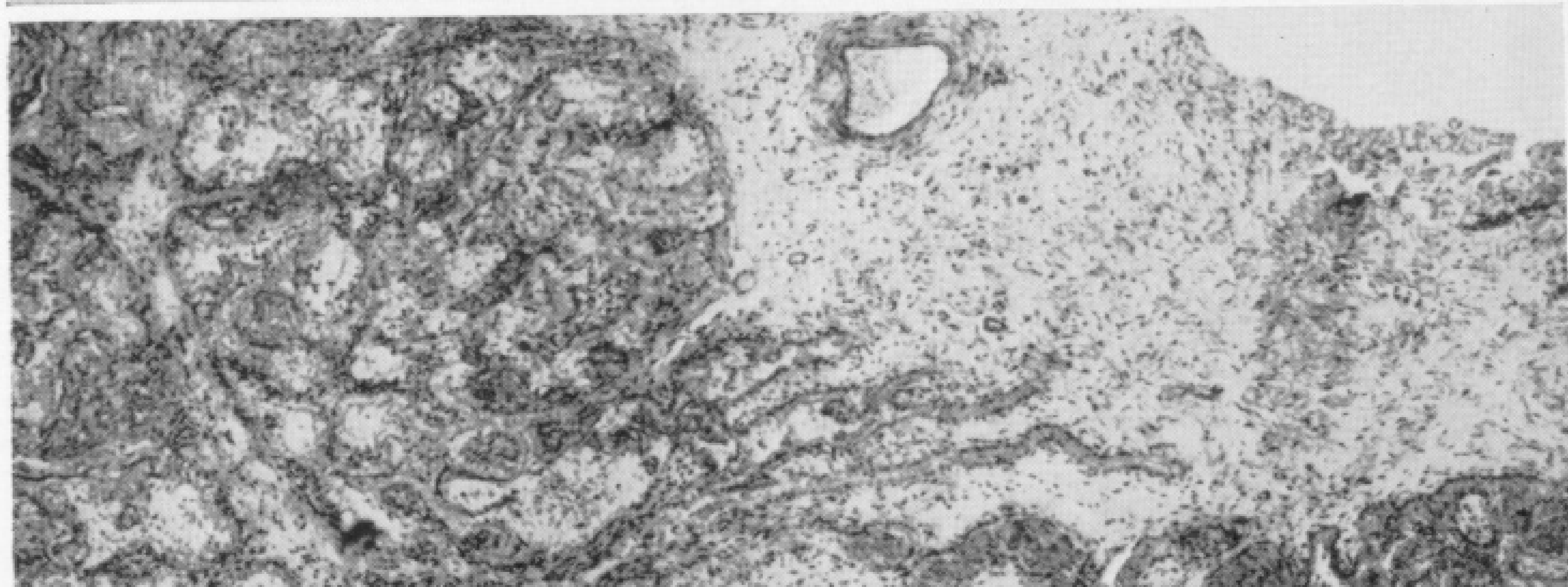
46

FIGURES 41 TO 46

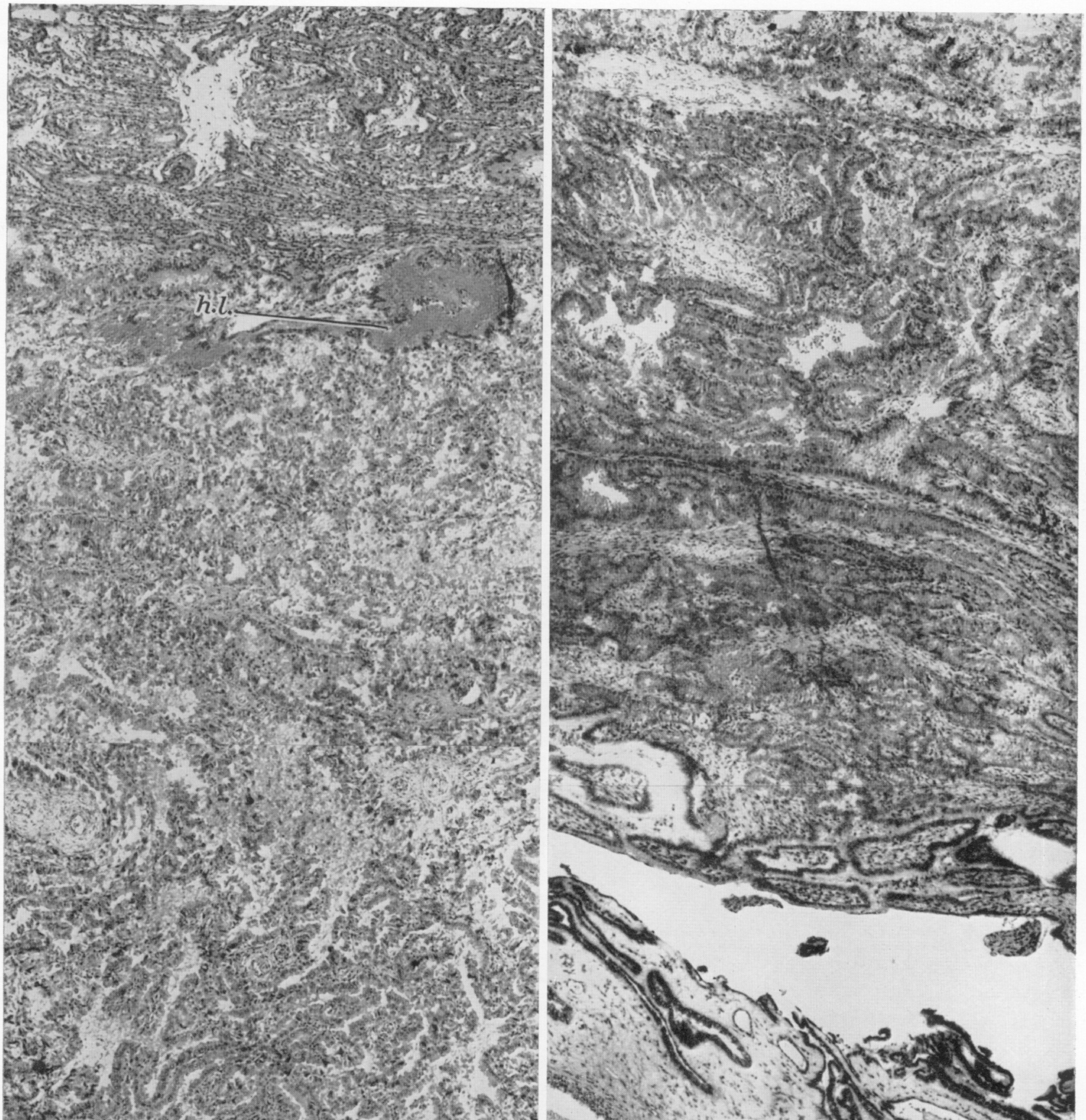

FIGURE 47

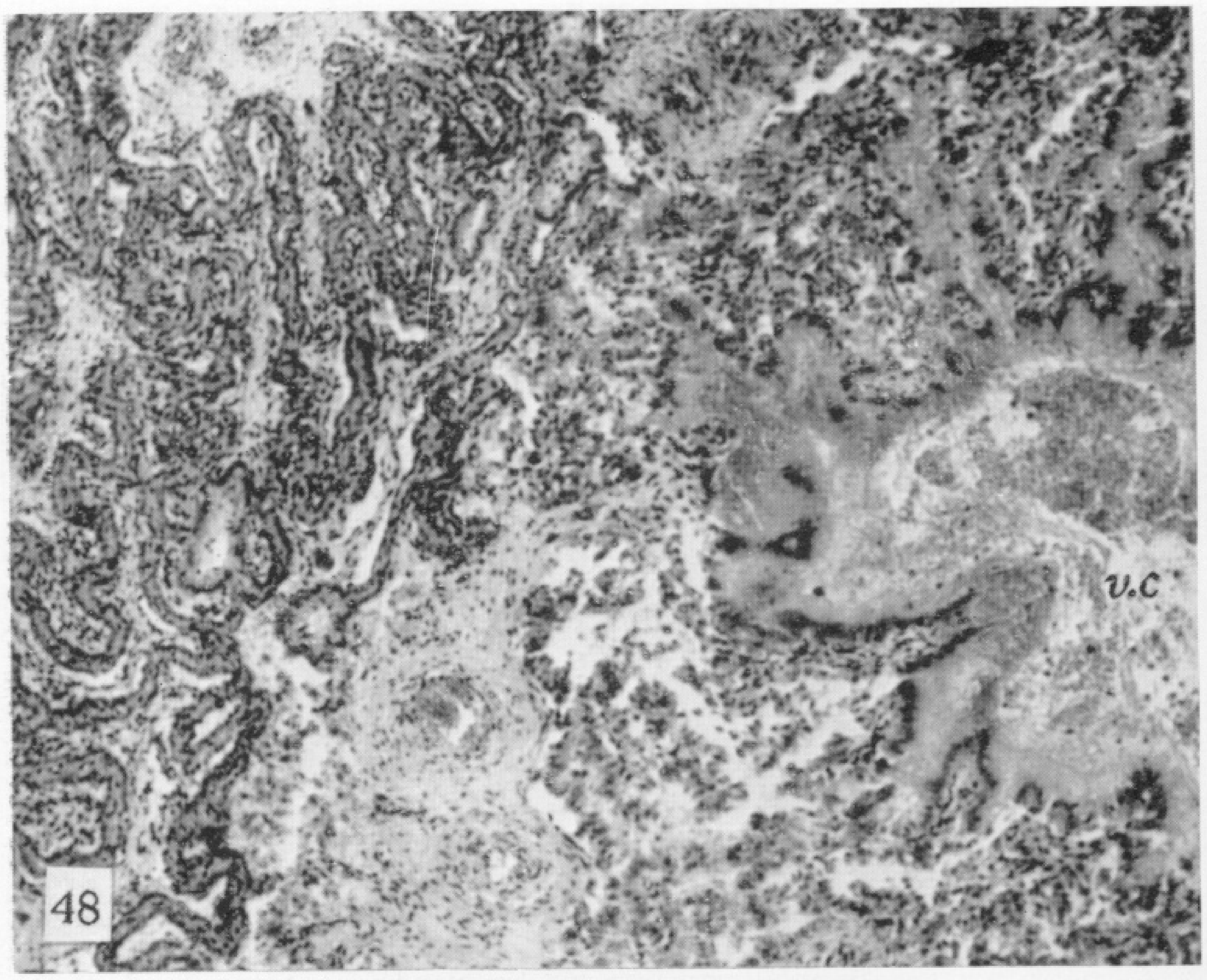

48

49

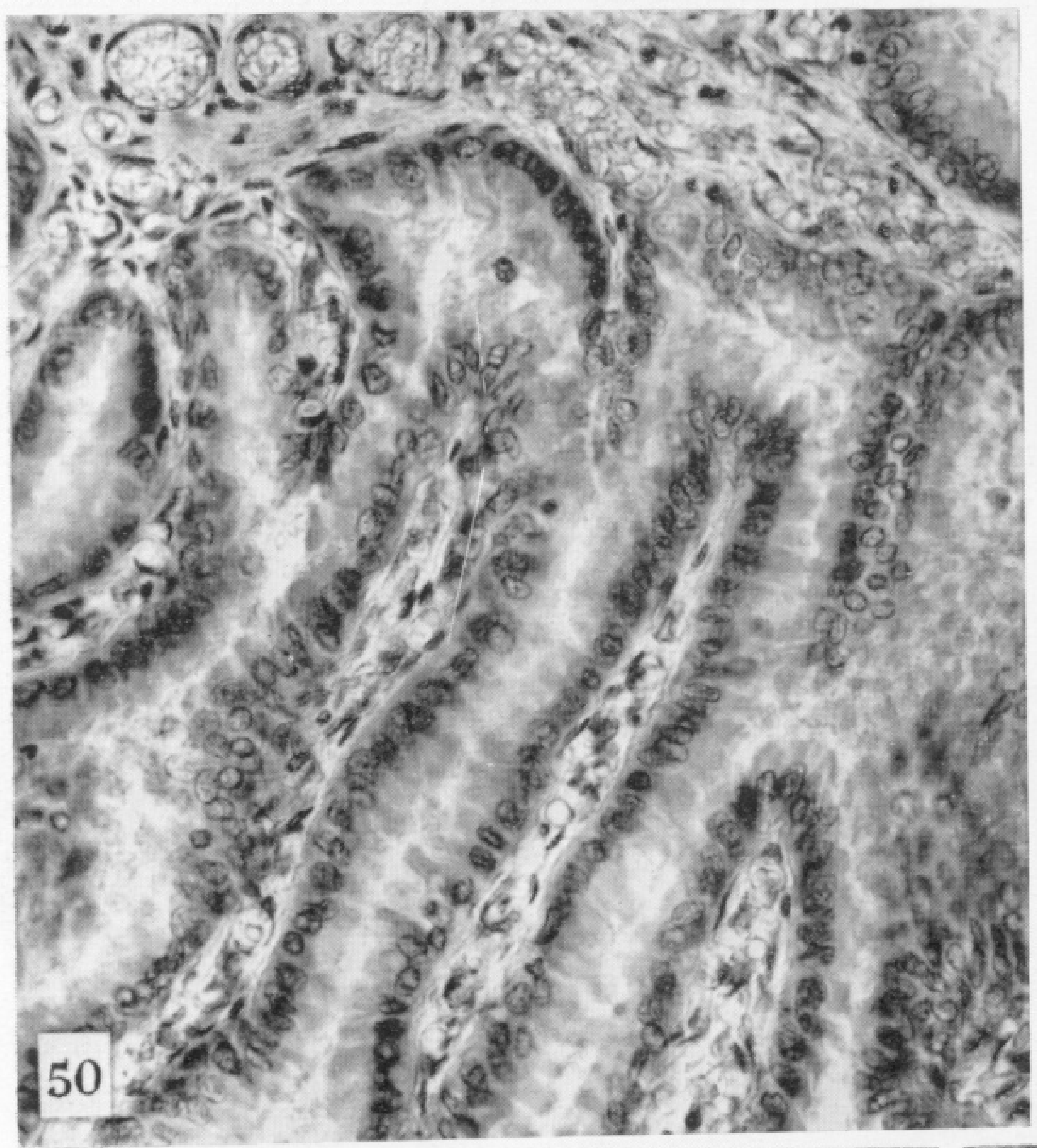

50

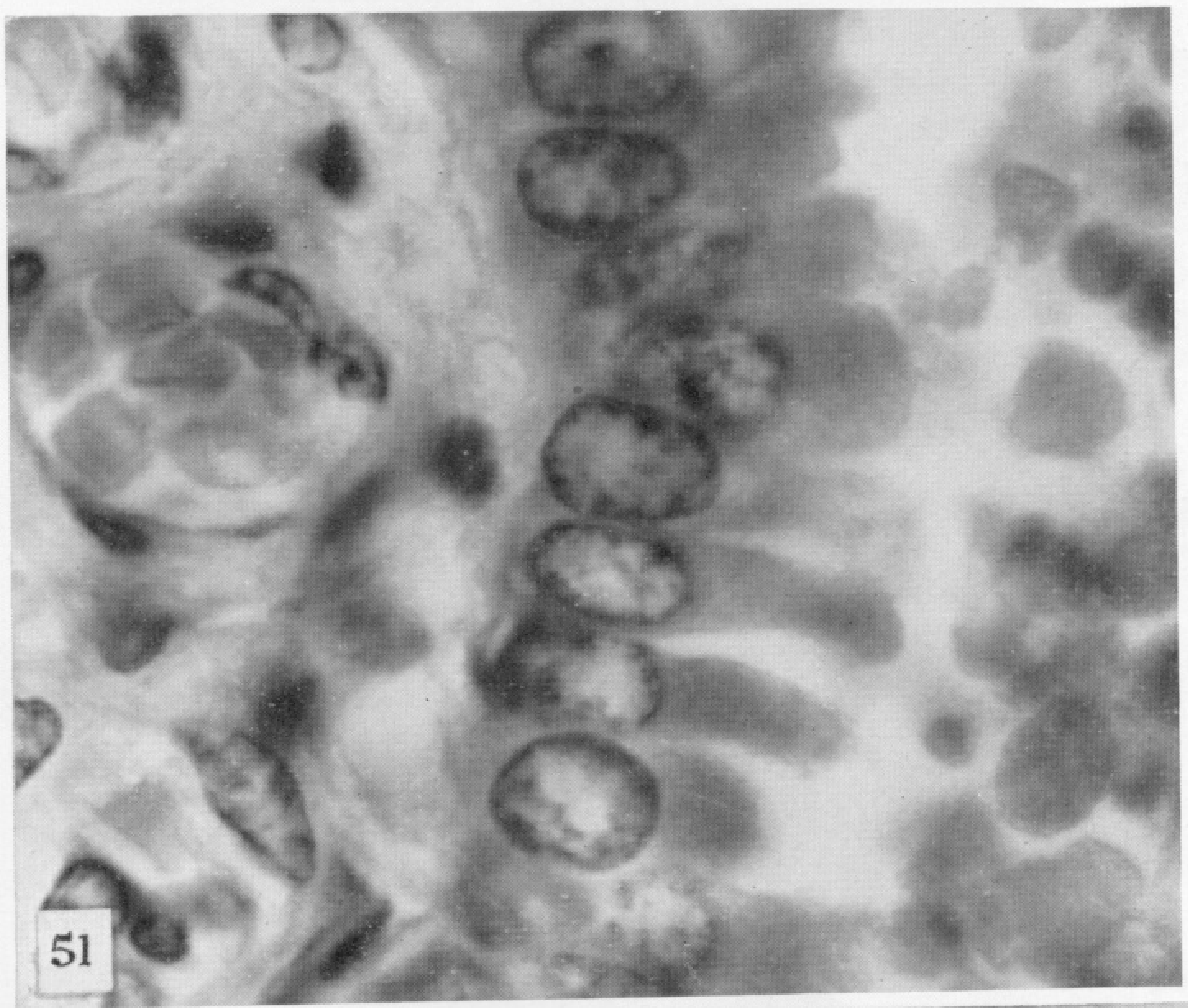

51

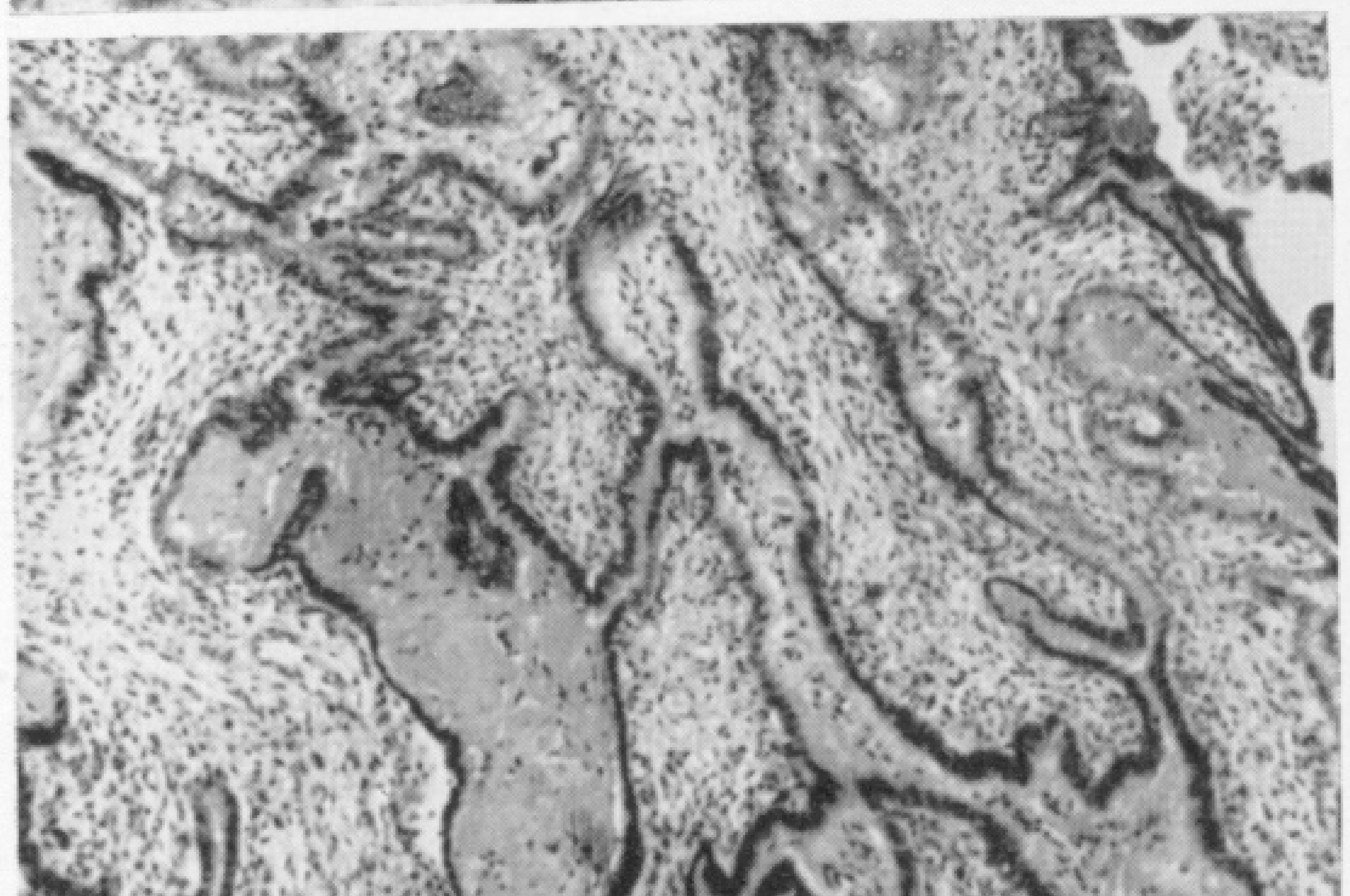

52

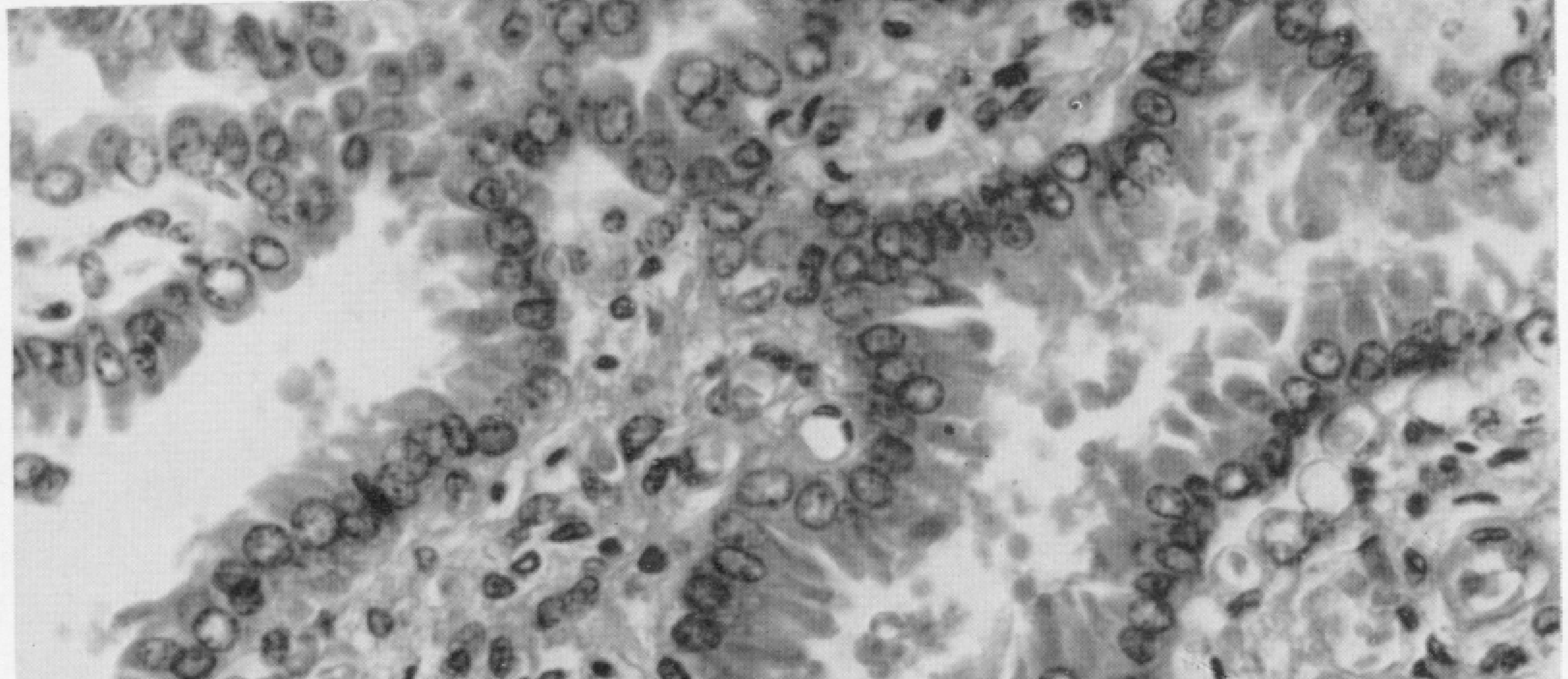

53

Figures 48 to 53

54

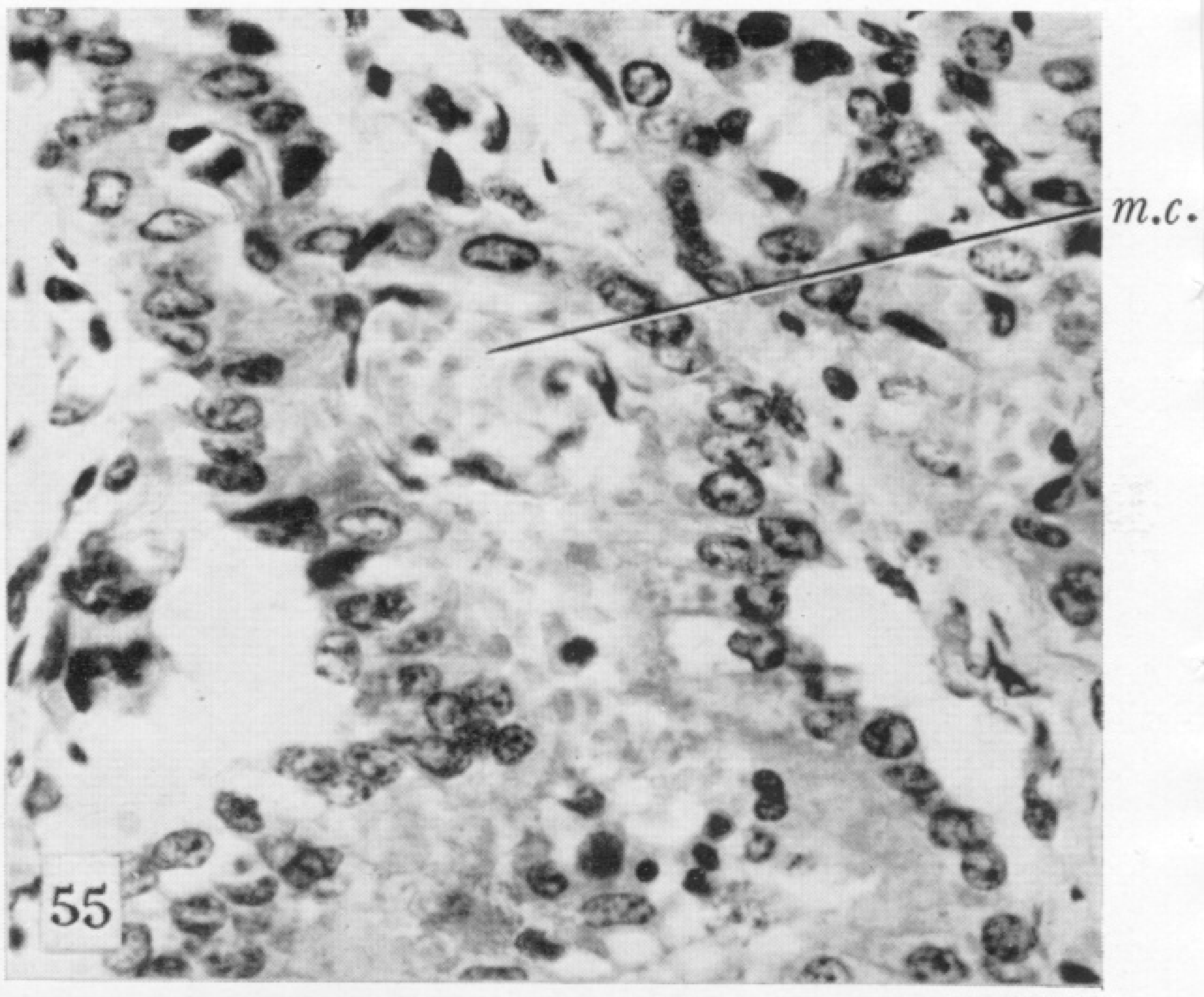

55

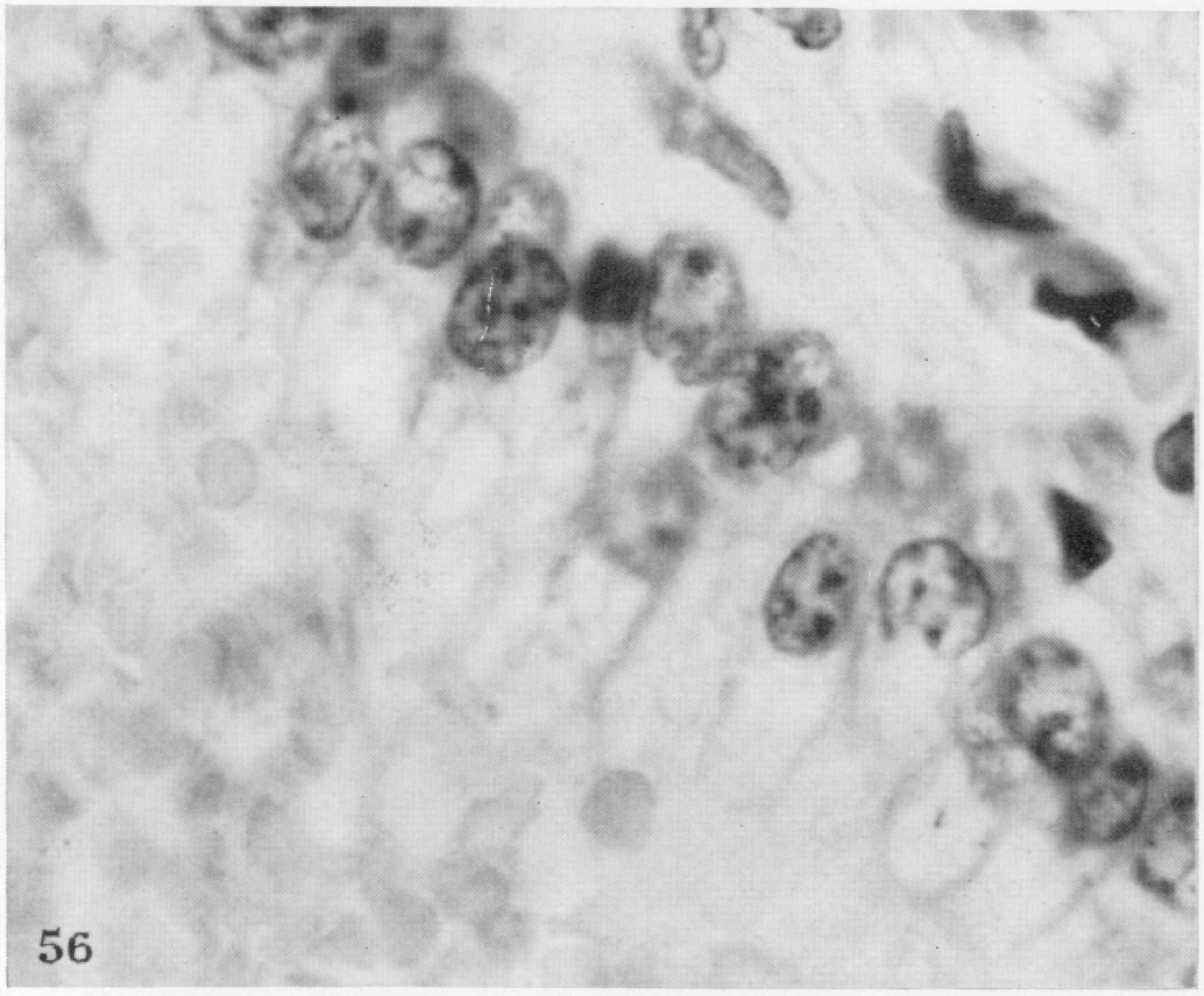

56

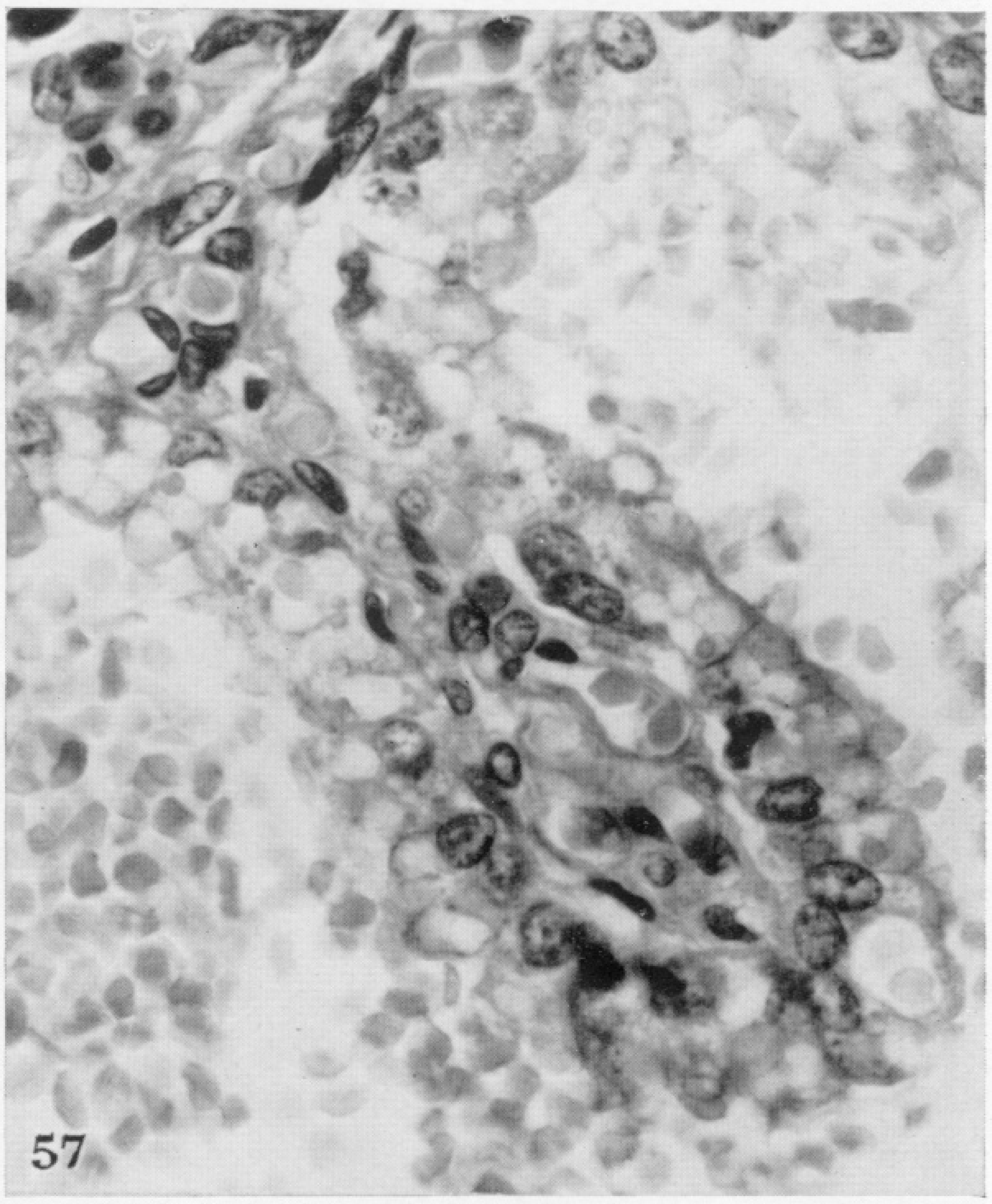

57

58

59

Figures 54 to 59

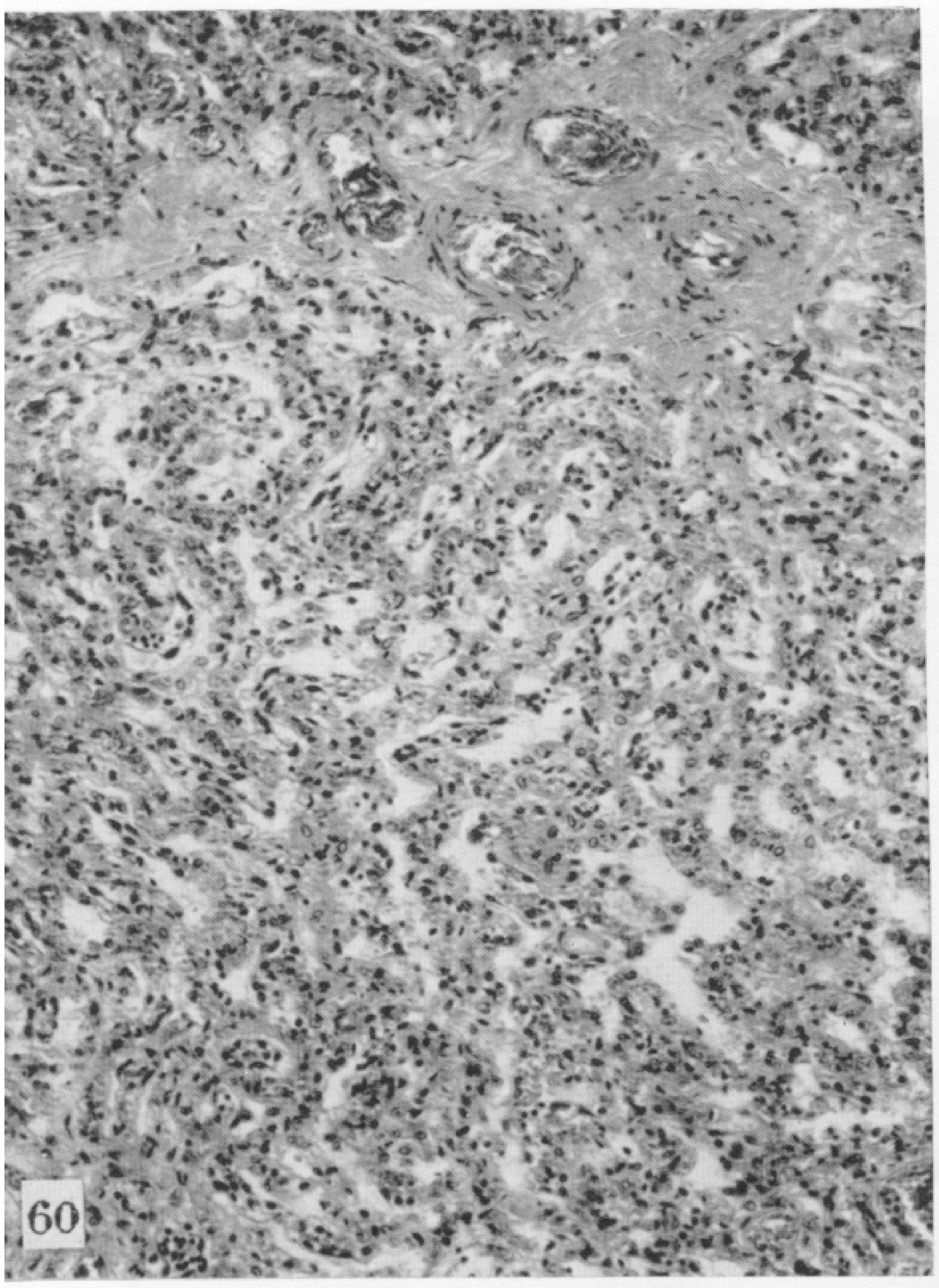

60



62

63

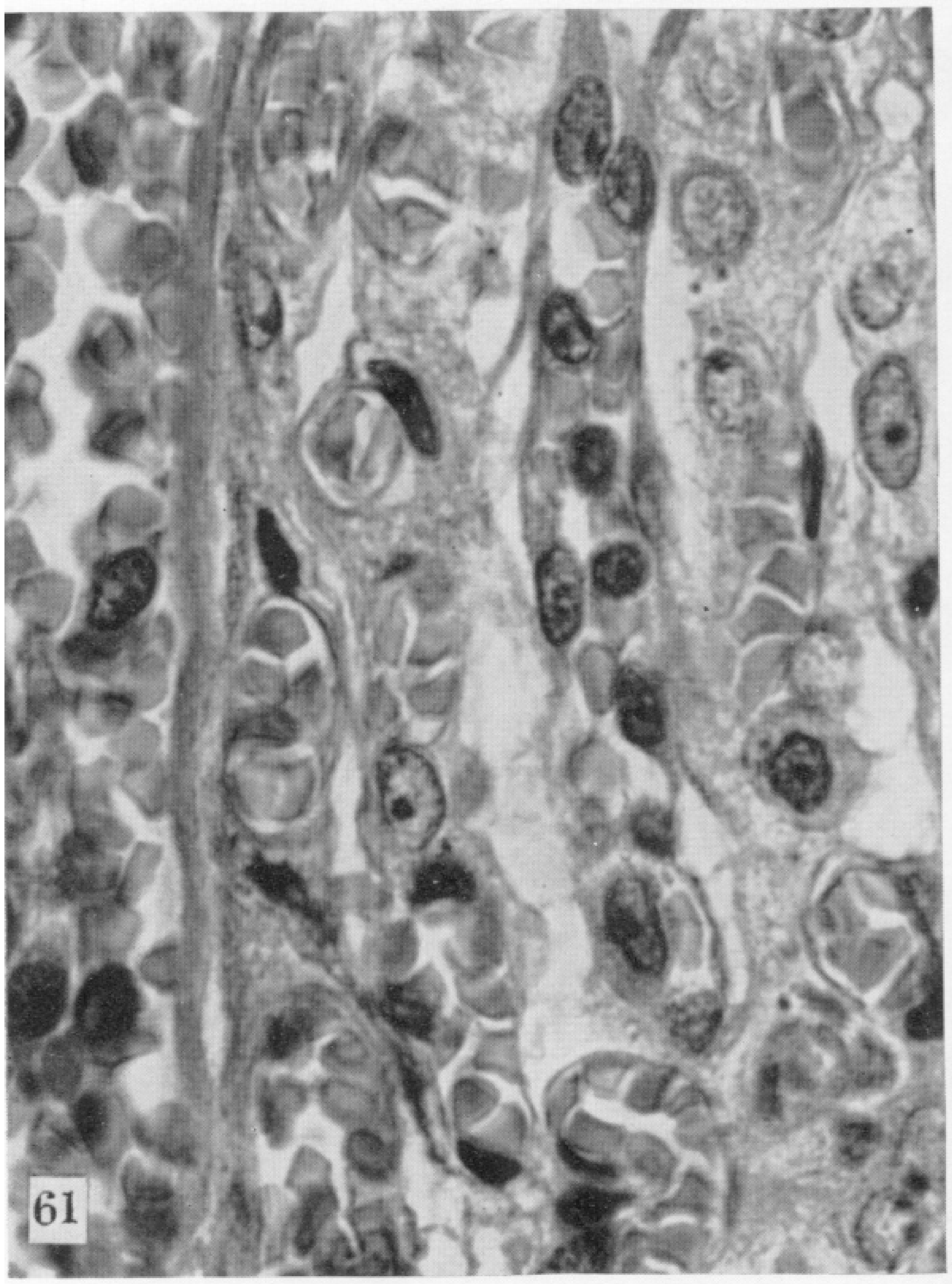

61

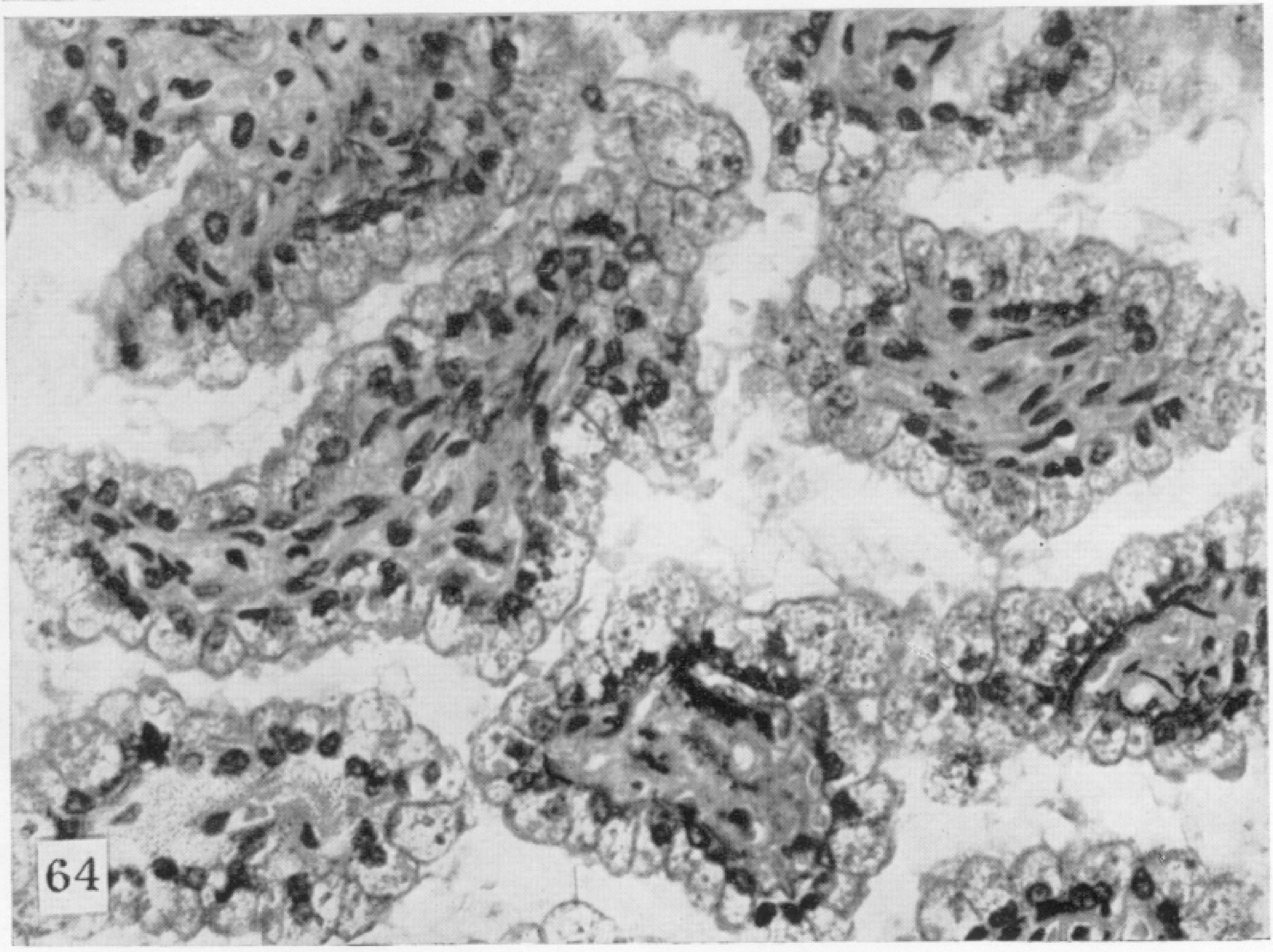

64

FIGURES 60 TO 64

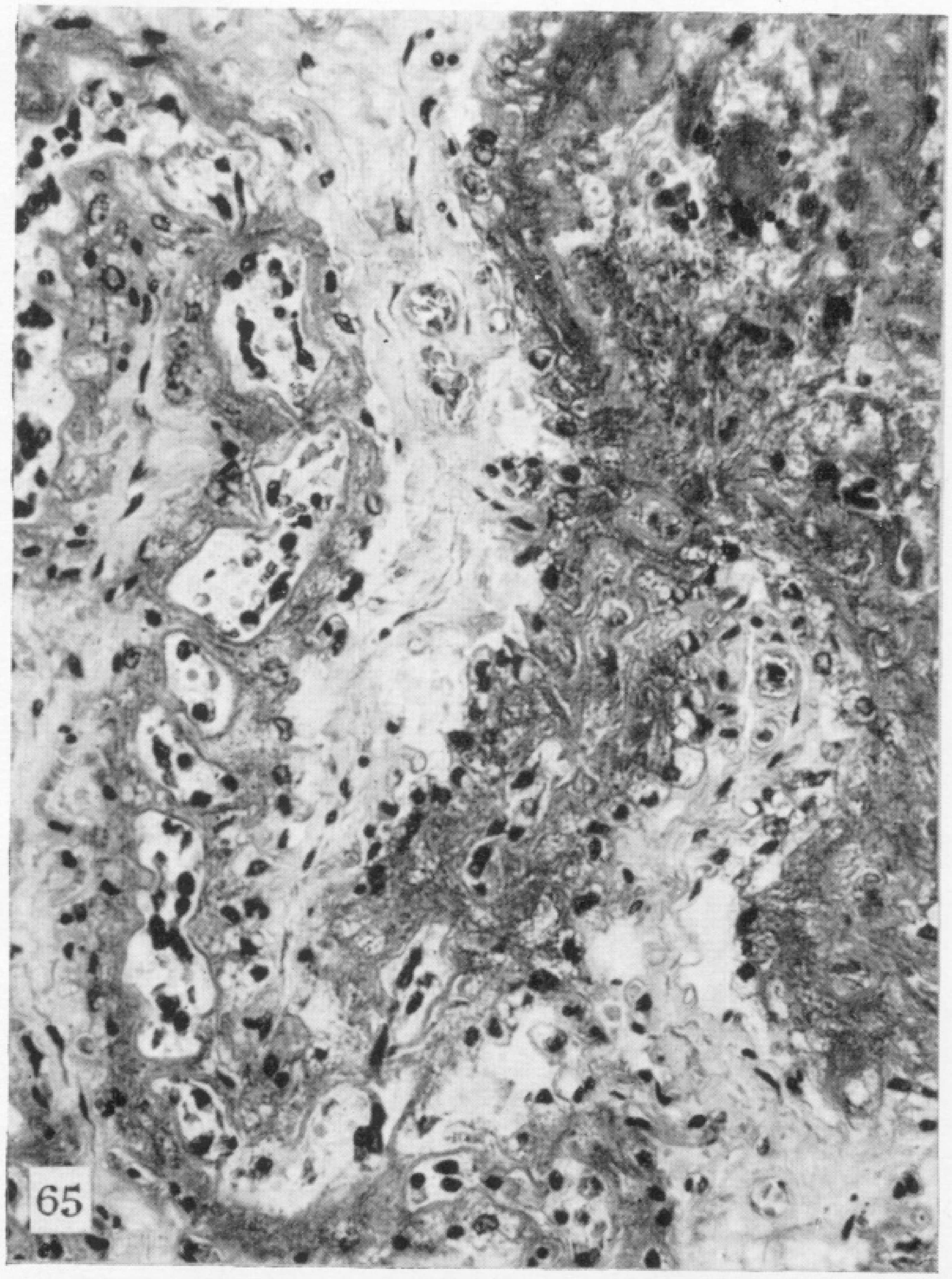
65

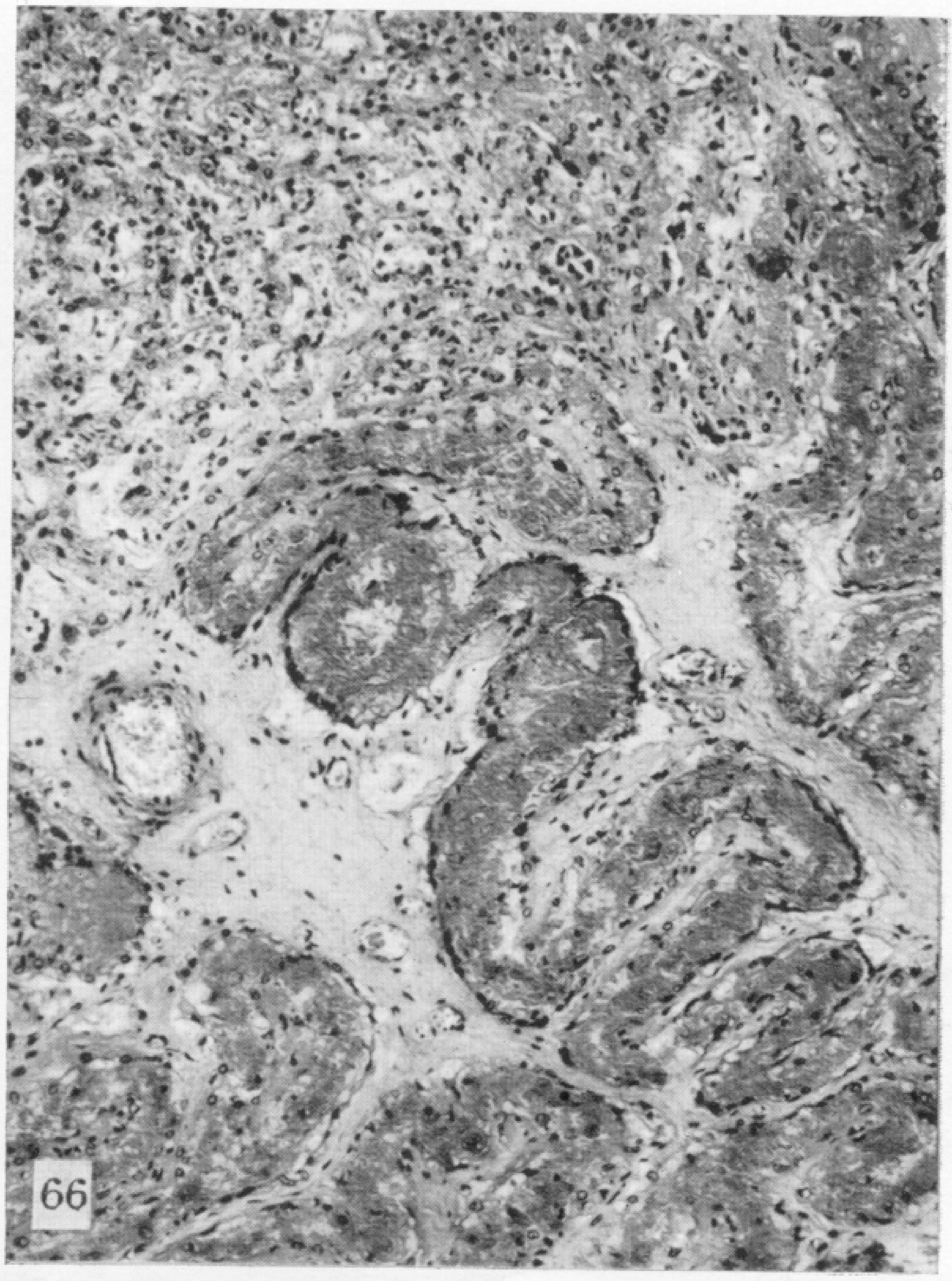
66

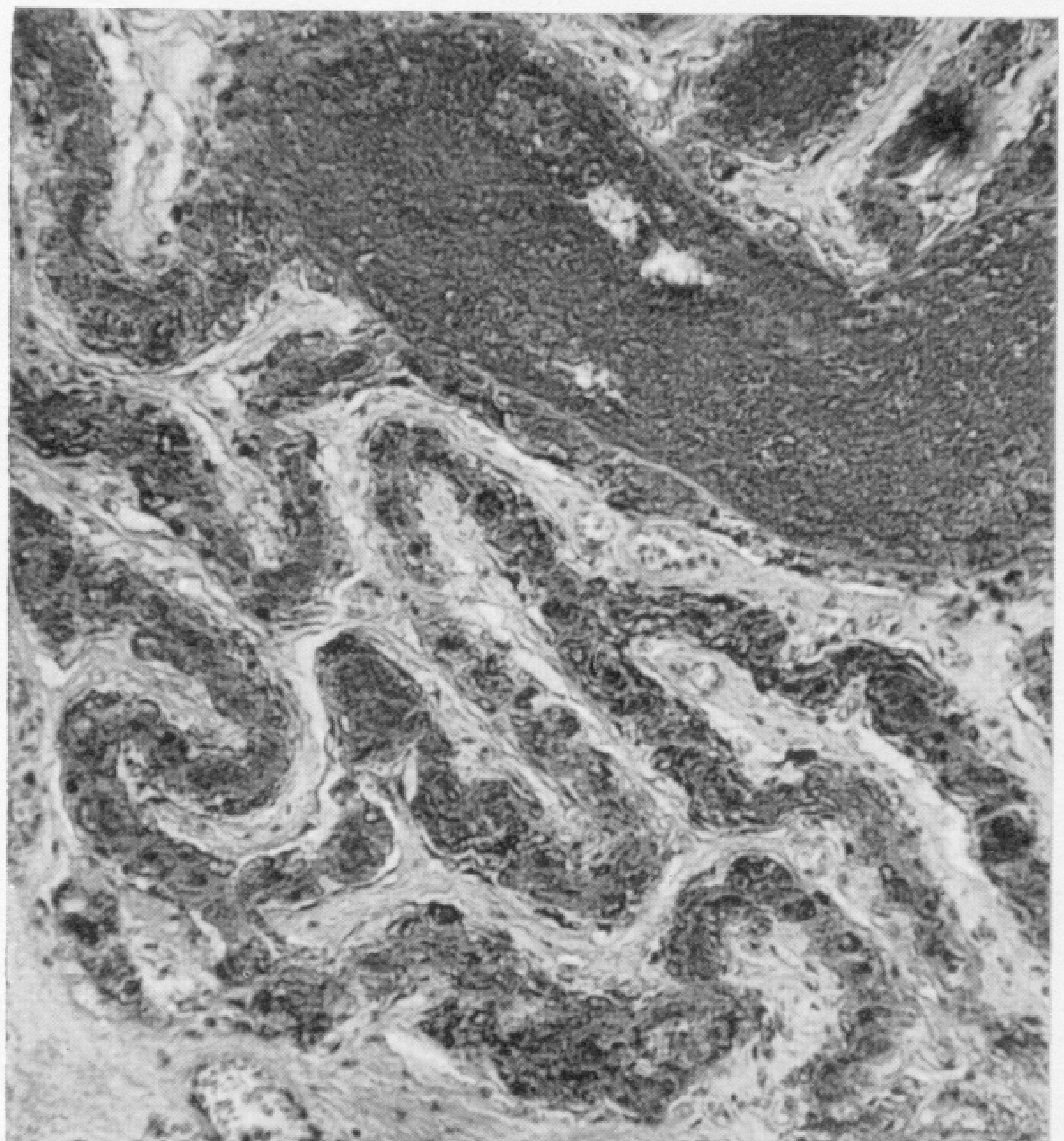
67

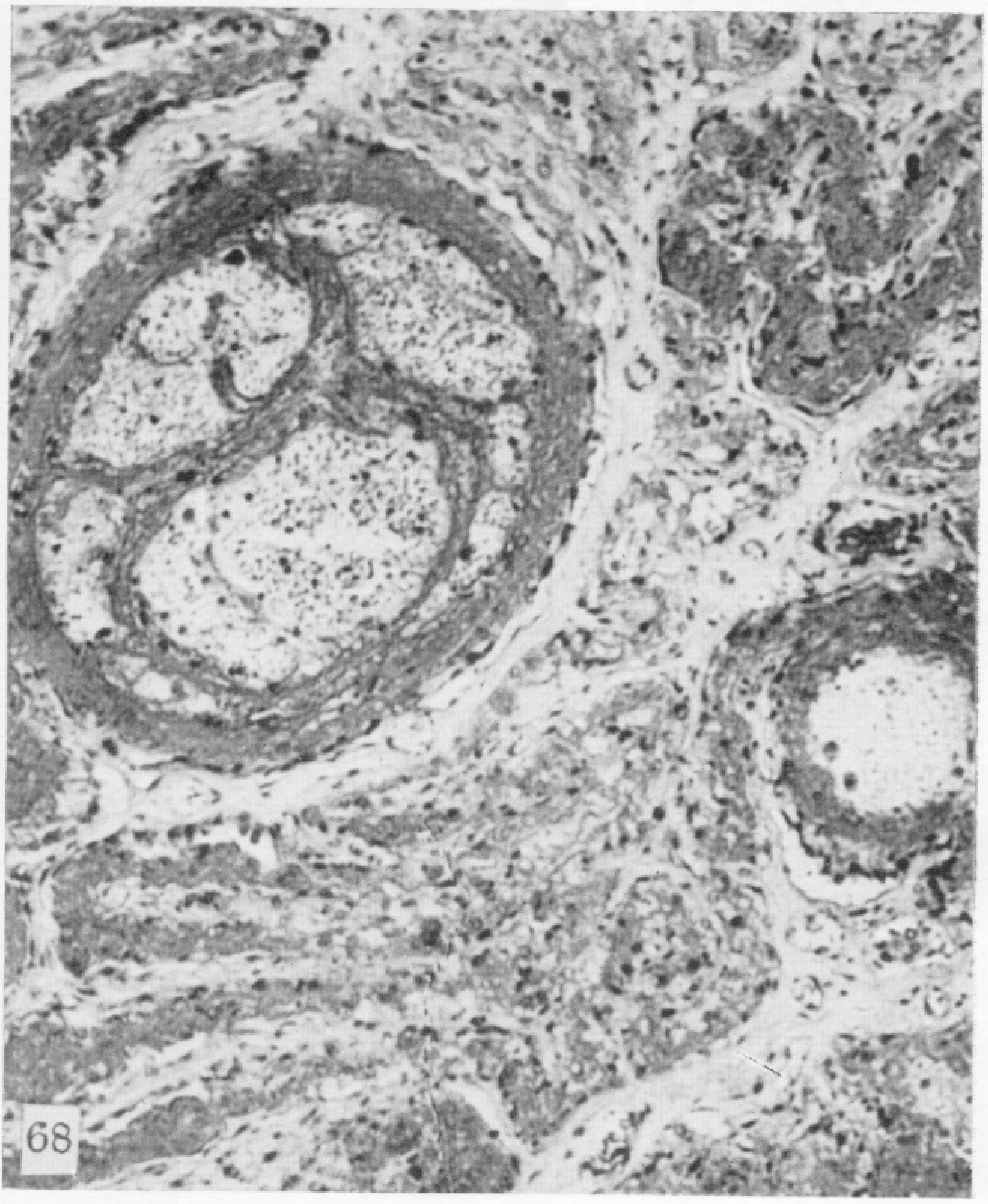
68

Figures 65 to 68